

# COVID-19 patient who denied any relating symptoms: A case report

## İlişkili semptomları reddeden COVID-19 hastası: Olgu sunumu

Hashim Talib Hashim

University of Baghdad - College of Medicine

**Corresponding author:** Hashim Talib Hashim, University of Baghdad - College of Medicine.

**E-mail:** Hashim.h.t.h@gmail.com

**Received/Accepted:** July 30, 2020 / December 20, 2020

**Conflict of interest:** There is not a conflict of interest.

### SUMMARY

COVID-19 disease triggering extreme acute respiratory illness is becoming more common globally and increasing quite quickly with surprisingly high death levels among patients in certain countries with elevated infection rates and are more common and aggressive in the countries that are not committing to the prevention rules and recommendations from the mask and hand washing.

In this paper, I reported on a case of COVID-19 patient who denied any symptoms despite that the case is very familiar and clear and the investigations confirmed the diagnosis.

This case of COVID-19 is special because the patient hides her symptoms to avoid the quarantine according to her. This patient was in sever stage because her SPO<sub>2</sub> = 77 and she had Gastrointestinal symptoms acting as a heartburn and despite that she was hiding her symptoms.

**Keywords:** COVID-19; heartburn; fever; sore throat; lymphopenia.

 Hashim Talib Hashim

ORCID IDs of the authors:  
H.T.H. 0000-0001-6155-7302

### ÖZET

Aşırı akut solunum yolu hastalığını tetikleyen COVID-19 hastalığı, küresel olarak daha yaygın hale geliyor ve enfeksiyon oranları yüksek olan bazı ülkelerdeki şaşırtıcı derecede yüksek ölüm seviyeleri ile oldukça hızlı bir şekilde artıyor ve önleme kurallarına uymayan ülkelerde daha yaygın ve agresif maske ve el yıkama önerileri.

Bu yazıda, vakanın çok tanınık ve açık olmasına rağmen herhangi bir semptomu reddeden bir COVID-19 hastasını rapor ettim ve incelemeler tanıyı doğruladı.

Bu COVID-19 vakası özeldir, çünkü hasta karantınayı ona göre önlemek için semptomlarını gizler. SPO<sub>2</sub> = 77 olması nedeniyle mide ekşimesi geçiren hasta mide ekşimesi gibi davranan gastrointestinal semptomları vardı ve buna rağmen semptomlarını saklıyordu.

**Anahtar sözcükler:** Covidien'in-19; göğüste ağrılı yanma hissi; ateş; boğaz ağrısı; lenfopeninin.

## INTRODUCTION

COVID-19 disease triggering extreme acute respiratory illness is becoming more common globally and increasing quite quickly with surprisingly high death levels among patients in certain countries with elevated infection rates and are more common and aggressive in the countries that are not committing to the prevention rules and recommendations from the mask and hand washing.<sup>1</sup>

Some people think that being infected with COVID-19 is a stigma and the society will look at him as unwanted person so they are tending to hide their infection or symptoms and sometimes they do not go to the hospital for checkup.<sup>2</sup>

The symptoms of the disease are variable from patient to another. Some patients suffer from fever, sore throat and dyspnea, while the others may suffer from gastrointestinal symptoms such as vomiting and diarrhea.<sup>3</sup>

There are reported cases of patients suffering from urinary symptoms as well.<sup>4</sup>

In this paper, I reported on a case of COVID-19 patient who denied any symptoms despite that the case is very familiar and clear and the investigations confirmed the diagnosis.

## CASE REPORT

A middle aged (49) years, female complained from heartburn for three days which exacerbate with eating and relieved by sleeping with high pill under the head.

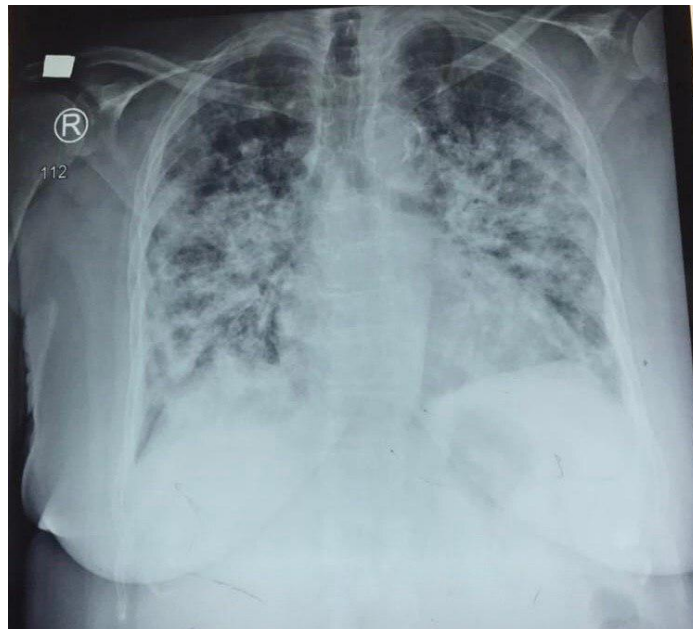
She denied any fever, shortness of breath, sore throat, headache, vomiting and diarrhea.

She is hypertensive (140/100) and diabetic (Random Glucose level = 190), she controls her blood pressure with Losartan and hydrochlorothiazide (Hyzaar). And for diabetes, she takes metformin (500 mg).

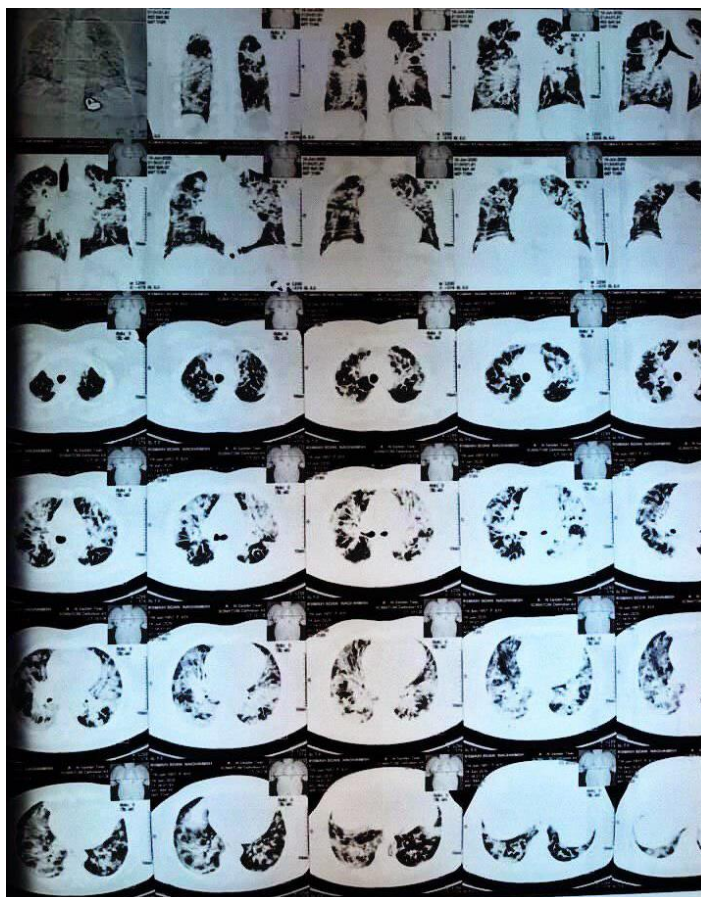Her SPO<sub>2</sub> was 77%, she was sent for chest x-ray and CT-imaging which showed a ground glass appearance covering both lungs and almost all zones that indicates sever infection (Figure 1 and Figure 2).

Her lab results showed sever elevation in lymphocytes and Lactic acid dehydrogenase (LAD):

1. Lymphocytes = 11.3%
2. Lactic acid dehydrogenase (LAD) = 600 U/L



**Figure 1:** The Chest X-ray for the patient



**Figure 2:** The Chest CT for the patient

After these findings, a swab from the nasal cavity internally was taken and sent for PCR. The results came with positive COVID-19 disease and she admitted that she had suffered from Fever and dyspnea in the last seven days with severe headache that controlled with Paracetamol pills three times a day and usually more than three times.

She was admitted to quarantine hospitals that was specialized for COVID-19 patients and put under observation with Oxygen mask till she had got better and her  $SPO_2$  becoming to raise and her symptoms resolved.

## DISCUSSION

This case of COVID-19 is special because the patient hides her symptoms to avoid the quarantine according to her. This patient was in sever stage because her  $SPO_2 = 77$  and she had Gastrointestinal symptoms acting as a heartburn and despite that she was hiding her symptoms.

There are many reasons that make the patient hide the symptoms especially in the middle east countries and the developing countries such as the stigma of society and the quarantine time especially the women who have to take care of their homes and children and then make them vulnerable for the infection.

## Conflict of interest:

- I declare that I have no conflict of interest.
- I declare that IO have no source of funding received.
- Patient consent paper was signed by the patient himself.
- Ethical approval was obtained from the ethical committee of the university of Baghdad – College of Medicine.

## REFERENCES

1. Velavan T, Meyer C. The COVID-19 epidemic. *Tropical Medicine & International Health*. 2020;25(3):278-280.

2. Low S, Smart A. Thoughts about Public Space During Covid-19 Pandemic. *City & Society*. 2020;32(1).
3. Pan L, Mu M, Yang P, Sun Y, Wang R, Yan J et al. Clinical Characteristics of COVID-19 Patients With Digestive Symptoms in Hubei, China. *The American Journal of Gastroenterology*. 2020;115(5):766-773.
4. Mumm J, Osterman A, Ruzicka M, Stihl C, Vilsmaier T, Munker D et al. Urinary Frequency as a Possibly Overlooked Symptom in COVID-19 Patients: Does SARS-CoV-2 Cause Viral Cystitis?. *European Urology*. 2020;.