



Is the Safe Cholecystectomy Technique Really Safe?

Sinan SOYLU*¹,

¹ . Cumhuriyet University, Faculty of Medicine, Department of General Surgery Sivas, Türkiye

*Corresponding author

Research Article

History

Received: 12/09/2023

Accepted: 27/12/2023

ABSTRACT

Abstract

This study aims to present the results of a single surgeon's experience to demonstrate the effectiveness of the 'Critical View of Safety' (CVS) technique in preventing bile duct injuries in clinical practice.

We retrospectively reviewed the records of 899 patients who underwent cholecystectomy using the CVS technique performed by a single surgeon at the Sivas Cumhuriyet University Hospital General Surgery Department between 2018 and 2023. Ethical approval for the study was obtained. Cholecystectomy cases were scanned retrospectively. The patients' age, gender, drain placement, surgery indications, and reason for switching to open cholecystectomy were recorded.

Among the 899 patients reviewed, 312 were male (34.70%), and 587 were female (65.30%). The average age was 55.10 for males and 51.65 for females. It was determined that 7(0.77%), cases converted to open cholecystectomy. The most common indication for cholecystectomy was elective gallbladder stone removal, accounting for 47.05% of cases. No major bile duct injuries were detected..

The safe cholecystectomy technique can be safely applied to avoid bile duct injuries in laparoscopic cholecystectomy

Keywords: Cholecystectomy, Bile duct injuries, Critical View of Safety

Güvenli Kolesistektomi Gerçekten Güvenli mi?

Süreç

Geliş: 12/09/2023

Kabul: 27/12/2023

ÖZ

Bu çalışma, klinik pratikte safra yolu yaralanmalarının önlenmesinde 'Eleştirel Güvenlik Görüşü' (CVS) tekniğinin etkinliğini göstermek için tek bir cerrahın deneyiminin sonuçlarını sunmayı amaçlamaktadır.

2018-2023 yılları arasında Sivas Cumhuriyet Üniversitesi Hastanesi Genel Cerrahi Anabilim Dalı'nda tek cerrah tarafından CVS tekniği kullanılarak kolesistektomi yapılan 899 hastanın kayıtları retrospektif olarak incelendi. Çalışma için etik onay alındı. Kolesistektomi olguları geriye dönük olarak tarandı. Hastaların yaşı, cinsiyeti, dren yerleşimi, ameliyat endikasyonları ve açık kolesistektomiye geçiş nedenleri kaydedildi.

İncelenen 899 hastanın 312'si (%34,70) erkek, 587'si (%65,30) kadındı. Erkeklerde yaş ortalaması 55,10, kadınlarda ise 51,65' idi. Olguların 7'sinin (%0,77) açık kolesistektomiye dönüştüğü belirlendi. Kolesistektominin en yaygın endikasyonu safra kesesi taşının elektif olarak çıkarılmasıydı ve vakaların %47,05'ini oluşturuyordu. Majör safra kanalı yaralanması tespit edilmedi.

Laparoskopik kolesistektomide safra yolu yaralanmalarını önlemek için güvenli kolesistektomi tekniği güvenle uygulanabilir.

Anahtar sözcükler: Kolesistektomi, Safra yolu yaralanmaları, Güvenliğe Eleştirel Bakış

License



This work is licensed under Creative Commons Attribution 4.0 International License

soylu.sinan@hotmail.com

<https://orcid.org/0000-0002-3911-3227>

How to Cite: Soylu S (2023) Is the Safe Cholecystectomy Technique Really Safe?, Cumhuriyet Medical Journal, December 2023, 45(4): 73-77

Introduction

Over the past three decades, laparoscopic cholecystectomy has become a widely practiced method for gallbladder removal. Still, it has been associated with an increase in major bile duct injuries compared to open cholecystectomy¹⁻⁴. Presently, among 1,000 patients undergoing laparoscopic cholecystectomy, two to four experience major bile duct injuries necessitating biliary reconstruction⁵. Despite the global acceptance of the 'Critical View of Safety' (CVS) for identifying critical anatomical structures such as the cystic duct, common bile duct, and cystic artery, major bile duct injuries continue to occur⁶. These injuries have serious consequences, including extended hospital stays, multiple invasive procedures, reduced quality of life, and increased mortality⁷. One of the significant factors leading to these complications during laparoscopic cholecystectomy is the adhesions that often result from prior or ongoing cholecystitis, causing challenges for surgeons and potential legal implications.

The CVS technique, conceptualized in 1995, has emerged as a critical and reproducible step to ensure safe cholecystectomy⁸. It involves three key components: (i) clearing all fibrous and fatty tissue from the hepatocystic triangle, (ii) dissecting the distal one-third of the gallbladder, and (iii) completely exposing the anatomy of the cystic duct and cystic artery. Various international guidelines have emphasized the importance of CVS as a fundamental step in safe cholecystectomy^{9,10}. The primary focus of these guidelines is on the precise identification and dissection of critical anatomical structures related to the gallbladder.

This study aims to present the results of a single surgeon's experience to demonstrate the effectiveness of the CVS technique in preventing bile duct injuries in clinical practice.

Materials and Methods

We retrospectively reviewed the records of 899 patients who underwent cholecystectomy using the CVS technique performed by a single surgeon at the Sivas Cumhuriyet University Hospital General Surgery Department between March 2017 and March 2022. Ethical approval for the study was obtained.

In this technique, uniform principles were applied to all patients. As the initial step, the procedure involved clearing the Calot's triangle of fat and fibrous tissue and separating the gallbladder from the lowest part of the gallbladder bed (Figure 1).

The second step focused on dissecting the lower end of the gallbladder, ensuring that only two structures, the cystic duct and cystic artery, remained (Figure 1). All cutting and ligating procedures were performed after achieving clear visibility of the entire anatomy at this stage. The final step involved using cautery to remove the lower part of the gallbladder from the gallbladder bed, completing the cholecystectomy.

The patient records were examined retrospectively, with evaluations based on age, gender, the use of drains, surgical indications, reasons for open conversion, and the development of complications.

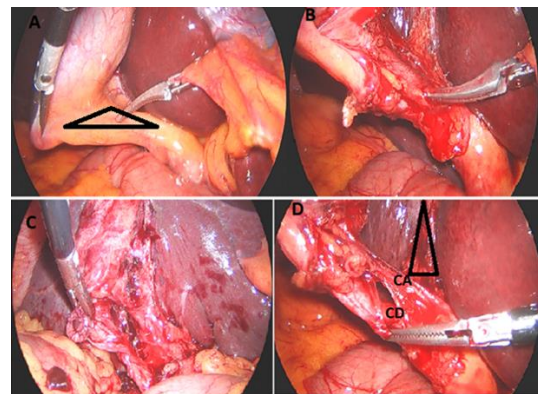


Figure 1: A: Calot's triangle. B, C: Clearing the Calot's triangle of fat and fibrous tissue and separating the gallbladder from the lowest part of the gallbladder bed. D: It ensures that only two structures (cystic duct and cystic artery) enter the gallbladder. CA: Cystic artery, CD: Cystic duct.

Results

Among the 899 patients reviewed, 312 were male (34.70%), and 587 were female (65.30%). The average age was 55.10 for males and 51.65 for females.

The most common indication for cholecystectomy was elective gallbladder stone removal, accounting for 47.05% of cases. Other indications included a history of pancreatitis or choledocholithiasis, acute cholecystitis (early cholecystectomy), gallbladder empyema, and gallbladder perforation (with percentages of 18.02%, 14.12%, 14.79%, 3.11%, and 1.44%, respectively).

Among the seven cases (0.77%) that required open conversion, two cases (28.57%) had severe inflammation, two cases (28.57%) had strong adhesions, two cases (28.57%) had anatomical irregularities, and one case (14.28%) involved bleeding.

After laparoscopic cholecystectomy, drains were placed in 402 patients (44.7%).

Table 1. Table of age and drainage catheter use according to cholecystectomy indications

Indication	Male	Female	total	Drein		
				No	Yes	Total
Planned Surgery	145	278	423	237	186	423
Dyspeptic Complaints	50	112	162	100	62	162
Pancreatitis, Choledocholithiasis	46	81	127	74	53	127
A Cholecystitis (Early Cholecystectomy)	47	86	133	65	68	133
Gallbladder Empyema	11	17	28	6	22	28
Gallbladder Perforation	7	6	13	2	11	13
Celiacystitis Planned Surgery	312	587	899	497	402	899
Total	145	278	423	237	186	423

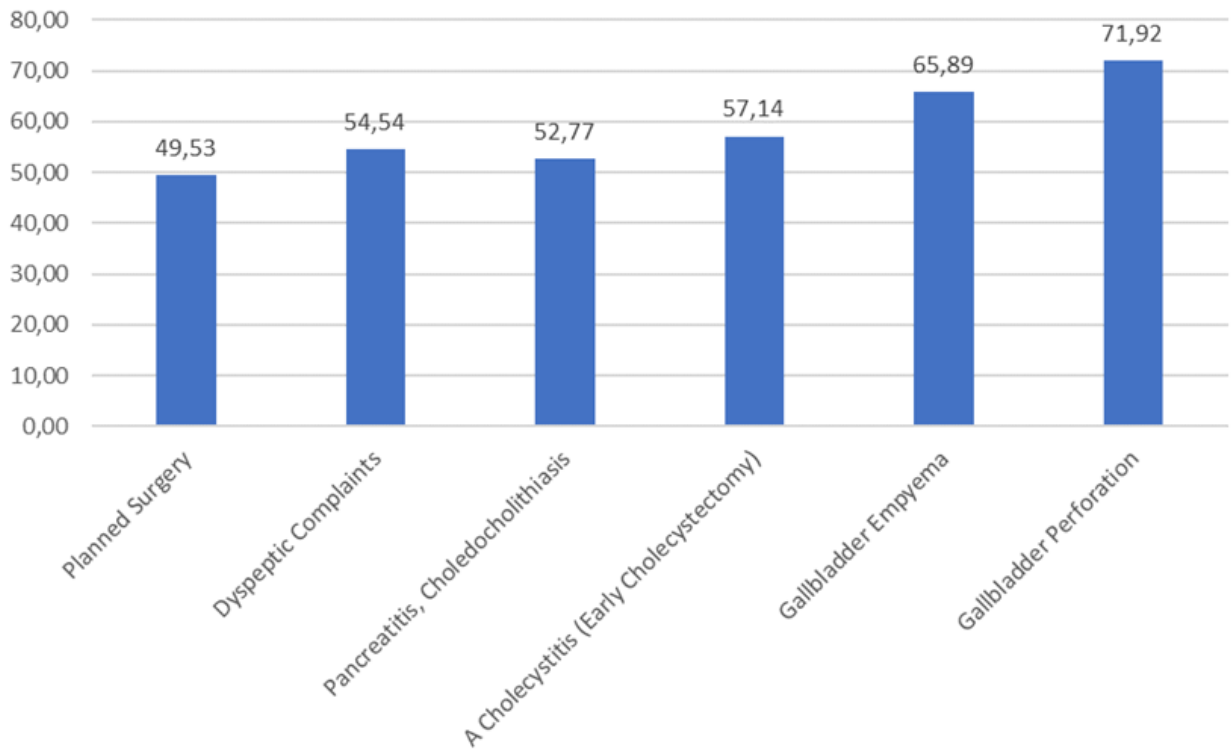


Figure 2. Figure of age according to cholecystectomy indications.

Discussion

Laparoscopic cholecystectomy is widely recognized as the gold standard for the surgical treatment of cholelithiasis. Nevertheless, the associated complications have been linked to mortality rates of up to 18%¹¹. Factors contributing to these complications include inadequate surgical experience and insufficient dissection, which may result from challenges posed by anatomical variations and adhesions associated with previous cholecystitis^{12,13}.

The adoption of laparoscopic techniques as the gold standard in cholecystectomy has not only led to an increased complication rate but has also altered the nature of bile duct injuries, with more severe complications such as complete bile duct transections, thermal injuries, and central injuries caused by incorrect dissection of the hepatic hilum¹⁵.

Various surgical techniques have been described in the literature to ensure the safe identification of ductal structures in laparoscopic cholecystectomy^{16,17}. These techniques share the common goal of establishing an objective surgical method for recognizing the anatomical structures in this region.

While intraoperative cholangiography has been presented as an effective method for preventing

bile duct injuries¹⁸⁻¹⁹, it has not provided the expected level of protection. Moreover, it is known to present technical challenges and increase both the duration and cost of the operation.

The safe critical view technique, introduced by Strasberg in 1995⁸, has been widely adopted by many surgeons. In this study, where our own cases were presented, we applied this technique to all patients, irrespective of whether their cases were elective or emergency. A single experienced surgeon performed these cases. Similar to the findings of Avginos¹⁵, no major bile duct injuries were encountered.

The absence of bile duct injuries and the consistency in the surgical approach performed by the same surgeon underscore the significance of the surgical experience. Some studies in the literature highlight the decrease in the rate of injuries after a surgeon's first 50 cases, emphasizing the importance of factors based on experience, such as familiarity with anatomical variations, safe dissection techniques, and making the correct decisions regarding open conversion, as the number of cases increases^{20,21}.

Result: The safe cholecystectomy technique can be safely applied to avoid bile duct injuries in laparoscopic cholecystectomy

References

1. Vollmer CM, Jr., Callery MP. (2007) Biliary injury following laparoscopic cholecystectomy: why still a problem? *Gastroenterology* 133: 1039–1041. <https://doi.org/10.1053/j.gastro.2007.07.041>, 2007/09/15
2. Way LW, Stewart L, Gantert W et al (2003) Causes and prevention of laparoscopic bile duct injuries: analysis of 252 cases from a human factors and cognitive psychology perspective. *Ann Surg* 237(4):460–469. <https://doi.org/10.1097/01.SLA.0000060680.92690.E9>
3. The Southern Surgeons Club (1991) A prospective analysis of 1518 laparoscopic cholecystectomies. *N Engl J Med* 324(16):1073–1078. <https://doi.org/10.1056/NEJM1991041832416015>.
4. Davidof AM, Pappas TN, Murray EA et al (1992) Mechanisms of major biliary injury during laparoscopic cholecystectomy. *Ann Surg* 215(3):196–202 6.
5. Tornqvist B, Stromberg C, Persson G, Nilsson M (2012) Effect of intended intraoperative cholangiography and early detection of bile duct injury on survival after cholecystectomy: population based cohort study. *BMJ* 345:e6457. <https://doi.org/10.1136/bmj.e6457>
6. Brittany Greene, Melanie Tsang, Shiva Jayaraman. The inferior boundary of dissection as a novel landmark for safe laparoscopic cholecystectomy. 2021; 23 (7):981-983. [Doi:10.1016/j.hpb.2021.02.04](https://doi.org/10.1016/j.hpb.2021.02.04).
7. Joshua Weis, Michael Brunt, Amin Madani, Dana Telem, Madhuri Nagaraj, Horacio Asbun, Briam R Davis, Sharmila Dissanaik, Michael B Ujiki, Carl J Wescott, Adnan Alseidi; SAGES Safe Chole Task Force. SAGES safe cholecystectomy modules improve practicing surgeons' judgment: results of a randomized, controlled trial. 2023; 37(2):862-870.
8. Strasberg SM, Hertl M, Soper NJ. An analysis of the problem of biliary injury during laparoscopic cholecystectomy. *J. Am. Coll. Surg.* 1995; 180: 101–25
9. Brunt LM, Deziel DJ, Telem DA et al. Safe cholecystectomy multisociety practice guideline and state of the art consensus conference on prevention of bile duct injury during cholecystectomy. *Ann. Surg.* 2020; 272: 3–23.
10. Bansal VK, Misra M, Agarwal AK et al. SELSI consensus statement for safe cholecystectomy—prevention and management of bile duct injury—part B. *Indian J. Surg.* 2019; 83: 611–24. <https://doi.org/10.1007/s12262-019-01994-1>
11. Moossa AR, Easter DW, Van Sonnenberg E, Casola G, D'Agostino H. Laparoscopic injuries to the bile duct. A cause for concern. *Ann Surg* 1992;215:203-8.
12. Khan MH, Howard TJ, Fogel EL, et al. Frequency of biliary complications after laparoscopic cholecystectomy detected by ERCP: experience at a large tertiary referral center. *Gastrointest Endosc* 2007;65:247-52.
13. Wojcicki M, Patkowski W, Chmurowicz T, et al. Isolated right posterior bile duct injury following cholecystectomy: report of two cases. *World J Gastroenterol* 2013;19:6118-21.
14. Malik AM, Laghari AA, Talpur AH, Khan A. Iatrogenic biliary injuries during laparoscopic cholecystectomy. A continuing threat. *Int J Surg* 2008;6:392-5.
15. Avgerinos C, Kelgiorgi D, Touloumis Z, Baltatzis L, Dervenis C. One thousand laparoscopic Cholecystectomies in a single surgical unit using the "Critical View of Safety" technique *J Gastrointest Surg* 2009; 13: 498-503.
16. Strasberg SM, Eagon CJ, Drebin JA. The «hidden cystic duct» syndrome and the infundibular technique of laparoscopic cholecystectomy—the danger of the false infundibulum. *J Am Coll Surg* 2000;191(3):661–667. [doi:10.1016/S1072-7515\(00\)00717-1](https://doi.org/10.1016/S1072-7515(00)00717-1).
17. Strasberg SM. Biliary injury in laparoscopic surgery: Part 2. Changing the culture of cholecystectomy. *J Am Coll Surg* 2005;201(4):604–611. [doi:10.1016/j.jamcollsurg.2005.04.032](https://doi.org/10.1016/j.jamcollsurg.2005.04.032).
18. Fletcher DR, Hobbs MS, Tan P, Valinsky LJ, Hockey RL, Pikora TJ, Knuiaman MW, Sheiner HJ, Edis A. Complications of cholecystectomy: risks of the laparoscopic approach and protective effects of operative cholangiography: a population based study. *Ann Surg* 1999;229:449–457. [doi:10.1097/0000658-199904000-00001](https://doi.org/10.1097/0000658-199904000-00001).
19. Flum DR, Koepsell T, Heagerty P, Sinanan M, Dellinger EP. Common bile duct injury during laparoscopic cholecystectomy and the use of intraoperative cholangiography: adverse outcome or preventable error? *Arch Surg* 2001;136:1287–1292. [doi:10.1001/archsurg.136.11.1287](https://doi.org/10.1001/archsurg.136.11.1287).
20. Adams DB, Borowicz MR, Woolton FT III, Cunningham JT. Bile duct complications after laparoscopic cholecystectomy. *Surg Endosc* 1993;7:79–83. [doi:10.1007/BF00704382](https://doi.org/10.1007/BF00704382).
21. Archer SB, Brown DW, Smith CD, Branum GD, Hunter JG. Bile duct injury during laparoscopic cholecystectomy: results of a national survey. *Am Surg* 2001;234:549–559.