



## Unusual Clinical Presentation of Sarcoidosis with Thrombocytopenia, Bone Marrow Involvement, and Myocardial Infiltration: A Case Report

Sejla Karup<sup>1,a</sup>, Burak Oğulcan Yıldırım<sup>2,b,\*</sup>, Esra Fırat Şentürk<sup>3,c</sup>, Yunus Emre Şentürk<sup>4,d</sup>, Serdal Uğurlu<sup>3,e</sup>

<sup>1</sup>Medical Student, Cerrahpaşa Medical Faculty, University of Istanbul, Istanbul, Türkiye

<sup>2</sup>Department of Cardiology, Menguçek Gazi Education and Research Hospital, Erzincan Binali Yıldırım University Medical Faculty, Erzincan, Türkiye

<sup>3</sup>Department of Internal Medicine, Division of Rheumatology, Cerrahpaşa Medical Faculty, University of Istanbul

<sup>4</sup>Department of Radiology, Koç University School of Medicine, Istanbul, Türkiye

\*Corresponding author

### Case Report

#### History

Received: 27/12/2023

Accepted: 21/05/2024

### ABSTRACT

This case study describes a 67-year-old female patient who presented with shortness of breath and quick exhaustion. In 2018, initial symptoms led to a diagnostic thoracic CT scan, which confirmed sarcoidosis using endobronchial ultrasound (EBUS). Despite the diagnosis, the patient did not receive treatment. A 2023 bone marrow biopsy revealed that the disease had progressed to include heart failure and thrombocytopenia. Transthoracic echocardiography (TTE) was used for cardiological examination, which revealed impaired left ventricular wall motion. Magnetic resonance imaging (MRI) revealed severe cardiac involvement by detecting full-thickness late gadolinium enhancement (LGE) in the left ventricle. This case report emphasizes the complexity and diversity of sarcoidosis symptoms, supporting a multidisciplinary approach for correct diagnosis and individual treatment approach.

**Keywords:** Sarcoidosis, Thrombocytopenia, Myocardial Infiltration, Bone Marrow Involvement

## Sarkoidozun Trombositopeni, Kemik İliği Tutulumu ve Miyokard İnfiltrasyonu ile Birlikte Olağandışı Klinik Görünümü: Olgu Sunumu

### Olgu Sunumu

#### Süreç

Geliş: 21/12/2023

Kabul: 21/05/2024

### ÖZET

Bu vaka çalışmasında nefes darlığı ve çabuk yorulma şikayetleriyle başvuran 67 yaşında bir kadın hasta anlatılmaktadır. İlk semptomlar 2018 yılında, endobronşiyal ultrason (EBUS) kullanılarak sarkoidozu doğrulayan tanısal bir toraks BT taramasına yol açtı. Teşhise rağmen hasta tedavi görmemiştir. 2023 yılında yapılan kemik iliği biyopsisi, hastalığın kalp yetmezliği ve trombositopeniyi içerecek şekilde ilerlediğini ortaya koymuştur. Kardiyolojik inceleme için transtoraksik ekokardiyografi (TTE) kullanıldı ve sol ventrikül duvar hareket bozukluğu tespit edildi. Manyetik rezonans görüntüleme (MRG), sol ventrikülde tam kat geç gadolinyum tutulumu (LGE) tespit ederek ciddi kardiyak etkilenmeyi ortaya koydu. Bu olgu sunumu sarkoidoz semptomlarının karmaşıklığını ve çeşitliliğini vurgulamakta, doğru tanı ve bireysel tedavi yaklaşımı için multidisipliner bir yaklaşımı desteklemektedir.

**Anahtar Kelimeler:** Sarkoidoz, Trombositopeni, Miyokardiyal İnfiltrasyon, Kemik İliği Tutulumu

### Copyright



This work is licensed under  
Creative Commons Attribution 4.0  
International License

<sup>a</sup> sejla.karup@gmail.com

<sup>c</sup> esrafiratsenturk@gmail.com

<sup>e</sup> serdalugurlu@gmail.com

<sup>id</sup> 0009-0007-2587-4707

<sup>id</sup> 0000-0003-3066-138X

<sup>id</sup> 0000-0002-9561-2282

<sup>b</sup> b.ogulcan@hotmail.com

<sup>d</sup> radiodryunus@gmail.com

<sup>id</sup> 0000-0003-3448-6187

<sup>id</sup> 0000-0002-0661-7867

**How to Cite:** Karup S, Yıldırım BO, Fırat Şentürk E, Şentürk YE, Uğurlu S. Unusual Clinical Presentation of Sarcoidosis with Thrombocytopenia, Bone Marrow Involvement, and Myocardial Infiltration: A Case Report, Cumhuriyet Medical Journal. 2024;46(2): 149-151.

## Introduction

Sarcoidosis is a systemic lung disease characterized by the formation of noncaseating granulomas, and its origin remains unknown. Despite the absence of a definitive cause, sarcoidosis is thought to arise from a genetically predisposed abnormal immune response to an unidentified antigen. While many studies suggest an equal female-to-male ratio, it is notable that more males than females receive a diagnosis between the ages of 20 and 45. However, the incidence of sarcoidosis tends to peak in females at a later age, typically between 50 and 65 years old.<sup>1</sup> The disease manifests as a multisystem inflammatory disorder, with the lungs and thoracic lymph nodes being the most commonly affected organs.<sup>2</sup> This disorder primarily impacts the lungs, but it can affect any organ.<sup>3</sup> Approximately 5% of individuals with sarcoidosis exhibit clinical indications of myocardial involvement.<sup>4</sup> Bernstein recorded the first case of cardiac involvement in sarcoidosis in 1929, concerning a 52-year-old tailor who died of heart failure.<sup>5</sup> Renal and bone marrow involvements are infrequent occurrences in individuals with sarcoidosis.<sup>6</sup>

The diagnosis is based on three criteria: a consistent clinical and radiological presentation, pathological confirmation of noncaseating granulomas, and the elimination of other disorders with comparable features, such as infections or malignancies.<sup>7</sup> Corticosteroids, such as prednisone, are commonly used in clinical practice to minimize inflammation.<sup>8</sup> When corticosteroids prove inadequate or are poorly tolerated, alternative immunosuppressive medications, including methotrexate, may be explored.<sup>8</sup> In cases resistant to conventional therapies or marked by intolerance, biological agents such as tumour necrosis factor (TNF) inhibitors, emerge as potential therapeutic options. TNF inhibitors have undergone evaluation; nonetheless, findings from controlled trials have shown marginal benefits, with studies reporting no discernible advantage.<sup>9</sup>

## Case Report

A 67-year-old female patient with shortness of breath, rapid fatigue, and a history of gonarthrosis presented with atypical clinical characteristics of sarcoidosis. Shortness of breath and erythema nodosum were the first symptoms in 2018, prompting a thoracic CT scan, which revealed mediastinal lymphadenopathy and interstitial lung disease. Pathological findings validated the diagnosis of sarcoidosis based on endobronchial ultrasound (EBUS). Regardless of the diagnosis, the patient went untreated.

Since 2022, the patient experienced heart failure without a documented history of myocardial infarction. Concurrently, thrombocytopenia was first detected in December 2021 (platelet count: 40,000). Upon admission, the platelet count had dropped to 18,000, leading to hospitalization. An external centre conducted a bone marrow biopsy in 2023. The pathology results revealed normo/hypercellular bone marrow (25%-55% cellularity), erythroid hyperplasia with normoblastic maturation,

myeloid hyperplasia with uninterrupted maturation, increased megakaryopoiesis, and two small non-necrotizing granulomas within the intramedullary and paracortical connective tissue, confirming sarcoidosis.

Despite the patient's thrombocytopenia, the cardiology department decided against angiography and instead performed a transthoracic echocardiography (TTE) to determine the cause of the patient's recurrent shortness of breath. The TTE results identified impaired left ventricular wall motion, with an ejection fraction (EF) of 40-45% and segmental wall motion abnormalities. Magnetic resonance imaging (MRI) revealed full-thickness late gadolinium enhancement (LGE) in the basal inferior-inferolateral wall of the left ventricle, along with a suspicious mid-wall LGE area in the basal inferoseptum. (Figure 1.) Although artefact-related considerations were acknowledged, these findings suggested significant cardiac involvement of sarcoidosis. The steroid treatment was initiated at a milligram per kilogram basis. Steroid therapy improved the platelet (PLT) count to over 100,000. The patient is currently being monitored under steroid therapy.

## Discussion

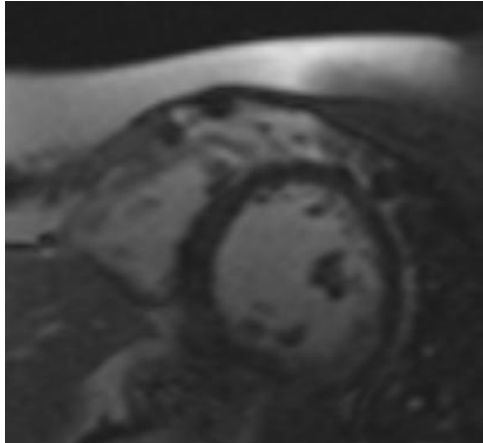
Our case report emphasizes the complexities of sarcoidosis, as well as the difficulties involved with its identification and management. The unknown origin of sarcoidosis complicates its clinical course, emphasizing the importance of investigation of the various symptoms and the treatment approaches. In this case, the patient's presentation included shortness of breath and rapid exhaustion, which led to a diagnosis of sarcoidosis. Despite a clear diagnosis confirmed by EBUS and pathological findings, the patient went untreated, allowing the progression of the condition. The later development of heart failure and thrombocytopenia brought challenges, requiring a comprehensive approach to patient treatment. The decision not to perform angiography in favour of TTE and cardiac MRI emphasizes the significance of individual approach to different patient presentations. The Silesian voivodeship sarcoidosis epidemiology study found a growing incidence of the condition among younger men (25-50 years) and some older women (50-64 years). The study's observed tendency of increased occurrence in the age group of 50-64 years corresponds with the age range of our patient, implying that individuals who are older than the upper limit of the previously identified range may still be susceptible to sarcoidosis.<sup>10</sup> Based on the 1999 WASOG criteria and the 2014 WASOG organ assessment instrument, a study of 175 sarcoidosis patients at the Hospital Clinic of Barcelona, Spain, from 1990 to 2014, revealed useful insights into the disease's age-related clinical symptoms. Patients identified before the age of 40 had a higher prevalence of musculoskeletal symptoms and neurological involvement, but a lower prevalence of renal and splenic involvement. Those who developed the disease beyond the age of 65, on the other hand, had a decreased prevalence of cutaneous/musculoskeletal symptoms and little or no neurological involvement.<sup>11</sup> This study emphasises the

dynamic nature of sarcoidosis and accentuates the value of early detection and close monitoring, particularly in cases where there is a severe organ involvement. Corticosteroids have already been assessed and documented in the literature for the treatment of cardiac sarcoidosis. The purpose of the trial was to determine whether weekly methotrexate plus low-dose corticosteroids might effectively treat cardiac sarcoidosis. In a small cohort of seventeen individuals, they compared this combination to corticosteroids alone during three to five years. The combined medication was a potentially well-tolerated long-

term treatment for cardiac sarcoidosis, as it dramatically stabilised ejection fraction, cardiothoracic ratio, and NT-proBNP levels without eliciting major adverse effects.<sup>12</sup>

### Conclusion

Due to systemic involvement of sarcoidosis in patients, there is the potential for affecting every organ. We demonstrated the bone marrow involvement in a patient with thrombocytopenia, and we have found cardiac involvement in the same patient. Therefore, it is necessary to screen patients with sarcoidosis systematically.



**Figure 1.** Full-Thickness Late Gadolinium Enhancement in Basal Inferior-Inferolateral Wall and Suspicious Mid-Wall LGE in Basal Inferoseptum of Left Ventricle

### References

1. Arkema EV, Grunewald J, Kullberg S, Eklund A, Askling J. Sarcoidosis incidence and prevalence: A nationwide register-based assessment in Sweden. *European Respiratory Journal*. 2016; 48(6):1690–1699. Available from: <https://doi.org/10.1183/13993003.00477-2016>
2. Rossides M, Darlington P, Kullberg S, Arkema EV. Sarcoidosis: Epidemiology and clinical insights. *Journal of Internal Medicine*. 2023; 293(6):668–680. Available from: <https://doi.org/10.1111/joim.13629>.
3. Damsky W, Wang A, Kim DJ, Young BD, Singh K, Murphy MJ, Daccache J, Clark A, Ayasun R, Ryu C, McGearry MK, Odell ID, Fazzone-Chettiar R, Pucar D, Homer R, Gulati M, Miller EJ, Bosenberg M, Flavell RA, King B. Inhibition of type 1 immunity with tofacitinib is associated with marked improvement in longstanding sarcoidosis. *Nature Communications*. 2022; 13(1):1–17. Available from: <https://doi.org/10.1038/s41467-022-30615-x>
4. American Thoracic Society. (1999). Statement on Sarcoidosis; ATS/ERS/WASGOG. *Am J Resp Crit Care Med*. 1999; 160(3):736–755. Available from: [www.atsjournals.org](http://www.atsjournals.org)
5. Bernstein M, Konzleemann FW, Sidlick DM. Boeck's sarcoid: report of a case with visceral involvement. *Archives of Internal Medicine*. 1929; 44(5):721-734.
6. Sugai M, Murata O, Oikawa H, Katagiri H, Matsumoto A, Nagashima H, Sugai T, Maemondo M. A case of bone marrow involvement in sarcoidosis with crescentic glomerular lesions. *Respiratory Medicine Case Reports*. 2020;28 (31):101202. Available from: <https://doi.org/10.1016/j.rmcr.2020.101202>
7. Soto-Gomez N, Peters JI, Nambiar AM. Diagnosis and management of sarcoidosis. *American Family Physician*. 2016; 93(10):840–848.
8. Rahaghi FF, Baughman RP, Saketkoo LA, Sweiss NJ, Barney JB, Birring SS, Costabel U, Crouser ED, Drent M, Gerke AK, Grutters JC, Hamzeh NY, Huizar I, James WE, Kalra S, Kullberg S, Li H, Lower EE, Maier LA, Scholand MB. Delphi consensus recommendations for a treatment algorithm in pulmonary sarcoidosis. *European Respiratory Review*. 2020; 29(155). Available from: <https://doi.org/10.1183/16000617.0146-2019>
9. Baughman RP, Drent M, Kavuru M, Judson MA, Costabel U, Du Bois R, Albera C, Brutsche M, Davis G, Donohue JF, Müller-Quernheim J, Schlenker-Herceg R, Flavin S, Lo KH, Oemar B, Barnathan ES. Infliximab therapy in patients with chronic sarcoidosis and pulmonary involvement. *American Journal of Respiratory and Critical Care Medicine*. 2006; 174(7):795–802. Available from: <https://doi.org/10.1164/rccm.200603-402OC>
10. Kowalska M, Niewiadomska E, Zejda JE. Epidemiology of sarcoidosis recorded in 2006-2010 in the silesian voivodeship on the basis of routine medical reporting. *Annals of Agricultural and Environmental Medicine*. 2014; 21(1):55–58.
11. Brito-Zerón P, Sellarés J, Bosch X, Hernández F, Kostov B, Sisó-Almirall A, Casany CL, Santos JM, Paradelo M, Sanchez M, Ramírez J, Xaubet A, Agustí C, Ramos-Casals M. (2016). Epidemiologic patterns of disease expression in sarcoidosis: Age, gender and ethnicity-related differences. *Clinical and Experimental Rheumatology*. 2016; 34(3):380–388.
12. Nagai S, Yokomatsu T, Tanizawa K, Ikezoe K., Handa T, Ito Y, Ogino S, Izumi T. Treatment with methotrexate and low-dose corticosteroids in sarcoidosis patients with cardiac lesions. *Internal Medicine*. 2014; 53(5):427–433. Available from: <https://doi.org/10.2169/internalmedicine.53.0794>