

# The effects of ozone on the local and systemic interleukin 1 $\beta$ (IL-1 $\beta$ ) and IL-10 levels experimental periodontitis model in rats

## Ratlarda deneysel periodontitis modellerinde sistemik ve lokal interlökin 1BETA(IL-1 $\beta$ ) ve IL-10 seviyelerine ozonun etkisi

Aysun Akpınar<sup>1</sup>, Metin Çalışır<sup>2</sup>, Ömer Poyraz<sup>3</sup>, Fahrettin Göze<sup>4</sup>, Derya Özdemir Doğan<sup>5</sup>, Vildan Bostancı<sup>1</sup>

<sup>1</sup>Cumhuriyet University Faculty of Dentistry Periodontology Department, Sivas, Turkey

<sup>2</sup>Adiyaman University of Dentistry Periodontology Department, Adiyaman, Turkey

<sup>3</sup>Department of Microbiology, Cumhuriyet University Faculty of Medicine, Sivas, Turkey

<sup>4</sup>Department of Pathology, Cumhuriyet University Faculty of Medicine, Sivas, Turkey

<sup>5</sup>Cumhuriyet University Faculty of Dentistry Prosthesis Department, Sivas, Turkey

**Corresponding author:** Aysun Akpınar, DDS, PhD, Department of Periodontology, Cumhuriyet University Faculty of Dentistry Sivas 58140, Turkey

**E-mail:** aysunakpinar73@hotmail.com

**Received/Accepted:** August 03, 2017 / August 22, 2017

**Conflict of interest:** There is not a conflict of interest.

### SUMMARY

**Objective:** The purpose of this study was to analyze the morphometric and histopathologic changes associated with experimental periodontitis in rats in response to the administration of ozone.

**Method:** Twenty-four rats were randomly divided into three experimental groups: a nonligated (NL) treatment group (n = 8), a ligature-only (LO) treatment group (n = 8), and a ligature plus ozone (60 second/each tooth a day) (LOZ) treatment group. In order to induce experimental periodontitis, a 4/0 silk suture was placed at the gingival margin of the right-mandibular first molars of the rats. The study duration was 14 days, and then the animals were sacrificed. Changes in the alveolar bone levels of rats in each group were measured clinically, and the tissues of the rats in each group were examined histopathologically to determine inflammatory cell infiltration (ICI), osteoblast and osteoclast activities, and osteoclast morphology. Serum and gingival cytokine levels were measured by using the rat-specific IL-1 $\beta$  and IL-10 ELISA kits.

**Results:** Alveolar bone loss around the mandibular molar tooth was significantly higher in the LO group compared with NL and LOZ groups (p<0.05). The ratio of the presence of ICI and osteoclast numbers were significantly higher in the LO group than in the NL and LOZ groups (p<0.05). Osteoblastic activity was significantly lower in the LO group than in the NL and LOZ groups (p<0.05). The serum and gingival homogenate IL-1 $\beta$  levels in the LO group were statistically higher than in the NL and LOZ groups (p<0.05). The serum IL-10 level in the LO group was statistically lower than in the NL and LOZ groups (p<0.05). The gingival homogenate IL-10 level in NL group was statistically higher than in the LO group (p<0.05).

**Conclusions:** The present study showed that the oral administration of ozone diminishes alveolar bone resorption in a rat periodontitis model.

**Keywords:** Experimental periodontitis, rat, ozone, IL-1 $\beta$ , IL-10

## ÖZET

**Amaç:** Bu çalışmanın amacı deneysel periodontitisli ratlarda ozonun uygulanmasıyla histopatolojik ve morfometrik değişiklikleri analiz etmektir.

**Yöntem:** 24 rat rastgele olarak üç gruba ayrıldı. Bu gruplar: ligatürsüz tedavi grubu (NL) (n=8), sadece ligatür uygulanan tedavi grubu (LO) (n=8) ve ligatür+ozon uygulanan tedavi grubu olarak belirlendi (LOZ) (n=8). Deneysel periodontitis oluşturmak için ratların sağ mandibular 1. molarlarının gingival marjinlerine 4/0 ipek sutur yerleştirildi. 14 gün sonra ratlar sakrifiye edildi. Her gruptaki ratların alveolar kemik seviyelerindeki değişiklikler klinik olarak ölçüldü, ve her gruptaki ratların osteoklast morfolojileri, osteoklast ve osteoblast aktiviteleri, enflamatuar hücre infiltrasyonlarını (ICI) belirlemek için dokuları histopatolojik olarak incelendi. Serum ve sitokin seviyeleri ratlara özel IL-1 $\beta$  ve IL-10 Eliza kitleri kullanılarak ölçüldü.

**Bulgular:** Mandibular diş çevresindeki alveolar kemik kaybı NL ve LOZ grupları ile karşılaştırıldığında LO grubunda önemli oranda yüksek bulundu. (p<0.05) Osteoklast sayıları ve ICI nin mevcudiyetindeki oran NL ve LOZ gruplarındakinden, LO grubunda önemli oranda yüksek olduğu tespit edildi. (p<0.05) Osteoblastik aktivite NL ve LOZ gruplarından, LO grubunda önemli oranda düşük bulundu. (p<0.05) LO grubundaki serum ve gingival homojenatdaki IL-1 $\beta$  seviyesi NL ve LOZ grubundakinden önemli oranda yüksek bulundu. (p<0.05) LO grubundaki serum IL-10 seviyesi, NL ve LOZ gruplarındakinden istatistiksel olarak düşüktü. (p<0.05) NL grubundaki gingival homojenat IL-10 seviyesi LO grubundakinden istatistiksel olarak yüksek olduğu belirlendi. (p<0.05)

**Sonuç:** Mevcut çalışma, ozonun oral uygulamasının rat periodontitis modellerinde alveolar kemik rezorpsiyonunu azalttığını göstermiştir.

**Anahtar sözcükler:** Deneysel periodontitis, rat, ozon, IL-1 $\beta$  ve IL-10

## INTRODUCTION

Periodontitis, which affects much of the world's adult population, is a destructive, inflammatory, and pathological condition that affects the connective tissue attachment between the alveolar bones of the teeth. It is characterized by an excessive host response to gram-negative bacteria associated with alveolar bone and eventually leads to tooth loss<sup>1,2</sup>. Periodontitis is currently understood to be a consequence of an immune inflammatory response to an oral microbial challenge. Lipopolysaccharides and other bacterial products elicit the host's response, i.e., a response that involves several mechanisms of the immune-inflammatory system<sup>3,4</sup>. The finding emerged from these studies is that a number of proinflammatory cytokines are synthesized as a reaction to periodontopathogenic bacteria and their products, as a result it triggers and maintains an inflammatory response in the periodontium<sup>4,5</sup>.

Interleukin 1 (IL-1) is a pro-inflammatory cytokine enabling the recruitment of the cells towards infection sites, contributing to bone resorption, and stimulating the prostoglandin (PGE2) released by monocytes and fibroblasts, and the release of metalloproteinases that degrade extracellular matrix proteins<sup>6</sup>. The predominant form of IL-1 in the periodontal tissues is IL-1 $\beta$ , produced primarily by macrophages<sup>7,8</sup>. Increased levels of interleukin - 1 have been reported in the inflammatory gingival tissue of the patients with periodontitis<sup>9,10</sup>.

Anti-inflammatory mediators, interleukin-10 (IL-10) has been considered and is important contributor to the pathogenesis of periodontal diseases. IL-10 is a fundamental cytokine involved

in the infection's regulatory processes (for some T-cell subgroups), as well as it precludes for autoimmunity because of the tolerance to self-antigens<sup>11</sup>. Moreover, IL-10 adjusts the expression of cytokines having myeloid origin, due to its significant operative effects on the mobilization and continuation of the immune reaction. The observed effect of IL-10 on various cell types proposed anti-inflammatory or immunosuppressive activities in vivo, which have been tested in various experimental models<sup>12,13</sup> and might result in strong regulatory effects on immune responses in the periodontal disease.

Ozone is a potent oxidant marked with antimicrobial activity and the potential to act as a metabolic and host immune modulator<sup>14</sup>. Ozone works destructively against the bacteria, fungi and viruses. The antimicrobial effect of ozone is a result of its action on cells by damaging the cytoplasmic membrane due to ozonolysis of dual bonds and also ozone-induced modification of intracellular contents because of the secondary oxidant effects. This action is selective to microbial cells but does not damage human body cells because of their major antioxidative ability<sup>15</sup>. Ozone influences cellular and humoral immune system. It stimulates proliferation of immunocompetent cells and synthesis of immunoglobulins. It also activates function of macrophages and increases the sensitivity of the microorganisms to phagocytosis. Ozone causes the synthesis of biologically active substances such as interleukins, leukotrienes, and prostaglandins which are beneficial in reducing inflammation and wound healing. Ozone in high concentrations causes immunodepressive effect whereas in the

low concentrations causes immunostimulating effect<sup>16</sup>.

A systemic review indicated good evidence for biocompatibility of ozone with oral epithelial cells, periodontal cells and gingival fibroblast<sup>17</sup>. Furthermore, the biocompatibility of ozone and its effect on oral epithelial wound healing have been studied on oral cells in comparison with other antiseptic agents ozone was found to be highly compatible and effective when used at certain concentrations<sup>17,18</sup>.

Ozone therapy can lead to several biological reactions such as improvements in blood circulation and oxygen delivery in the ischemic tissues, enhancements in general metabolism due to improvement in oxygen delivery, upregulations in cellular antioxidant enzymes, and a mild activation of the immune system enhancing the release of the growth factors<sup>19</sup>.

Recently, ozone therapy, has gained momentum in dentistry. Most of the published articles considering the use of ozone in dentistry have been relation to its antimicrobial effects<sup>18,20-22</sup>. In light of these data and considering ozone's antiinflammatory properties and capability for significantly inhibiting the expression of proinflammatory cytokines, it may play a significant role in preventing the initiation and progression of periodontitis. It is probable that ozone will present a new aspect in the prevention and treatment of periodontal disease.

Therefore, ozone may have a role in the inhibition of periodontal inflammation and alveolar bone loss in periodontal disease. The aim of the present study was to evaluate the effect of ozone on cytokines and alveolar bone loss in experimental periodontitis in a rat model.

## MATERIALS AND METHODS

### Animals

Twenty-four adult male and systemically healthy (aged 12 weeks) Wistar rats with an initial mean weight of 300 g to 320 were used. The rats were randomly divided into three groups of eight rats each: Group 1: non-ligated control group (NL). Group 2: Ligature-only group (LO). Group 3: Ligature+ Ozone (LOZ). The animals were acclimatized to the housing conditions for 2 weeks. Rats were housed in each cage and maintained under a 12-hour light/dark cycle at a temperature of

22° C. The animals were kept in individual cages and received water and food ad libitum. The experimental protocol of the present study was approved by the Ethics Committee on Animal Experimentation of Cumhuriyet University.

### Experimental Induction of Periodontitis

Experimental periodontitis was performed in rats under general anesthesia by the intramuscular injection of a combination of 0.1 mL ketamine<sup>‡</sup> hydrochloride (40 mg/kg); and 0.05 mL xylazine hydrochloride (Rompun; 2 g/100 mL) for each 100 g of body weight by the placement of sterile A 4-0 silk suture<sup>†</sup> in a subgingival position around the first molars of right mandibular quadrants. The sutures were checked after application, and lost or loose sutures were replaced. All ligatures were placed by the same operator (M.Ç.).

Ozone was administered by gingival probe\* at a rate of 60 sec/each tooth per day. On day 14, the animals were sacrificed, and the blood samples (4cc) were taken by cardiac puncture for serum ELISA analyses. After the mandible was dissected, the vestibular gingival tissues of 2x2 mm were taken from each animal as a single tissue sample, placed in 0.1M sucrose solution, and stored at -80°C prior to use for the gingival cytokine analyses. The animal heads were removed, boiled for 10 minutes, and the soft tissues were cleansed manually. Then, the skulls were soaked in 0.2 N NaOH solution at room temperature for five minutes to remove the remaining soft-tissue debris. The mandibles were dislodged, washed, dried, and stained with 1% methylene blue for the adequate identification of the cemento-enamel junction (CEJ).

### IL-1 $\beta$ and IL-10 Analyses

Serum and gingival cytokines were measured using the rat-specific IL-1 $\beta$  and IL-10 ELISA kits.<sup>†,‡</sup> Serum cytokines were analyzed in the blood sample was taken by cardiac puncture of each animal collected prior to periodontitis induction. To measure the serum IL-1 $\beta$  and IL-10 levels by ELISA, the serum was collected after centrifugation. All experimental samples were stored at -80°C until being assayed. To measure the gingival IL-1 $\beta$  and IL-10 levels by ELISA, supernatants were derived from the collected gingival tissues as described by Sakallioğlu et al.<sup>23</sup> The tissues were initially blotted and weighed in a microbalance for standardization. Then, each tissue

\*Eczacıbasi İlaç Sanayi, İstanbul, Turkey.

† Dogsan İlaç Sanayi, İstanbul, Turkey.

‡ Biozonix Ozonytron XP, Medentazone, Turkey

† Rat IL-1 $\beta$  ELISA kit, eBioscience Platinum, Vienna, Austria)

‡ Rat IL-10 ELISA kit, Invitrogen, California, USA)

was placed into a protease inhibitor (5 µg/ml aprotinin + 1 mM EDTA) containing phosphate buffer solution (pH = 7.0, at 4°C) to prepare 10 mg tissue/ml of gingiva + protease inhibitor + phosphate buffer solution. The prepared samples were homogenized (four times at 8,500 rpm for 30 seconds with 10-second intervals), and the homogenates were processed twice by a freeze-thawing procedure. Finally, sonication (three times at 4 µm to 5 µm for 30 seconds with 10-second intervals) and centrifugation (at 15,000 rpm for 16 minutes) were performed to obtain gingival supernatants. These procedures were carried out on an ice-medium at 0 °C to 4°C.

### Measurement of Alveolar Bone Loss

The mandibles were stained with aqueous methylene blue<sup>§</sup> (1%) to identify the CEJ. The alveolar bone height was measured under a stereomicroscope\*\* (x25 magnification) by recording the distance from the CEJ to the alveolar bone crest. Measurements were taken at three points on both the buccal and lingual sides to quantify the alveolar bone level. A mean value for each tooth was calculated. The morphometric measurement of alveolar bone loss was performed by a single examiner (M.C.) who was unaware of the identity of samples.

### Histopathological Evaluation

Histological evaluations were performed on the right maxillary molars. The maxillary specimens were fixed in 10% formalin for 24 h at room temperature (FG) and decalcified with a 0.1M EDTA solution at 42°C for approximately 10 days. Samples were then dehydrated and embedded in paraffin, sectioned along the molars in a mesio-distal plane, and stained with haematoxylin–eosin (H&E) and Masson's trichrome. Sections of 6µm thickness, corresponding to the area between the first and second molars where ligatures had been placed, were evaluated by light microscopy.<sup>††</sup>

Parameters such as inflammatory cell infiltration (ICI) of the periodontal tissues, fibrotic component content and bundles of collagen fibres, existing resorption lacunae (osteoclast surfaces) and osteoblastic activity (forming surfaces), and the number of osteoclasts in the alveolar bone and interdental septum were analysed. ICI was determined by a semi-quantitative scoring as no visible ICI (0), slightly visible ICI (1), moderate ICI (2), and dense ICI (3). Osteoclasts were counted based on their morphology. For the evaluation of osteoblastic activity, we defined the forming surfaces by the visibility of active bone formation surfaces, which were limited by osteoid and cuboidal osteoblasts. Osteoblastic activity was determined by a semi-quantitative scoring as no activity (0), mild activity (1), moderate activity (2), and high activity (3).

### Statistical Analysis

Statistical analyses were performed with SPSS 14.0 for Windows (SPSS, Inc., Chicago, IL, USA). Kolmogorov-Smirnov test was performed for determined data distribution. Data did not disturb normally, thus nonparametric tests were performed. Comparisons between the four groups were performed using the Kruskal-Wallis test. Two independent group comparisons were performed using Mann-Whitney U test. Data were presented as mean ± standard deviation and  $p < 0.05$  was considered statistically significant. The ratios of the presence of ICI and osteoblastic activity were analyzed using a chi-square test.

## RESULTS

The animals did not show any obvious signs of systemic illness throughout the study period.

### Serum and Gingival Homogenate IL-1β Levels

The serum and gingival homogenate IL-1β levels in the LO group were statistically higher than in the NL and LOZ groups ( $p < 0.05$ ). However, there were no significant differences between the NL and LOZ groups ( $p > 0.05$ ). (Table.1)

<sup>§</sup> Merck&Co., Rahway, NJ.

\*\* Stemi DV4, Carl Zeiss, Germany)

<sup>††</sup> Nikon Eclipse 80i, Nikon, Tokyo, Japan)

**Table.1** Serum and Gingival Homogenate IL-1 $\beta$  Levels and IL-10 Levels in the NL, LO, LOZ groups.

Groups	Serum IL-1 $\beta$ levels		Gingival IL-1 $\beta$ levels		Serum IL-10 levels		Gingival IL-10 levels	
	$\bar{X} \pm S$	(min – max)median	$\bar{X} \pm S$	(min – max)median	$\bar{X} \pm S$	(min – max)median	$\bar{X} \pm S$	(min – max)median
<b>NL</b>	4,68 $\pm$ 2,10	(1,79-6,25) 5,35	6,02 $\pm$ 3,59	(1,79-9,82) 6,25	21,44 $\pm$ 12,08	(7,81-33,25) 22,35	89.80 $\pm$ 18.60*	(62.50-103.78) 96.47
<b>LO</b>	96,95 $\pm$ 6,86*	(88,26-105,00) 97,27	63,69 $\pm$ 5,17*	(56,98-69,58) 64,11	3,90 $\pm$ 2,20*	(2,13-7,10) 3,19	22.71 $\pm$ 20.07	(2.84-43.75) 22.13
<b>LOZ</b>	21,23 $\pm$ 12,65	(6,25-34,93) 21,87	9,60 $\pm$ 8,03	(1,79-16,97) 9,82	20,97 $\pm$ 13,17	(7,10-37,75) 19,51	52.59 $\pm$ 17.97	(26.96-65.51) 58.95
	KW = 9,40 p = 0,009		KW = 7,49 p = 0,024		KW = 7,00 p = 0,030		KW = 7,53 p = 0,023	

\* $p < 0.05$  statistically significant

**NL:** Non-Ligated Group

**LO:** Ligature-Only Group

**LOZ:** Ligature + Ozone Group

**Table.2** Mean alveolar bone loss (mm).

Groups	Mean Alveolar Bone Loss (mm)	
	$\bar{X} \pm S$	(min – max) median
Non-Ligated Group	0.91 $\pm$ 0.22	(0.51 – 1.10) 0.99
Ligature-Only Group	1.54 $\pm$ 0.13*	(1.30 – 1.67) 1.59
Ligature + Ozone Group	0.94 $\pm$ 0.16	(0.68 – 1.12) 0.90
	KW = 14.18 p = 0.001*	

\* $p < 0.05$  statistically significant

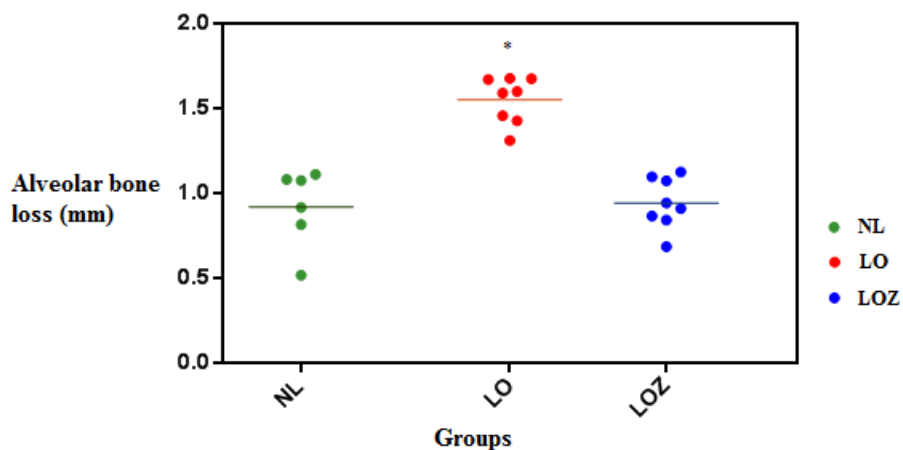
### Serum and Gingival Homogenate IL-10 Levels

The serum IL-10 level in the LO group was statistically lower than in the NL and LOZ groups ( $p < 0.05$ ). There were no significant differences between the NL and LOZ groups ( $p > 0.05$ ).

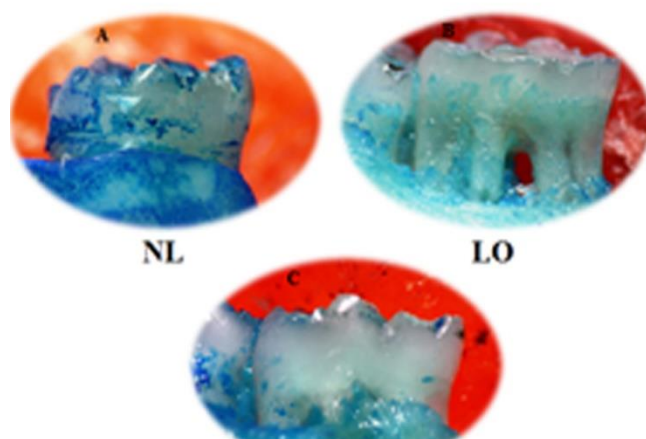
The gingival homogenate IL-10 level in the NL group was statistically higher than in the LO group ( $p < 0.05$ ). There were no significant

differences between the LOZ group and the other groups ( $p > 0.05$ ) (Table 1)

Measurements of alveolar bone loss in mandibular molars revealed significantly higher bone loss values in the LO group compared with the NL and LOZ groups ( $p < 0.05$ ). The alveolar bone loss in the NL group was less than in the LOZ group, but the difference was not significant between the two groups ( $p > 0.05$ ) (Figures 1 and 2).



**Figure 1.** Mean alveolar bone loss in the NL, LO and LOZ groups. \* $p < 0.05$  versus the NL and LOZ groups. Lines = mean values

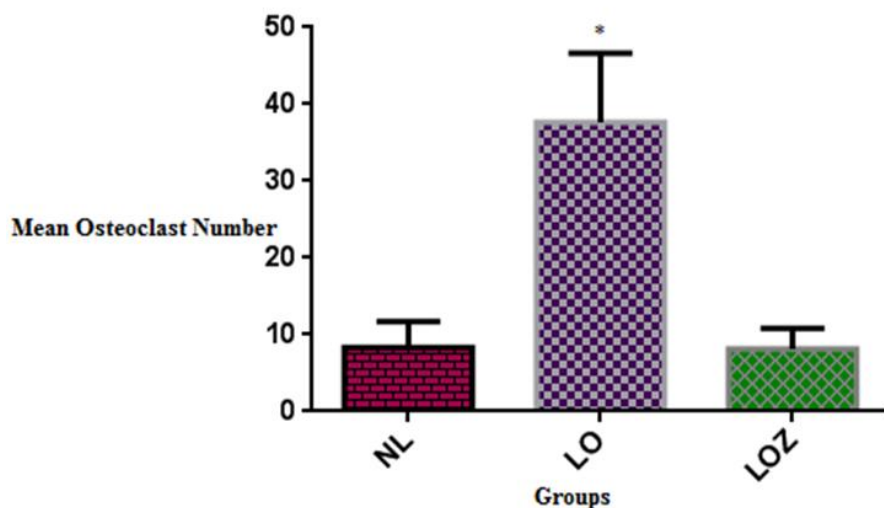


**Figure 2.** Representative photographs of the alveolar bone loss in the mandibular first molar tooth in the NL(A), LO(B) and LOZ(C) groups

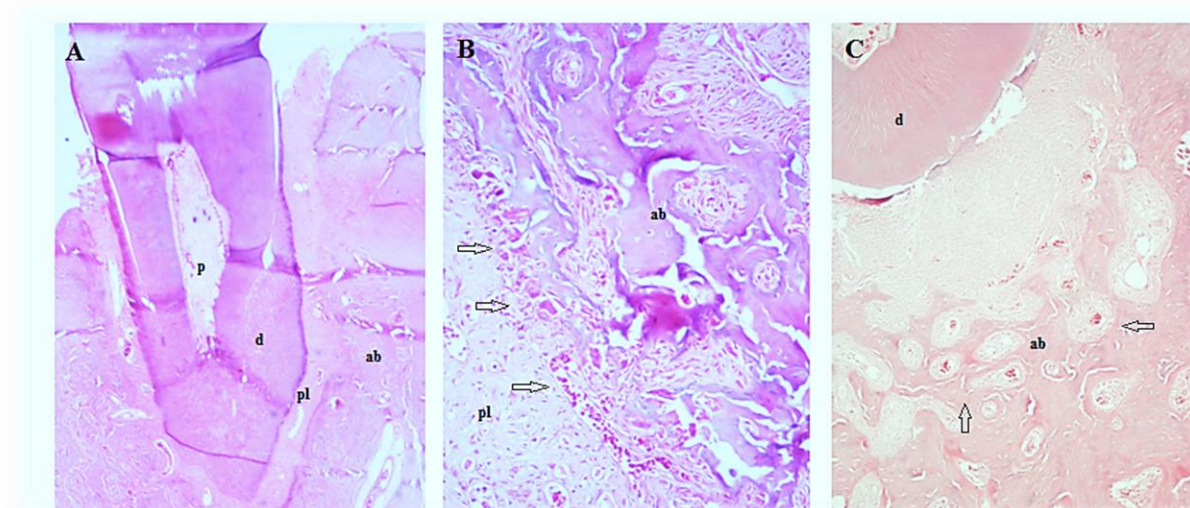
### Osteoclast Number

Figure 3 presents the osteoclast numbers in the study groups. When the mean osteoclast numbers were compared, the differences

between the NL and LO groups and the LO and LOZ groups were significant ( $p < 0.05$ ). There were no significant differences between the NL and LOZ groups ( $p > 0.05$ ) (Figure 4)



**Figure 3.** Osteoclast numbers in the NL, LO and LOZ groups. \* $P < 0.05$  versus the NL and LOZ groups. Lines = mean values.



**Figure 4.** Histopathology of mandibular first molar tooth in all groups. (A) Normal mandibula, showing (B) Mandibula after 14 days of periodontitis in the ligature only (LO) group; mainly alveolar bone with numerous osteoclasts (arrows). (C) Mandibula in the ligature plus ozone (LOZ) group after 14 days of periodontitis, showing increased osteoblastic activity (arrows) (hematoxylin and eosin stain ; original magnification A, X4; B, X20 and C, X10)

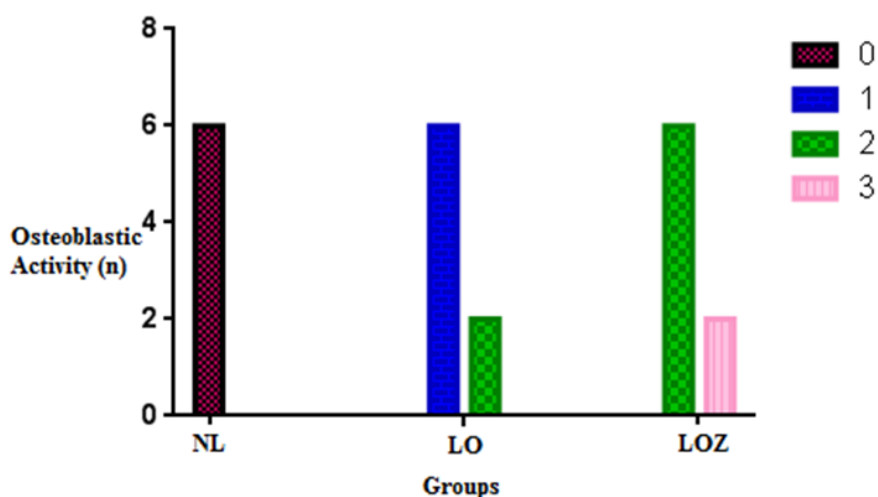
*ab.* alveolar bone, *pl.* periodontal ligament, *d.* dentin and *p.* pulp

#### Osteoblastic Activity

The highest osteoblastic activity occurred in the LOZ group and the differences from other groups were statistically significant ( $p < 0.05$ ).

Additionally, there were significant differences between the NL and LO groups ( $p < 0.05$ ) (Figure 5)



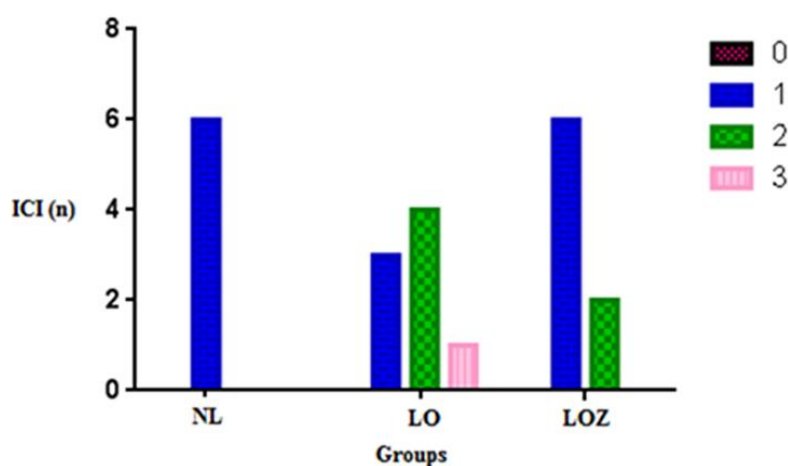


**Figure 5.** Osteoblastic Activity in the NL, LO, LOZ groups. NL, nonligated; LO, ligature only; LOZ, ligature plus ozone. no activity (0), mild activity (1), moderate activity (2) and high activity (3).

#### Inflammatory Cell Infiltrate (ICI)

The difference between the NL and LO groups was significant ( $p < 0.05$ ). There were no

significant differences between the NL and LOZ groups ( $p > 0.05$ ) (Figure 6).



**Figure 6.** Inflammatory Cell Infiltrate (ICI) in the NL, LO, LOZ groups. NL, nonligated; LO, ligature only; LOZ, ligature plus ozone. no visible ICI (0), slightly visible ICI (1), moderate ICI (2) and the dense ICI (3).

## DISCUSSION

In the present study, we evaluated the effect of ozone on alveolar bone loss and IL-1 $\beta$ , IL-10 levels in experimental periodontitis in a rat model. Several models of experimental periodontitis, such as dietary manipulation,

introduction of pathogenic microorganisms, and placement of a ligature, have been described in the literature<sup>24,25</sup> Ligature methods have been accepted as useful experimental models of periodontitis with alveolar bone resorption<sup>24,26</sup> In our study, ligature placement on the first



molar tooth caused a significant amount of bone loss. However, for every animal model of a human disease, there are inherent limitations. Molars in rats are similar in anatomic configuration and structure to those in humans, but the molars of rats are smaller, so it was difficult to perform any sort of periodontal treatment<sup>27</sup>. A further limitation to the experimental model used is that the induced periodontitis follows an acute course, during which tissue trauma and adjacent microbial accumulation accelerate the destructive process. Such pathways of acute inflammation are likely to differ from chronic periodontitis<sup>28</sup>. Nevertheless, the ligature model is useful for evaluating bone loss in animal models. Overall, in our laboratory settings, ozone decreased the alveolar bone loss and IL-1 $\beta$ , while it increased IL-10 levels in experimental periodontitis.

Periodontitis is a complicated disorder that depends on a number of factors, but inflammatory cell accumulation induced by microorganisms in the gingival connective tissues is considered to be the main causative factor. The majority of the bacteria is located in the periodontal pocket and does not invade the periodontal tissues; therefore, these microorganisms can never be removed effectively by the host immune system. Consequently, chronic inflammation and extreme, unceasing host responses, including the recruitment of leukocytes and the subsequent release of inflammatory mediators and cytokines, can cause periodontal pathology<sup>15</sup>.

Some authors have tried to assess the usefulness of ozone application in periodontal treatments. Menable et al.<sup>29</sup> pointed out the beneficial therapeutic effect of ozone application in the treatment of periodontitis. The authors observed a reduction in gingival index, plaque index, and probing depth that helped to restore the normal clinical status of gingiva within three days, ascribing the decreased bleeding of the gums and their restored normal color to ozonotherapy. Brauner<sup>30</sup> compared the clinical periodontal status between patients who underwent scaling and root planing (SRP) and those instructed to use ozonated water, which cannot replace professional dental plaque removal. They concluded that the ozone was marginally better than the negative control, but had a limited effect on periodontal tissue and bone at histopathologic levels after the administration

of ozone. Therefore, to the best of our knowledge, the present study is unique in that it demonstrates an effect on periodontal tissue IL-1 $\beta$ , IL-10 levels and bone at the histopathologic levels after the administration of ozone.

Ozone causes the synthesis of biologically active substances such as interleukins, leukotrienes, and prostaglandins. Ozone influences the cellular and humoral immune systems and stimulates the proliferation of immunocompetent cells and synthesis of immunoglobulins. It also activates function macrophages and increases sensitivity of microorganisms to phagocytosis<sup>15</sup>. In a study, B-dependent transcription and the expression of the NF-kappa B target genes Interleukin-8 (IL-8) and IL-1<sup>31</sup> were prevented by an O<sub>3</sub> medium. Both cytokines have been correlated with the biological and clinical severity of periodontal disease<sup>32</sup> and are secreted by various cells, e.g., epithelial cells, fibroblasts, and monocytes/macrophages. IL-8 expression shows the rapid onset in an early inflammatory stage and exerts chemotactic/activation effects on neutrophils<sup>33,34</sup>. IL-1, when inadequately expressed, is known to mediate tissue-destructive effects, e.g., bone resorption and loss of periodontal attachment<sup>32,35</sup>.

Considering these research studies and data, we thought ozone might play an important role in preventing the initiation and progression of periodontal disease and suppress IL-1 $\beta$ . For this reason, we aimed to examine the effects of locally ozone administration, histologically and morphometrically, in an experimental rat periodontitis model. The results of this study show ozone diminished periodontal inflammation and alveolar bone loss, IL-1 $\beta$  in experimental periodontitis.

In recent years, ozone has been introduced as an alternative antibacterial treatment to the use of antibacterial bonding systems or material with antibacterial properties<sup>22,36</sup>. Ozone has been recognized as a strong and effective antibacterial<sup>37</sup> and antimicrobial<sup>19</sup> agent. The application of ozone gas has been advocated for use in dentistry for the sterilizing of cavities, root canals, periodontal pockets and herpetic lesions<sup>38</sup>.

Muller et al.<sup>39</sup> compared the influence of ozone gas with photodynamic therapy (PDT) and known antiseptic agents (2% chlorhexidine, 0.5 and 5% hypochlorate solutions) on a

multispecies oral biofilm in vitro. The following bacteria were studied: *Actinomyces naeslundii*, *Veillonella dispar*, *Fusobacterium nucleatum*, *Streptococcus sobrinus*, *streptococcus oralis*, and *Candida albicans*.

Little is known about the effects of ozone on cell function or the morphology of bone cells. The osteoclast number increased in all rats after ligature placement, but administration of ozone decreased ICI, osteoclast number, and the alveolar bone loss. Furthermore, osteoblastic activity decreased in all rats after ligature placement on the first molar tooth, but administration of ozone increased its level to normal. However, according to Matsumura et al.<sup>40,41</sup>, ozone does not have a major impact on stimulation of gingival cells for osteoblastic activity in the regeneration of the periodontium around implants.

In a study, the influence of ozonized water on the epithelial wound healing process in the oral cavity was observed by Filippi.<sup>42</sup> It was found that ozonized water applied on the daily basis can accelerate the healing rate in oral mucosa.

## REFERENCES

1. Duang XY, Wang Q, Zhou XD, Huang DM. Mangiferin: a possible strategy for periodontal disease to therapy. *Med Hypotheses* 2011; 76: 486-88.
2. Breivik T, Gundersen Y, Osmundsen H, Fonnum F, Opstad PK. Neonatal dexamethasone and chronic tianeptine treatment inhibit ligature-induced periodontitis in adult rats. *J Periodontal Res* 2006; 41: 23-32.
3. Kinane DF, Causation and pathogenesis of periodontal disease. *Periodontol* 2000 2001; 25: 8-20.
4. Page RC, The role of inflammatory mediators in the pathogenesis of periodontal disease. *J Periodontal Res* 1991; 26: 230-42.
5. Gursoy UK, Könönen E, Uitto V-J. Stimulation of epithelial cell matrix metalloproteinase (MMP-2, -9, -13) and interleukin-8 secretion by fusobacteria. *Oral Microbiol Immunol* 2008; 23: 432-34.
6. Dewhirst FE, Stashenko PP, Mole JE, Tsurumachi T. Purification and partial sequence of human osteoclast-activating factor: identity with interleukin 1 beta. *J Immunol.* 1985; 135: 2562-8.
7. Matsuki Y, Yamamoto T, Hara K. Interleukin-1 mRNA-expressing macrophages in human chronically inflamed gingival tissues. *Am J Pathol* 1991; 138: 1299-305.
8. Matsuki Y, Yamamoto T, Hara K. Detection of inflammatory cytokine messenger RNA (mRNA)-expressing cells in human inflamed gingiva by combined in situ hybridization and immunohistochemistry. *Immunology* 1992; 76: 42-7.
9. Hönig J, Rordorf-Adam C, Siegmund C, Wiedemann W, Erard F. Increased interleukin-1 beta (IL-1 beta) concentration in gingival tissue from periodontitis patients. *J Periodont Res* 1989; 24: 362-67.
10. Tokoro Y, Yamamoto T, Hara K. IL-1 beta mRNA as the predominant inflammatory cytokine transcript: correlation with inflammatory cell infiltration into human gingiva. *J Oral Pathol Med* 1996; 25: 225-31.
11. Preshaw PM, Taylor JJ. How has research into cytokine interactions and their role in driving

This effect can be seen in the first two postoperative days.

In comparison with classical periodontal treatment modalities, such as systemic ve local antimicrobials, ozone therapy is quite inexpensive, and according to many case reports and scientific studies, it is very promising. However, further research is needed to standardize the indications and treatment procedures of ozone therapy. To the best of our knowledge, this study represents, within the inherent limitations of experimental animal and human disease interventions, the first attempt to evaluate the role of administered ozone in the development of experimental periodontal inflammation and bone loss. Ozone decreased alveolar bone loss in experimental periodontitis in a ligature-induced rat model. We suggest that ozone may play an important role as an adjunct to periodontal treatment in preventing periodontal diseases, after a further evaluation of its effects in experimental and clinical studies.

- immune responses impacted our understanding of periodontitis? *J Clin Periodontol* 2011; 38: 60-84.
12. Arai T, Hiromatsu K, Kobayashi N, Takano M, Ishida H, Nimura Y, Yoshikai Y. IL-10 is involved in the protective effect of dibutyl cyclic adenosine monophosphate on endotoxin-induced inflammatory liver injury. *J Immunol* 1995; 155: 5743-9.
  13. Tumphey TM, Elnor VM, Chen SH, Oakes JE, Lausch RN. Interleukin-10 treatment can suppress stromal keratitis induced by herpes simplex virus type 1. *J Immunol* 1994; 153: 2258-65.
  14. Bocci VA. Scientific and medical aspects of ozone therapy. State of the art. *Arch Med Res* 2006; 37: 425-35.
  15. Seidler V, Linetskiy I, Hubáľková H, Stanková H, Smucler R, Mazánek J. Ozone and its usage in general medicine and dentistry. A review article. *Prague Med Rep* 2008; 109: 5-13.
  16. Adusumilli S, Manthana S, and Anumolu V. Application of ozone in the treatment of periodontal disease *J Pharm Bioallied Sci* 2013; 5: 89-94.
  17. Azarpazhooh A, Limeback H, The application of ozone in dentistry: a systematic review of literature. *J Dent* 2008; 36: 104-16.
  18. Huth KC, Jakob FM, Saugel B, Cappello C, Paschos E, Hollweck R, Hickel R, Brand K. Effect of ozone on oral cells compared with established antimicrobials. *Eur J Oral Sci* 2006; 114: 435-40.
  19. Sagai M, Bocci V. Mechanisms of Action Involved in Ozone Therapy: Is healing induced via a mild oxidative stress? *Med Gas Res* 2011; 20: 1-29.
  20. Polydorou O, Halili A, Wittmer A, Pelz K, Hahn P. The antibacterial effect of gas ozone after 2 months of in vitro evaluation. *Clin Oral Investig* 2012; 16: 545-50.
  21. Polydorou O, Pelz K, Hahn P. Antibacterial effect of an ozone device and its comparison with two dentin-bonding systems. *Eur J Oral Sci* 2006; 114: 349-53.
  22. Baysan A, Lynch E. Effect of ozone on the oral microbiota and clinical severity of primary root caries. *Am J Dent* 2004; 17: 56-60.
  23. Sakallıođlu E.E, Ayas B, Lutfiođlu M, Keleş G.Ç, Açıkgöz G, Fıratlı E. Gingival levels of monocyte chemoattractant protein-1 (MCP-1) in diabetes mellitus and periodontitis: an experimental study in rats. *Clin Oral Invest* 2008; 12: 83-89.
  24. de Lima V, Bezerra MM, de Menezes Alencar VB, Vidal FD, da Rocha FA, de Castro Brito GA, de Albuquerque Ribeiro R. Effects of chlorpromazine on alveolar bone loss in experimental periodontal disease in rats. *Eur J Oral Sci* 2000; 108: 123-9.
  25. Buduneli E, Vardar S, Buduneli N, Berdeli AH, Türkođlu O, Bařkesen A, Atilla G. Effects of combined systemic administration of low-dose doxycycline and alendronate on endotoxin-induced periodontitis in rats. *J Periodontol* 2004; 75: 1516-23.
  26. Holzhausen M, Spolidorio DMP, Muscara MN, Hebling J, Spolidorio LC. Protective effects of etoricoxib, a selective inhibitor of cyclooxygenase-2, in experimental periodontitis in rats. *J Periodontal Res* 2005; 40: 208-11.
  27. Xu Y, Wei W. A comparative study of systemic subantimicrobial and topical treatment of minocycline in experimental periodontitis of rats. *Arch Oral Biol* 2006; 51: 794-803.
  28. Di Paola R, Mazzon E, Zito D, Maiere D, Britti D, Genovese T, Cuzzocrea S. Effects of Tempol, a membrane-permeable radical scavenger, in a rodent model periodontitis. *J Clin Periodontol* 2005; 32: 1062-68.
  29. Menabde GT, Natroshvili ND, Natroshvili TD. [Ozonotherapy for the treatment of parodontitis]. *Georgian Med News* 2006; 134: 43-6.
  30. Brauner AW. Periodontology: New Methods. Ozone: Science & Engineering 1992; 14: 165-76.
  31. Pahl HL. Activators and target genes of Rel/NF-kappaB transcription factors. *Oncogene*. 1999; 18: 6853-66.
  32. Gamonal J, Acevedo A, Bascones A, Jorge O, Silva A. Levels of interleukin-1 beta, -8, and -10 and RANTES in gingival crevicular fluid and cell populations in adult periodontitis patients and the effect of periodontal treatment. *J Periodontol* 2000; 71: 1535-45.
  33. Okada H, Murakami S. Cytokine expression in periodontal health and disease. *Crit Rev Oral Biol Med* 1998; 9: 248-66.
  34. Bartold PM, Narayanan AS. Molecular and cell biology of healthy and diseased periodontal tissues. *Periodontol* 2000. 2006; 40: 29-49.
  35. Graves DT, Jiang Y, Genco C. Periodontal disease: bacterial virulence factors, host response and impact on systemic health. *Curr Opin Infect Dis* 2000; 13: 227-32.

36. Millar BJ, Hodson N. Assessment of the safety of two ozone delivery devices. *J Dent* 2007; 35: 195-200.
37. Sharma M, Hudson JB. Ozone gas is an effective and practical antibacterial agent. *Am J Infect Control* 2008; 36: 559-63.
38. Baysan A, Lynch E. The use of ozone in dentistry and medicine. *Prim Dent Care* 2005; 12: 47-52.
39. Müller P, Guggenheim B, Schmidlin PR. Efficacy of gasiform ozone and photodynamic therapy on a multispecies oral biofilm in vitro. *Eur J Oral Sci* 2007; 115: 77-80.
40. Matsumura K, Hyon SH, Nakajima N, Iwata H, Watazu A, Tsutsumi S. Surface modification of poly(ethylene-co-vinyl alcohol): hydroxyapatite immobilization and control of periodontal ligament cells differentiation. *Biomaterials*. 2004; 25: 4817-24.
41. Matsumura K, Hyon SH, Nakajima N, Tsutsumi S. Effects on gingival cells of hydroxyapatite immobilized on poly(ethylene-co-vinyl alcohol). *J Biomed Mater Res A* 2007; 82: 288-95.
42. Fillipi A. The influence of ozonised water on the epithelial wound healing process in the oral cavity. *Radiology and Oral Medicine*, 2001.