



Diaphragmatic Mesothelial Cyst And Percutaneous Ethanol Sclerotherapy: In A Young Girl**

Levent Cankorkmaz^{1,a,*}, İsmail Şalk^{2,b}, Mehmet H. Atalar^{2,c}

¹ Department of Pediatric Surgery, Sivas Cumhuriyet University, Faculty of Medicine, Sivas, Türkiye

² Department of Radiology, Sivas Cumhuriyet University, Faculty of Medicine, Sivas, Türkiye

*Corresponding Author


**This study was presented at the 16th Congress of Hungarian Association of Pediatric Surgeons, October 14th – 16th, September 2017, in Szeged, Hungary.

Case Report

History

Received: 11/03/2024
Accepted: 27/07/2024

Copyright


This work is licensed under
Creative Commons Attribution 4.0
International License

ABSTRACT

Diaphragmatic mesothelial cysts are rare congenital lesions that are lined with mesothelial cells. The diagnosis might be problematic because of their rarity and anatomic location. We report a case of with a diaphragmatic cyst in a 6-year-old girl. In this case, the cyst was found incidentally. We found a thin-wall, homogeneous cyst, which was between the lateral aspects of the liver and diaphragm with radiological imaging. The patient was planned for cyst aspiration and ethanol sclerotherapy was made based on the imaging findings. The cyst was aspirated and then performed ethanol sclerotherapy. The cytological findings of the cyst fluid were appeared to be degenerated histiocytes and mesothelial cells. If treatment is needed, percutaneous treatment is conceivable as the first choice of technique.

Keywords: Mesothelial cyst, Child, Ethanol Sclerotherapy

Bir Kız Çocukta Diyafragmatik Mezotelyal Kist ve Perkütan Etanol Skleroterapisi

Olgu Sunumu

Süreç

Geliş: 11/03/2024
Kabul: 27/07/2024



Telif Hakkı




Bu Çalışma Creative Commons Atf
4.0 Uluslararası Lisansı
Kapsamında Lisanslanmıştır.


ÖZET


Diyafragmatik mezotelyal kistler, mezotelyal hücrelerle döşeli, nadir görülen konjenital lezyonlardır. Nadir görülmeleri ve anatomik yerleşimleri nedeniyle tanıları sorunlu olabilir. Biz 6 yaşında diyafragma kisti olan kız çocuğu olguyu sunuyoruz. Bu vakada kist tesadüfen tespit edilmişti. Radyolojik görüntüleme karaciğer laterali ile diyafram arasında ince duvarlı, homojen kist saptandı. Görüntüleme bulgularına göre hastaya kist aspirasyonu planlandı ve etanol skleroterapi uygulandı. Kist aspire edildi ve ardından etanol skleroterapi uygulandı. Kist sıvısının sitolojisinde dejenerer histiositler ve mezotelyal hücreler saptandı. Lezyonlarda tedavi gerekiyorsa perkütan tedavi ilk seçenek olarak düşünülebilir.

Anahtar Kelimeler: Mezotelyal kist, Çocuk, Etanol skleroterapi

^a  lcankorkmaz@gmail.com
^c  mhatalar@gmail.com

^{ib}  0000-0003-1525-1470
^{ib}  0000-0003-3076-8072

^b  ismailsalk@gmail.com

^{ib}  0000-0002-5156-6923

How to Cite: Cankorkmaz L, Şalk İ, Atalar MH. Diaphragmatic Mesothelial Cyst And Percutaneous Ethanol Sclerotherapy: In A Young Girl. Cumhuriyet Medical Journal. 2024;46(3): 211-213

Introduction

Diaphragmatic mesothelial cysts (DMC) are uncommon congenital lesions, especially for pediatric patients lined by mesothelial cells. The diagnosis might be problematic because of their rarity and anatomic location.^{1,2} MC in small size is usually asymptomatic and diagnosis is generally based on the imaging.² We report a case of a diaphragmatic cyst in a 6-year-old girl. US is the initial diagnostic examination for children, and it has been reported that the finding of a thin-walled and bilobate cyst in the posterolateral aspect of the right costophrenic angle, and an extracapsular location of the liver is very suggestive of the diagnosis.¹

Case Report

In our case, the chief complaint was abdominal pain, and the cyst had been found incidentally by Ultrasonography (US). There was not a family history of hydatid cysts or trauma. We performed US and computed tomography (CT) (Figure 1-2). It was found in the US, a thin-wall, homogeneous cyst, which was between the lateral aspects of the liver and diaphragm determined with CT. The dimension of the cyst was 35X25X55 mm (ML-AP-CC). Laboratory investigations yielded normal results.

The patient was planned for cyst aspiration and ethanol sclerotherapy was made based on the imaging

findings because she had abdominal pain. The cyst was aspirated and then performed ethanol sclerotherapy. The cytological findings of the cyst fluid were appeared to be degenerated histiocytes and mesothelial cells, features of a cystic fluid. Ethanol was chosen as the sclerosing solution because it has been commonly used for sclerosing hepatic, renal, and splenic hydatid cysts safely and successfully.^{3,4} Cyst disappeared completely in case after the procedure, in follow-up was nonproblematic.

Discussion

Diaphragmatic masses present a radiological challenge because of cysts' infrequency and the difficulty of establishing exact anatomical relationships concerning neighboring structures such as the pleura, lungs, spleen, or liver, where the disease is much more frequent.⁵ Diaphragmatic mesothelial cysts arise from coelomic remnants. Other cystic lesions of the diaphragm include bronchogenic cysts, teratoma, and hydatid cysts. Mesothelial cysts may also be detected in organs such as the spleen, adrenal gland, ovary, falciform ligament, vaginal process of the testicle, and mesentery.⁶ Surgery may be necessary if the cyst is large or symptomatic. If treatment is needed, percutaneous treatment is conceivable as the first choice of technique.

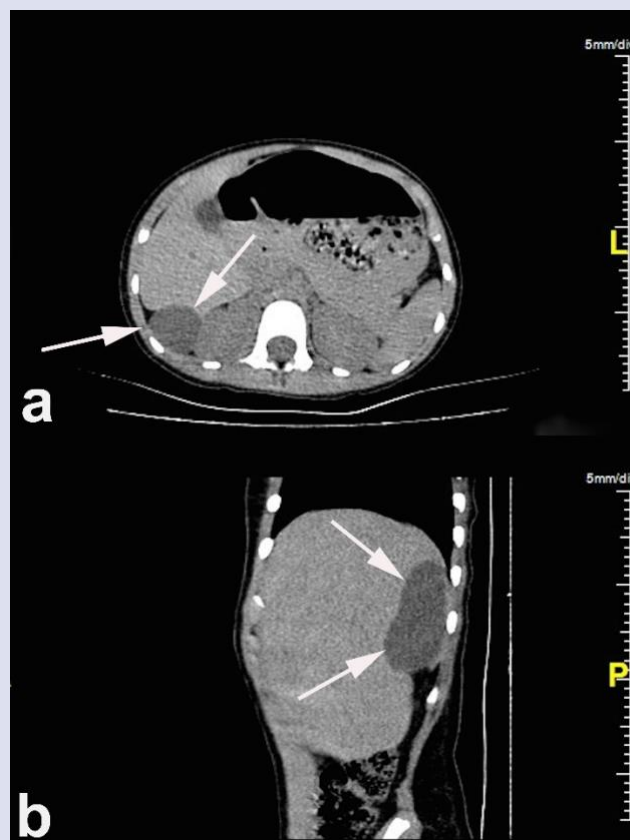


Figure 1: Pretreatment axial (a) and sagittal reformatted (b) computed tomography images show diaphragmatic mesothelial cyst (arrows).

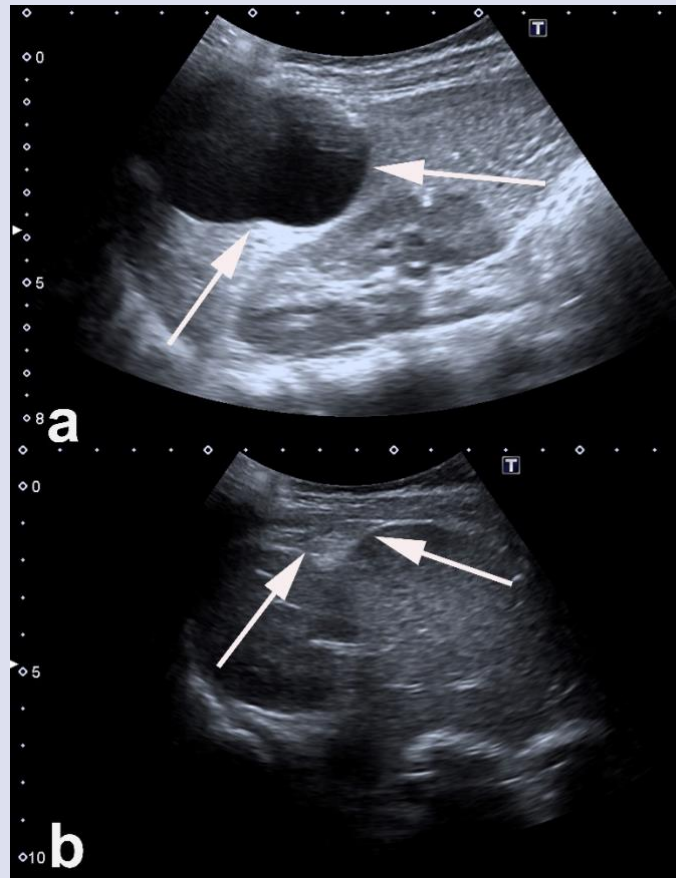


Figure 2: Ultrasound images, (a) pretreatment image shows cystic lesion (arrows) with thin hyperechoic wall, and (b) post-treatment image shows after complete aspirated of diaphragmatic mesothelial cyst (arrows).

References

1. Akinci D, Akhan O, Ozmen M, Ozkan OS, Karcaaltincaba M. Diaphragmatic mesothelial cysts in children: radiologic findings and percutaneous ethanol sclerotherapy. *AJR Am J Roentgenol.* 2005; 185(4): 873-7.
2. Yang M, Xiang B, Xie XL, Li KW, Li FY. Retroperitoneal mesothelial cyst misdiagnosed as a congenital choledochal cyst for an infant patient: A case report and literature review. *Int J Surg Case Rep.* 2020; 71:176-178. doi: 10.1016/j.ijscr.2020.04.075.
3. Bean WJ, Rodan BA. Hepatic cysts: treatment with alcohol. *AJR* 1985; 144:237-241.
4. Akinci D, Akhan O, Ozmen M, et al. Long-term results of single-session percutaneous drainage and ethanol sclerotherapy in simple renal cysts. *Eur J Radiol* 2005; 54: 298-302.
5. Esparza Estaún J, González Alfageme A, Sáenz Bañuelos J. Radiological appearance of diaphragmatic mesothelial cysts. *Pediatr Radiol* 33, 855-858 (2003). Doi: 10.1007/s00247-003-1014-6.
6. Estaun JE, Alfageme AG, Banuelos JS. Radiologic appearance of diaphragmatic mesothelial cysts. *Pediatr Radiol.* 2003; 33: 855-858.