

Verrucous carcinoma of the external auditory canal: a report of two cases

Dış kulak yolu verrüköz karsinomali iki olgu sunumu

Emine Elif Altuntaş, Mehmet Yaşar, Mansur Doğan, Suphi Müderris, Fahrettin Göze

Departments of Otorhinolaryngology (Assist. Prof. E. E. Altuntaş, MD; M. Yaşar, MD; M. Doğan, MD; Prof. S. Müderris, MD) and Pathology (Prof. F. Göze, MD), Cumhuriyet University School of Medicine, TR-58140 Sivas

Abstract

Verrucous carcinoma can be observed in the genital part, nasal fossa and esophagus in addition to the larynx and oral cavity that is more commonly seen in men. Verrucous carcinoma of the ear is an extremely rare and special form of squamous cell carcinoma. There are only tree cases well documented in the literature related to the rarely observed verrucous carcinoma of the ear. We have described two cases of verrucous carcinoma on the tract. In etiology, tobacco and alcohol abuse and bad mouth hygiene have been put forward as the causes. Its diagnosis is rather difficult because while it may display invasive characteristic clinically, it may not give any malignity findings histologically and especially cytologically. Verrucous carcinomas exhibit low degree malignity biologically. A close cooperation between the surgeon and the pathologist is required in order to prevent mistaken diagnosis. Most resorted treatment method of verrucous carcinoma is surgery. However in the recent years, there have been treatment reports in the literature with the methods like suction, diathermy, cryosurgery and laser surgery. In this study, two male patients diagnosed with ‘‘Verrucous Carcinoma’’ and age 45 and 26 respectively were involved and the literature was reviewed.

Keywords: Verrucous carcinoma, external auditory canal

Özet

Verrüköz karsinomali sıklıkla genital bölge, nazal kavite, larenks, oral kavite ve özefagusda görülür. Erkeklerde kadınlara göre daha fazla izlenmektedir. Verrüköz karsinoma skuamöz hücreli karsinomun özel bir formudur ve kulakta son derece nadir görülür. Literatürde kulakta verrüköz karsinomlu üç olgu bulunmaktadır. Etiyolojisinde sigara ve alkol kullanımı ile kötü oral hijyen rol oynamaktadır. Kliniğinin invaziv karakterde olması histolojik ve sitolojik olarak malignensi özelliklerini göstermemesi nedeni ile tanı konulması zor bir patolojidir. Verrüköz karsinomaların biyolojik davranışı düşük dereceli maligniteler gibidir. Verrüköz karsinomalar cerrahi olarak tedavi edilmekle birlikte son yıllarda suction benzeri metotlar, diathermi, krioterapi ve laserle yapılan tedavi seçenekleri de literatürde yer almaya başlamıştır. Bu çalışmada ‘‘Verrucous Carcinoma’’ tanısı almış 45 ve 26 yaşlarında ki iki erkek hastayı literatür bilgilerinde gözden geçirilerek sunuldu.

Anahtar kelimeler: Verrüköz karsinoma, dış kulak yolu

Geliş tarihi/Received: March 16, 2009; **Kabul tarihi/Accepted:** April 27, 2009

Corresponding author:

Dr. Emine Elif Altuntaş, Kulak Burun Boğaz Anabilim Dalı, Cumhuriyet Üniversitesi Tıp Fakültesi, TR-58140 Sivas. Email: ealtunta@yahoo.com

Introduction

The term “verrucous carcinoma” was first used by Ackerman in 1948 and 31 cases were presented [1]. It is more commonly observed in men. Similar to verrucous carcinoma’s lesions are also described in some other parts of the body. It can be observed in the genital part, nasal fossa and esophagus in addition to the larynx and oral cavity [2, 3]. Only three cases of the external ear tract have been published [4, 5]. It is kind of a tumor which is prone to grow slowly and which has a papillomatous quality which can easily invade the surrounding tissues. In the clinic, conductive type audio loss because of the mass blocking the external ear tract and ear flow in the shape of mucopurulent flow from the external ear canal may be observed. Though not proven yet; tobacco, alcohol and cigarette are emphasized in the etiology [2, 6, 7]. In addition to different opinions about its scale, the best treatment is regarded as the surgical excision. Moreover, its diagnosis is rather difficult because while it may display invasive characteristic clinically, it may not give any malignity findings histologically and especially cytologically. In the histologically distinguishing diagnosis; papilloma, senile keratosis and verruca vulgaris should be taken into consideration.

Case 1

One of the male patients, who are 45 years old, applied to our clinic with the complaints of audio loss, mass, and mucopurulent flow in the right ear. In the physical inspection of the patient; a mass on the right external ear tract which had a papillomatous appearance, obliterated the canal and was visible from outside, was identified. It was seen that the mass could have stemmed from the middle ear mucosa and it was extending towards the skin of the external ear tract posterior wall. The ear membrane could not be evaluated because of the mass. No other pathological finding was observed in the overall ENT (Ear Nose Throat) inspection. No lymph node on the neck could be palpated. There was not facial paralysis. There was no history of the patient related to alcohol and tobacco abuse. There was no bone and cartilage erosion at the temporal bone tomography of the patient. There was a slight conductive type audio loss in the purse sound audiogram. After the inspections, biopsy was not required because it was thought that the mass was premalignant. The mass was taken out via local anesthesia under the microscope with transmeatal approach and with the “sleeve” resection method (it was resected by way of uncovering a shirt’s sleeve taking 1 cm from the external ear tract mucosa with a normal appearance, on the periphery of the mass) from the posterior wall of the external ear tract. The ear membrane was evaluated as normal after the physical inspection following the operation. There was no recurrence in the 1 year post-operative period.

Case 2

The other patient was a male who is 26 years old, applied to our clinic with the complaints of audio loss and mass. In the physical inspection of the patient; a 5mm size verrucous mass on the left external ear tract (Figure 1). The ear membrane and the other inspections were normal. No other pathological finding was observed in the overall ENT (Ear Nose Throat) inspection. No lymph node on the neck could be palpated. There was not facial paralysis. He has got a lot of warts on your hands. There was no history of the patient related to alcohol and tobacco abuse. There was no bone and cartilage erosion at the temporal bone tomography of the patient. There was a slight conductive type audio loss in the purse sound audiogram. The mass was taken out via local anesthesia under the microscope with transmeatal approach and with the “sleeve” resection method (it was resected by way of uncovering a shirt’s sleeve taking 1 cm from the external ear tract mucosa with a normal appearance, on the periphery of the mass) from the posterior wall of the external ear tract. There was no recurrence in the 1 year post-operative period.

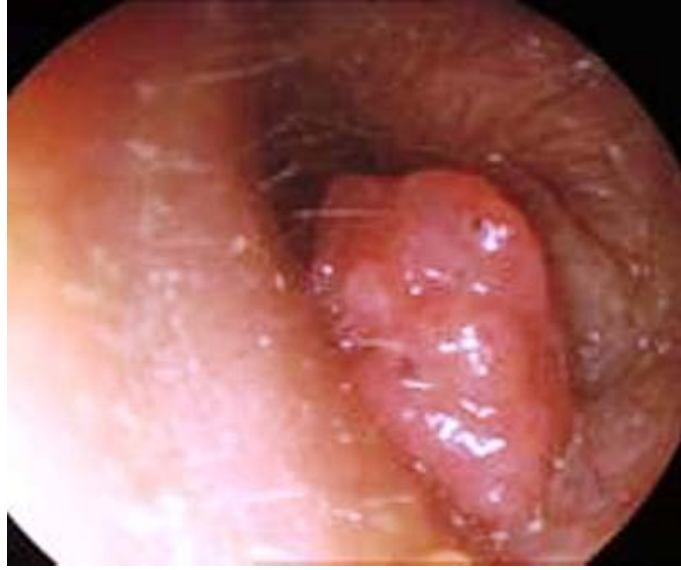

Figure 1. A mass on the right external ear tract which had a papillomatous appearance, obliterated the canal and was visible from outside was identified.

Histopathologic examination

Our cases were two men who were 45 and 26 years old respectively. There were no invasion of the surrounding tissues and lymph node metastasis by the tumors. The mass on the ear of the elder man stemmed from the middle ear mucosa and it extended to external ear skin posterior wall. Macroscopically, during the histopathologic examination of the mass which had a grey-pink and soft characteristic, a lesion was identified which occurred due to the partially intense and dysplastic proliferation of the papillomatous- verrucous epithel in addition to the intense hyperkeratosis lamellas (Figures 2 and 3).

Discussion

According to the reports of the three cases previously published in the literature, verrucous carcinoma of the external ear tract can stem from the cells of the mastoid bone, middle ear mucosa or the skin of the external ear tract. The characteristic features related to the tumor as defined by Ferlito [12] and his colleagues in a study based on 77 cases of verrucous carcinoma of the larynx were similar to the macroscopic and microscopic features of our study. According to Ferlito's criteria [11], the patients are usually old men; the lesion is white colored, exophytic, and has a papillomatous appearance; there is a high degree of cell differentiation and all the cytological aspects of the malignancy do not contain completely but sometimes there may be shows small focal cellular atypical findings; chronic inflammation is apparent on the stroma but this infiltration stems especially from lymphocytes and plasmocytes and these tumors do not cause metastasis practically.

If verrucous carcinoma invades the larynx, then it causes thyroid cartilage necrosis [8]. If it invades the oral cavity, it causes a surface bone erosion of the jaw bones without invading the bone marrow emptiness. No bone destruction has been observed either in our cases or in the temporal bone tomographic screenings taken for the previously published verrucous carcinoma of the external ear. Despite having benign histological appearance, the mass shows aggressive clinic behavior. In the histology, it is generally either misdiagnosed or inadequately diagnosed as "senile keratosis". It can be confused with keratoacanthoma, papilloma, cholesteatoma, well differentia flat cell carcinoma [9]. Therefore the clinician and the pathologist should be in very close cooperation.

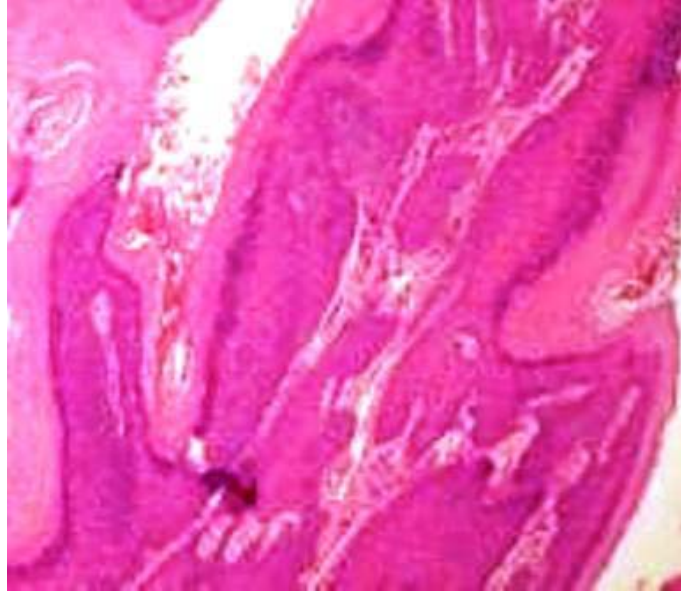


Figure 2. The panoramic appearance of a curettage-shaped material extracted from the external ear tract. Upwards, exophytic, papillary verrucous development, hyperkeratosis, hyper-granulose (H&E, x40).

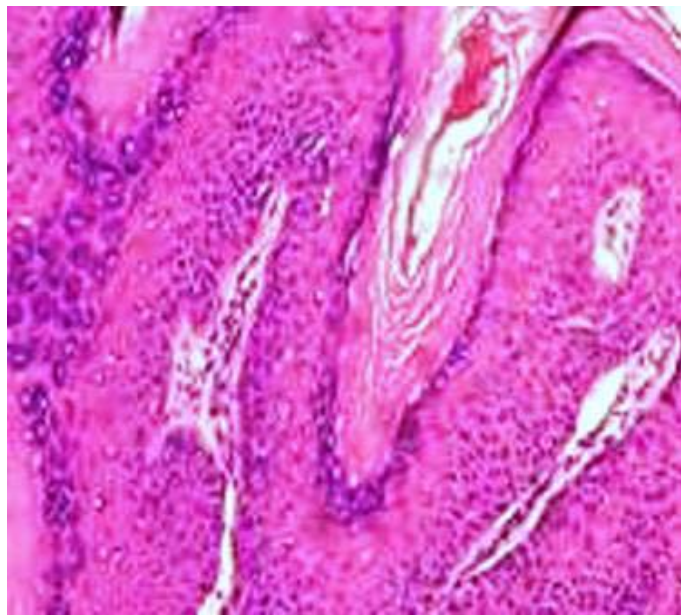


Figure 3. Details of a cell from another area: small papillary verrucous formations due to hyperkeratosis and hyper-granulose in addition to moderate dysplastic epithelium proliferation (H&E, x100).

Verrucous carcinomas exhibit low degree malignancy biologically. The tumor was kind of a one which blocked external ear tract by way of descending from middle ear mucosa, did not exhibit cause any temporal bone destruction and was localized and non-aggressive in both pour case and the three published cases. Practically, these tumors do not bring about lymph node metastasis. Paradoxically, lymph node metastasis has been reported only after radio-therapy. It is more commonly observed in men and 75 % of the cases are between the ages 50 and 75 [1, 2]. The ratio of woman /man is 3/10 in the series of Van

Nostrand [7] and his colleagues respectively. In etiology, tobacco and alcohol abuse and bad mouth hygiene have been put forward as the causes [2, 6]. Besides, the effects of tobacco abuse by way of chewing or snuffing and HPV on the oral cavity is emphasized. There was not tobacco and alcohol abuse in our case. It is not easy to hold alcohol and tobacco abuse and especially bad mouth hygiene, which are blamed in the cases of oral cavity and larynx, as responsible in our case since the tumor was located on the external ear tract. However, presence of warts on hands brings into mind the etiologic role of HPV infection just as in oral cavity [10]. In terms of clinical behavior, verrucous carcinomas in oral cavity destruct bone edges without invading bone marrow emptiness [2]. Those localized on the larynx cause the necrosis of the thyroid cartilage.

Ferlito and Pecher [12] compiled all published cases treated with RT at the beginning and showed that recurrence is 77.1 %. Therefore, surgery is the most resorted treatment method. In the recent years, there have been treatment reports with the methods like suction, diathermy, cryosurgery and laser surgery [13]. In our cases, the tumor mass was extracted from the external ear tract posterior through "sleeve" resection method and there was no recurrence in the follow-up period.

Consequently, verrucous carcinoma of the external ear tract histopathologic examination is very important for the diagnosis and planning of therapy options. Our suggestion because of the verrucous carcinoma of the external ear tract is see extremely rare and histopathologic diagnosis difficulty clinician and pathologist must be appreciation patients together. For this reason; wherever is invaded by the tumor, through the cooperation of the pathologist and the clinician, the extraction of the tumor all at once and as largely as possible will prevent further recurrences and metastasis and this will be the securest way to struggle with the tumor.

References

1. Ackerman LV. Verrucous carcinoma of the oral cavity. *Surgery* 1948; 23: 670-7.
2. Kraus FT, Perez-Mesa.C: Verrucous carcinoma. Clinical and pathologic study of 105 cases involving oral cavity, larynx and genitalia. *Cancer* 1966; 19: 26-38.
3. Minielly JA, Harrison EG, Fontana RS, Payne WE. Verrucous squamous cell carcinoma of the oesophagus. *Cancer* 1967; 20: 2078- 87.
4. Proops DW, Hawke WM, van Nostrand AWP, Harwood AR, Lunan M. Verrucous carcinoma of the ear. *Ann Otol Rhinol Laryngol* 1984; 93: 385-8.
5. Orsini MA, Conner GH, Sharkey FE. Verrucous carcinoma of the middle ear. *Trans Pa Acad Ophthalmol Otolaryngol* 1981; 34: 36-8.
6. Robin, JL. Verrucous carcinoma of the larynx. *Otolaryngol Head Neck Surg* 1988; 98:593.
7. Van Nostrand AWP, Olofsson J. Verrucous carcinoma of the larynx. A clinical and pathologic study of 10 cases. *Cancer* 1966; 30: 691-702.
8. Batsakis JG: Tumours of the Head and Neck, 2nd ed. Williams & Wilkins, Baltimore 1981; 205.
9. Stafford ND, Frootko NJ. Verrucous carcinoma in the external auditory canal. *Am J Otol* 1986; 7: 443-5.
10. Regezi AJ, Sciubba J. Oral Pathology. Clinical-Pathologic Correlations. WB. Saunders Co. A Division of Harcourt Brace&Co. Philadelphia-London-Toronto-Montreal-Sydney-Tokyo, 2nd ed., 1993; 187.
11. Almaç A, Göze ÖF, Yüksel A, Şengül E, Eğılmez R. Larenksin verrüköz karsinomu. *Türk Onkoloji Dergisi* 1991; 6: 1197.
12. Ferlito, A. Diagnosis and treatment of verrucous squamous cell carcinoma of the larynx. A critical review. *Ann Otol Rhinol Laryngol* 1985; 94: 575.
13. Maw AR, Culler RJ, Slinger RP, Wysocki.GP. Verrucous carcinoma of the larynx. *Clin Otolaryngol* 1982; 7: 305-11.