

Torsion of a benign ovarian cyst in the third trimester of pregnancy: a case report

Gebeliğin son üç ayında benign ovaryan kist torsiyonu: olgu sunumu

Ahmet Cantuğ Çalışkan, Hakan Aytan, Fazlı Demirtürk

Department of Obstetrics and Gynecology (Assist. Prof. A.C. Çalışkan, MD; Assist. Prof. H. Aytan, MD; Assoc. Prof. F. Demirtürk), Gaziosmanpaşa University School of Medicine, TR-60100 Tokat

Abstract

Adnexal torsion in advanced pregnancy is an uncommon emergency. It is uncommon for a normal-sized ovary to undergo torsion in advanced gestation. Presenting symptoms include severe abdominal pain, followed rapidly by maternal shock and fetal distress. A 34 years-old woman at 34 weeks gestation (gravida 5, para 4) was admitted with abdominal pain, vaginal bleeding, fever, and vomiting. On examination, in the right lower abdomen, an amorphous, predominantly hyperechogenic mass was found. Laparotomy revealed, however, that the right ovary was gangrenous and had undergone torsion. Adnexal torsion should be kept in mind in the differential diagnosis of lower abdominal pain in advanced gestation. An early diagnosis using Doppler ultrasonography of the adnexa will enable early intervention to prevent maternal shock and fetal distress.

Keywords: Torsion, ovarian cyst, pregnancy

Özet

İleri gebelikte adneksal torsiyon nadir bir acil durumdur. Büyük gebeliklerde normal bir overind torsiyona uğraması zordur. Olgu şiddetli karın ağrısı ve bunu izleyen hızlı maternal şok ve fetal distress ile başvurdu. Anne, 34 yaşında, gravida 5 parite 4, karın ağrısı, vajinal kanama, ateş ve kusma ile Kabul edildi. Muayenede sağ alt kadranda düzensiz şekilli, daha çok hiperekojenik olan bir kitle bulundu. Laparatomide sağ overin torsiyona uğramış ve gangranöz olduğu saptandı. İleri gebelikte alt karın ağrılarının ayırıcı tanısında adneksal torsiyon da düşünülmelidir. Adnekslerin Doppler ultrasonografisi erken tanıda yardımcı olarak maternal şok ve fetal distressi önleyebilir.

Anahtar sözcükler: Torsiyon , over kisti, gebelik

Geliş tarihi/Received: March 13, 2009; **Kabul tarihi/Accepted:** June 13, 2009

Corresponding author:

Dr. Ahmet Cantuğ Çalışkan, Kadın Hastalıkları ve Doğum Anabilim Dalı, Gaziosmanpaşa Üniversitesi Tıp Fakültesi, TR-60100 Tokat. Email: ahmetcantug@hotmail.com

Introduction:

Ovarian torsion is considered the fifth most common emergency in gynecology, with a prevalence rate of 2,7 [1]. It has been described as a severe complication of ovarian hyperstimulation syndrome and after ovarian stimulation for in vitro fertilization. Its incidence during pregnancy is one in 5000, occurring mostly in early pregnancy [2]. It is unusual during the third trimester [2]. The diagnostic accuracy of ultrasound in these weeks is limited because the ovaries are displayed from their normal positions [3]. By using color and power Doppler ultrasonography and transvaginal probes, the lack of perfusion of the ovary could be detected [4]. The clinical symptoms of adnexal torsion in

advanced pregnancy are non-specific and could be confused with other causes like appendicitis, cholecystitis and labor. It is generally diagnosed during surgery. We report a case of torsion of a benign ovarian cyst during the third trimester of pregnancy.

Case

A 34-year-old women at 34-weeks gestation (gravida 5, para 4) was admitted with a history of acute abdominal pain, vaginal bleeding, fever and vomiting. No recent illness or urinary complaints were reported, and her vital signs were stable. Physical examination showed that her consciousness was clear and she was coherent but irritable with a pulse rate of 120/min, blood pressure of 90/50 mmHg. The uterus was enlarged and cervix was dilated 3-4 cm with 50-60% effacement. Laboratory results showed a slightly elevated white blood cell count of 14700/mm³. Hemoglobin, hematocrit, platelet count and urine analysis were normal.

Transabdominal ultrasonography visualized a fetus in utero with a gestational age of 34 weeks. In the right lower abdomen, an amorphous, predominantly hyperechogenic mass of 8x4x4 cm was found. The left ovary had a normal size and appearance. In the right ovary within the mass, flow signals were decreased in color Doppler ultrasonography, whereas the left ovary showed a normal flow pattern (Figure 1)

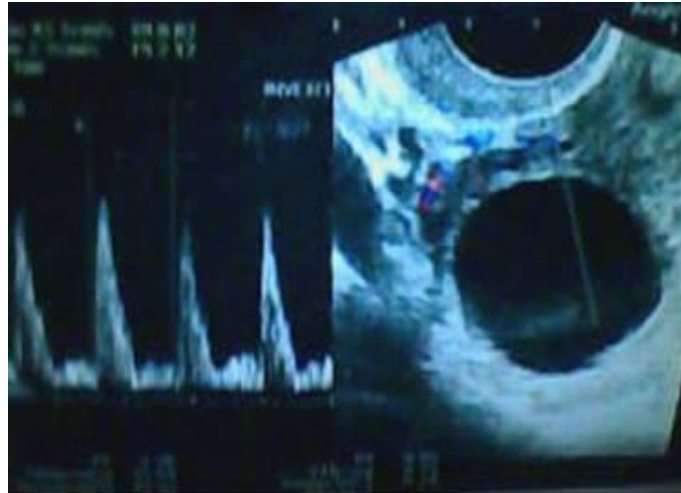

Figure 1. In the right ovary within the mass, flow signals were decreased in color Doppler sonography

Laparotomy was performed immediately for acute abdominal pain with third trimester preterm labor. At laparotomy, a lower segment cesarean section was performed and a healthy male baby weighting 2550 gr was delivered. The appendix was normal in appearance. The right ovary was gangrenous and had undergone torsion two times on his pedicle, and a salpingo-ooforectomy was performed.(Figure 2)

In order to patient and relatives desire the left salpingectomy was also performed. Microscopically there was a benign ovarian cystic lesion including multiple hemorrhagic, degenerated, and congestive areas. (Figure 3)

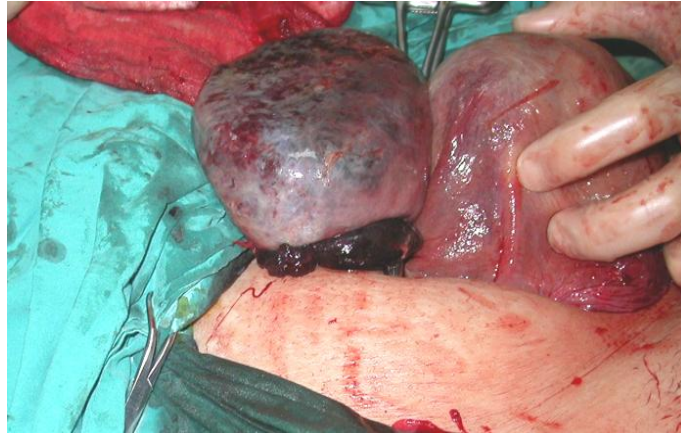


Figure 2:Gangrenous right ovary as a result of torsion of the benign cyst formation.

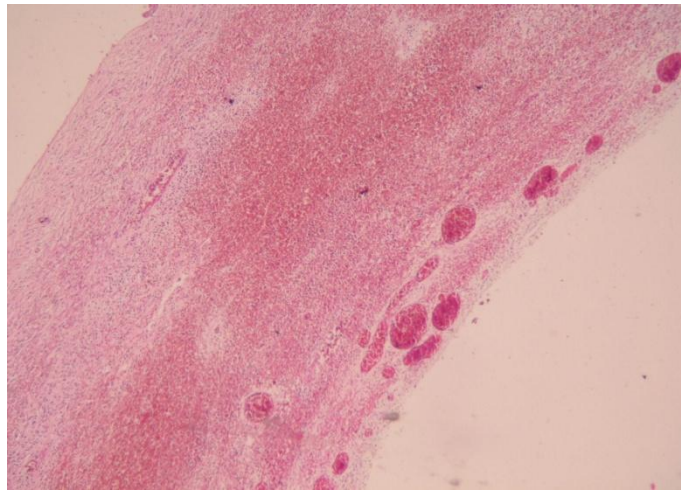


Figure 3:Hemorrhagic and edematous imaging of the full thickness cyst wall because of the strangulation (HE x 20)

Discussion:

The incidence of adnexal torsion is 1 in 5000 during pregnancy, occurring more frequently in the first trimester after IVF and ovarian stimulation as treatment for infertility [2]. It is rare in the second trimester of pregnancy and exceptional in the third trimester. The preoperative diagnosis is difficult, especially in pregnant women [3]. When a tumor is palpable within the pelvis, it must be differentiated from a retroverted uterus, a pedunculated leiomyoma, carcinoma of the colon, a pelvic kidney, a retroperitoneal mass and congenital accessory uterine horn. Mucinous or serous cystadenomas are the most common of the adnexal masses removed during pregnancy.

It results in circulatory stasis that is initially venous, but it becomes arterial as the torsion and the resultant edema progress. Therefore, the clinical presentation is variable, ranging from non-specific symptoms that include nausea, vomiting and lower abdominal pain to circulatory collapse [5]. The torsion can be complete, leading to hemorrhagic necrosis and loss of ovary [6]. When diagnosis is made early and the adnexa is hemorrhagic, simple detorsion is possible with good functional health [7].

The sonographic detection rate of adnexal masses during pregnancy is approximately 1% [8]. Although the mass had been followed sonographically, the growing uterus made detection of the persisting mass impossible. Ultrasound findings, including solid, cystic and complex pelvic tumors with or without fluid collections in the pouch of Douglas, are nonspecific. In nonpregnant women, color Doppler sonography performed with a

transvaginal probe is expected to enable early diagnosis of ovarian torsion with depiction of enlarged ovaries without perfusion of the parenchyma [9].

Torsion is seen two or three times more frequently in the right fallopian tube than in the left that is consistent with our case. This is thought to be due to the prevention of torsion by the sigmoid colon on the left side or to slow venous flow on the right side, which may result in congestion [10].

The color Doppler is the imaging method usually chosen for the assessment of patients with suspected ovarian torsion. The main finding is the enlarged volume of the ovary with central heterogeneous stroma and multiple small follicles along its periphery measuring less than 5.0 mm on average [11]. It can provide important information about ovarian flow and vascularization, and it is very important to establish ovarian viability in case of torsion before surgery. However, a decreased blood flow should not rule out the suspicion of adnexal torsion.

Since the rupture of the twisted ovarian cyst leads to massive internal bleeding, intrauterine fetal death may be caused by acute hemodynamic changes in the mother in shock. Rapid diagnosis of this rare complication is essential because these patients are often first seen in the emergency service. Aggressive fluid and blood replacement together with prompt surgical intervention provide the only chance for a favorable outcome for both mother and child. Even with these interventions, fetal mortality remains high at 31% [12].

In conclusion, both pregnancy and ovarian enlargement predispose to ovarian torsion. Therefore, this diagnosis should be considered in a pregnant patient with acute pelvic pain. The color and power Doppler are appropriate for the assessment of vascularization of small vessels. Our patient underwent definitive surgical treatment with delivery within hours of the initial presentation.

References:

1. Hibbart LT. Adnexal torsion. *Am J Obstet Gynecol* 1985;152:456-461.
2. Mancuso A, Broccio G, Angio LG: Adnexal torsion in pregnancy. *Acta Obstet Gynecol Scand* 1997;76:83-84.
3. Hohl MK. *Adnek-tumore in der Schwangerschaft*. Basel: Verlag S. Karger, 2002.
4. Teper R, Lemer-Geva J, Zalel Y. Adnexal torsion: the contribution of color Doppler sonography to diagnosis and post-operative follow-up. 1995.
5. Meyer JS, Harmon CM, Harty MP, Markowitz RJ, Hubbart AM, Bellak RD. Ovarian torsion: Clinical and imaging presentation in children. *J Pediatr Surg* 1995;30:1433-1436.
6. Rha SE, Byun JY, Jung SE. CT and MR imaging features of adnexal torsion. *Radiographics* 2002;22:283-294.
7. Massiah S, Bider D, Moran O: Adnexal torsion of hyperstimulated ovaries in pregnancies after gonadotropin therapy. *Fertil Steril* 1990;53:76-80.
8. Nelson MJ, Cavalieri R, Graham D. Cysts in pregnancy discovered by sonography. *J Clin Ultrasound* 1986;14:509-12.
9. Dawis LG, Gersovich EO, Anderson MW, Stading R. Ultrasound and Doppler in the diagnosis of ovarian torsion. *Eur J Radiol* 1995;20:133-136.
10. Vierhout ME, Wallenburg HC. Torsion of the fallopian tube: a case report of a bilateral non-simultaneous torsion and a review of the literature. *Eur J Obstet Gynecol Reprod Biol* 1986;23:111-5.
11. Graif M, Shalev J, Strauss S, Engelberg S, Mashiach S, Itzhak Y. Torsion of the ovary: Sonographic features. *AJR Am J Roentgenol* 1984;143:1331-1334.
12. Hodgkin SCP, Christiansen RS. Hemorrhage from ruptured utero-ovarian veins during pregnancy. *Am J Obstet Gynecol* 1950;59:1112-6.