

# Multiple and large nabothian cysts: a case report

## *Çok sayıda ve büyük nabothian kist: olgu sunumu*

Çağlar Yıldız, Asker Zeki Özsoy, Selda Bahçe, Dinçer Sümer, Ali Çetin

Department of Obstetrics and Gynecology (Ç. Yıldız, MD; A. Z. Özsoy, MD; S. Bahçe, MD; D. Sümer, MD; Prof. A. Çetin, MD) Cumhuriyet University School of Medicine, TR-58140 Sivas

### Abstract

Nabothian cysts are common gynecologic findings and rarely of clinical significance. The squamous epithelium of the uterine cervix proliferates and covers the columnar epithelium of the endocervical glands and the columnar cells continue to secrete mucoid material. This is an important factor for the development of nabothian cysts. Transvaginal ultrasonography and magnetic resonance imaging are the most useful imaging modalities for cervical cystic lesions. Generally, nabothian cysts do not require any therapy. If the lesion character is not clear and if the patient relief from pain a surgical intervention is needed. Here we report a case with chronic pelvic pain needed surgical intervention because of multiple nabothian cysts.

**Keywords:** Nabothian cyst, cervix, pelvic pain

### Özet

Naboth kistleri sık görülen jinekolojik patolojilerdir ve nadiren klinik önem taşırlar. Uterin serviksın skuamöz epiteli proliferasyon olur ve endoservikal glandların kolumnar epitelinı kaplar, kolumnar epitel mukoid material sekresyonuna devam eder; bu durum, naboth kistlerin gelişmesi için önemli bir faktördür. Transvajinal ultrasonografi ve manyetik rezonans görüntüleme servikal kistik lezyonlar için en kullanışlı görüntüleme yöntemleridir. Genel olarak naboth kistleri herhangi bir tedavi gerektirmezler. Eğer lezyonun yapısı belli değilse ve hasta ağrı nedeniyle acı çekiyorsa cerrahi bir müdahale gerekir. Burada kronik pelvik ağrısı olan ve cerrahi müdahale gerektiren çok sayıda naboth kisti olan bir olguyu sunuyoruz.

**Anahtar sözcükler:** Naboth kisti, serviks, pelvik ağrı

**Geliş tarihi/Received:** June 05, 2009; **Kabul tarihi/Accepted:** November 17, 2009

### Corresponding author:

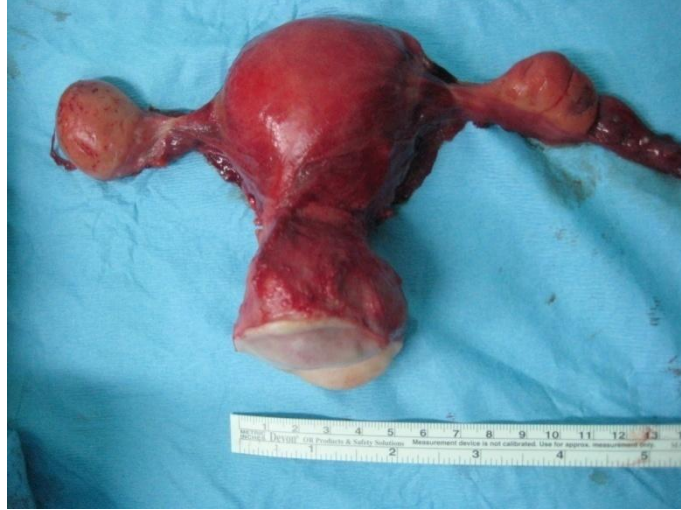Dr. Çağlar Yıldız, Kadın Hastalıkları ve Doğum Anabilim Dalı, Cumhuriyet Üniversitesi Tıp Fakültesi, TR-58140 Sivas, Email: dr\_caglaryildiz@yahoo.com

### Introduction

Nabothian cysts are common gynecologic findings and rarely of clinical significance. Nabothian cysts are formed when a gland of cervix which is fitted by the columnar epithelium covered with squamous cells and the columnar cells continue to secrete mucoid material. They can be solitary or multiple and their size shows considerable variations.[1] The sizes of the cysts vary from microscopic to several centimeters. Nabothian cysts may occur by the inflammation and reparative processes of chronic cervicitis, following minor trauma or childbirth.[2, 3] Submucosal layer of the cervix is the most common location of these cysts, rarely they are seen deeply into the cervical wall. Anechoic cystic structures are the ultrasonographic appearances of these cysts. Here we report a case with multiple large nabothian cysts which causes chronic pelvic pain.

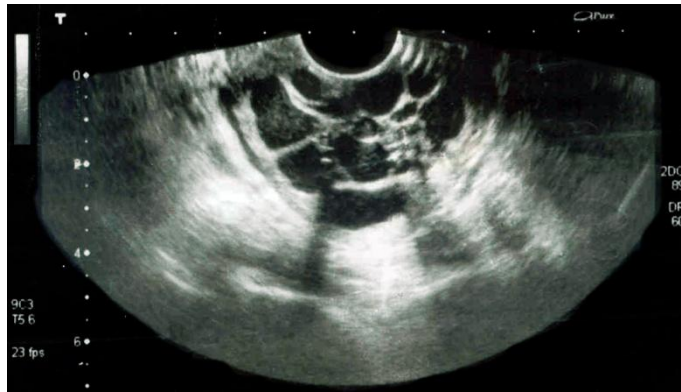
## Case report

A 49-year-old woman, G 17, P 3, A 3, DyC 10 and a previous ectopic pregnancy was admitted to our clinic with a chronic pelvic pain, fullness feeling in the vagina and irregular menstruation. In her past medical history, there was a left salpingectomy because of the ectopic pregnancy. General examination of the patient showed no abnormalities. The speculum examination revealed a multiparous enlarged cervix with an appearance of chronic cervicitis and mucoid discharge (Figure 1).



**Figure 1. Macroscopic appearance of enlarged cervix.**

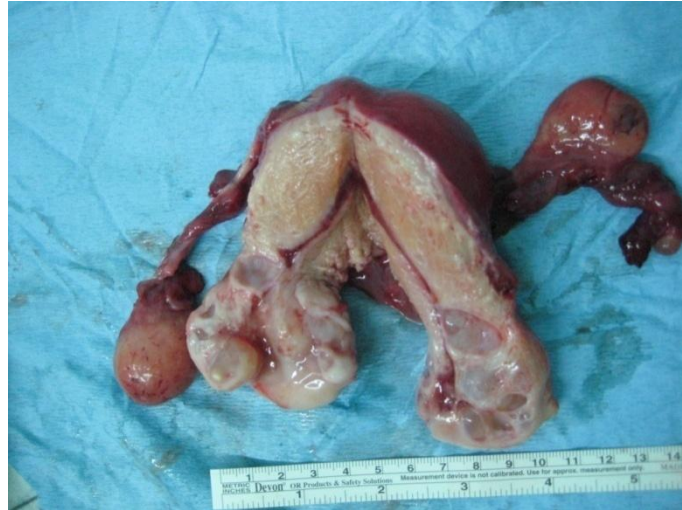Transvaginal ultrasonography showed an uterus with 85x40x50 mm in size, normal ovaries and the endometrial thickness was 6 mm, the cervix enlarged to 4 cm and multiple cystic lesions seen varied 2 mm to 20 mm size (Figure 2).



**Figure 2. Ultrasonographic image of multiple large Nabothian cysts.**

Pap smear test was performed and no pathology was detected. There were no abnormality in the laboratory tests including urinary system ultrasonography and intravenous pyelography.

Total abdominal hysterectomy and bilateral salpingo-oophorectomy was performed with no intraoperative complication. The patient was discharged on the 2th day of operation. Pathologic examination of the uterus revealed chronic cervicitis with multiple nabothian cysts (Figure 3).



**Figure 3. Macroscopic examination of uterus with multiple large Nabothian cysts.**

### Discussion

Nabothian cysts are the retention cysts in the uterine cervix. Nabothian cysts are common, nonneoplastic gynecologic disorder and rarely of clinical significance. Tunnel clusters and endocervical glandular hyperplasia are distinguished by histological diagnosis. Deep nabothian cysts are uncommon nonneoplastic lesions of the cervix. Adenoma malignum (minimal deviation adenocarcinoma of mucinous type) or other glandular malignant cervical lesions can mimic nabothian cysts, but the latter are usually located deeper in the cervix [4, 5]. Large, multiple, and deeply-localized nabothian cysts are difficult to distinguish from minimal-deviation adenocarcinoma. A solid component surrounding or separating multiple cysts is considered a clue in distinguishing adenoma malignum from benign lesions such as nabothian cysts, exact differentiation is occasionally difficult [6-9].

The squamocolumnar junction of the cervix is not a static tissue; the squamous epithelium of the uterine cervix proliferates and covers the columnar epithelium of the endocervical glands. Nabothian cysts formed when a cleft of columnar epithelium becomes covered with squamous cells and the columnar cells continue to secrete mucoid material [10].

Transvaginal ultrasonography and magnetic resonance imaging (MRI) are the most useful imaging modalities for cervical cystic lesions. Transvaginal sonography also affords a mean to evaluate several types of cervical masses and disorders. For this application, the transvaginal probe is usually placed a few centimeter into the vagina so that the cervix itself can be delineated [11]. The cysts vary from microscopic to several centimeters in size; the larger ones project above the surface of the portio. The MRI that is characteristic of Nabothian cysts is a high T2 signal intensity. T1 signal characteristics depend on the protein content [12-14]. Transvaginal power Doppler ultrasonography can reveal richness of small vessels, whose arterial flow has higher velocity in the diastolic phase, around the cystic lesion of the uterine cervix [15]. Intracervical sonography may also be able to display dysplastic lesions and carcinomas as hypoechoic defects with surrounding echogenic areas of glandular cervical mucosa [16].

Generally, nabothian cysts do not require any therapy. If the lesion character is not clear and malignancy cannot be ruled out and if the patient relief from pain or a bothersome feeling of fullness in the vagina, a surgical intervention is needed. Ablation of the cyst using electrocautery is the usual approach; however, if the diagnosis is uncertain, excision to evaluate histopathology is advised. The main disadvantage to surgical treatment is the possibility of causing scar tissue, which itself can lead to dyspareunia [17]. Despite the use of these contemporary diagnostic approaches, exploratory laparotomy and hysterectomy may still be needed in the case of unusually large and deep intracervical

cysts, when malignancy cannot be excluded [10].

## References

1. DiSaia PJ, Stafl A. Disorders of the uterine cervix. In: Scott JR, Disaia PJ, Hammond CB, Spellacy WN, eds. *Danforth's Obstetrics and Gynecology*. 6th ed. Philadelphia (USA): JB Lippincott Co., 1990; 987-95.
2. Danforth DN, Scott JR. *Obstetrics and gynecology*. Philadelphia, Pa: Lippincott, 1986.
3. Novak ER, Woodruff JD. *Novak's gynecologic and obstetric pathology with clinical and endocrine relations*. 8th ed. Philadelphia: Saunders Co., 1979.
4. Yamashita Y, Takahashi M. Adenoma malignum: MR appearances mimicking nabothian cyst. *AJR*. 1994; 162:649-50.
5. Clement PB, Young RH. Deep Nabothian cysts of the uterine cervix. *Int J Gynecol Pathol* 1989; 8:340-8.
6. Yamashita Y, Takahashi M, Katabuchi H, Fukumatsu Y, Miyazaki K, Okamura H. Adenoma malignum: MR appearances mimicking nabothian cysts. *AJR Am J Roentgenol* 1994; 162:649-50.
7. Doi T, Yamashita Y, Yasunaga T, et al. Adenoma malignum: MR imaging and pathologic study. *Radiology* 1997; 204:39-42.
8. Mikami Y, Hata S, Fujiwara K, Imajo Y, Kohno I, Manabe T. Florid endocervical glandular hyperplasia with intestinal and pyloric gland metaplasia: worrisome benign mimic of "adenoma malignum." *Gynecol Oncol* 1999; 74:504-11.
9. Yoden E, Mikami Y, Fujiwara K, Kohno I, Imajo Y. Florid endocervical glandular hyperplasia with pyloric gland metaplasia: a radiologic pitfall. *J Comput Assist Tomogr* 2001; 25: 94-7.
10. Sosnovski V, Barenboim R, Cohen HI, Bornstein J. Complex Nabothian cysts: a diagnostic dilemma. *Arch Gynecol Obstet* 2009; 279: 759-61.
11. Fleischer AC, Entmann SS. Sonographic evaluation of the uterus and related disorders. In: Fleischer AC, Manning Fa, Jeanty P, Romero R, eds. *Sonography in obstetrics and gynecology*. 5th ed. London: Appleton and Lange, 1996. pp 829-50.
12. Oramoto Y, Tanara YO. MR Imaging of the uterine cervix: imaging-pathologic correlation. *Radiographics* 2003; 23:425-45.
13. Okamoto Y, Tanaka YO, Nishida H. Pelvic imaging: multicystic uterine cervical lesions. Can magnetic resonance imaging differentiate benignancy from malignancy? *Acta Radiol* 2004; 45:102-8.
14. Tsuda K, Murakami T, Kurachi H, Ogawa H, Oi H, Miyake A, Narumi Y. MR imaging of cervical carcinoma: comparison among T2-weighted, dynamic, and postcontrast T1-weighted images with histopathological correlation. *J Abdom Imaging* 1997; 22:103-7.
15. Umesaki N, Nakai Y, Honda K, Kawamura N, Kanaoka Y, Nishimura S. Power Doppler Wndings of adenoma malignum of uterine cervix. *Gynecol Obstet Invest* 1998; 45: 213-16.
16. Dubinsky TJ, Reed SD. Intracervical sonographic-pathologic correlation. *J Ultrasound Med* 2003; 22:61-7.
17. Donald Peter Goldstein, MD Marc R Laufer, MD. Congenital cervical anomalies and benign cervical lesions. In: *UpToDate*, 2008.