

Case report - Olgu sunumu

A giant pancreatic pseudocyst compressing stomach and duodenum : a case report

Mide ve duodenuma bası yapan dev pankreatik psödokist: Bir olgu sunumu

Hüseyin Savaş Göktürk, Kemal Aslan, Mehmet Demir, Mustafa Erbayrak, Vefa Öner, Osman Doğru

Gastroenterology Clinic (H. S. Göktürk, MD, M. Erbayrak, MD), General Surgery Clinic (K. Aslan, MD, O. Doğru, MD), Radiology Clinic (V. Öner, MD) Konya Education and Research Hospital TR 42000 Konya, Gastroenterology Clinic (M. Demir, MD) Erzurum Region Education and Research Hospital TR 25240 Erzurum.

Abstract

Different strategies for pancreatic pseudocysts drainage are available: endoscopic drainage, percutaneous drainage, or open surgery. Pancreatic pseudocysts may be treated endoscopically by internal drainage to a neighboring adherent viscus such as stomach, duodenum or jejunum. We present a case with a large pseudocyst treated surgically. We hereby reported a case which a 62-year-old male patient who has giant pancreatic pseudocyst causing of gastric and duodenal compression. Surgical cystogastrostomy drainage was successfully performed, resulting in complete resolution of the giant pancreatic pseudocyst. We suggest that surgical cystogastrostomy for giant pseudocyst of the pancreas is safe, feasible and it brings out a good outcome.

Keywords: Pancreatic pseudocysts, gastric and duodenal compression, surgical cystogastrostomy

Özet

Pankreatik psödokistlerin drenajı için farklı stratejiler vardır: endoskopik drenaj, perkütan drenaj veya açık cerrahi. Pankreatik psödokistler mide, duodenum veya jejunum gibi komşu bitişik iç organlara internal drenaj yoluyla endoskopik olarak tedavi edilebilirler. Biz cerrahi olarak tedavi edilmiş büyük bir psödokist vakasını sunuyoruz. Biz burada, mide ve duodenuma bası yapan dev pankreatik psödokisti olan 62 yaşında bir erkek hastayı sunduk. Dev pankreatik psödokistin tam rezolüsyonuna yol açan cerrahi kistogastrostomi drenajı başarıyla kullanıldı. Pankreasın dev psödokisti için güvenli, uygulanabilir ve iyi bir netice elde edildiğinden dolayı cerrahi kistogastrostomi bu hastalarda önerilebilir.

Anahtar sözcükler: Psödokist, mide ve duodenuma bası, cerrahi kistogastrostomi

Geliş tarihi/Received: March 23 2010; **Kabul tarihi/Accepted:** April 12 2010

Corresponding adress:

Dr. Mehmet Demir Gastroenteroloji Kliniği Bölge Eğitim ve Araştırma Hastanesi TR 25240 Erzurum e-mail: drmehmetdemir@yahoo.com

Introduction

Pancreatic pseudocysts are localized fluid collections rich in amylase and other pancreatic enzymes and surrounded by a wall of fibrous tissue that is not lined by epithelium [1]. The limited natural history data suggest that most pseudocysts usually resolve spontaneously and rarely produce complications. However, they can produce a wide range of clinical problems depending upon the location and extent of the fluid collection and the presence of infection. On the other hand, authors generally agree that giant pancreatic pseudocysts (> 10 cm) have a lower spontaneous resolution rate and are more difficult to treat than smaller pancreatic pseudocysts [2]. We report the a 62-year-old

male with giant pancreatic pseudocyst treated successfully with surgical cystogastrostomy.

Case report

A 62-year-old male patient was admitted to the gastroenterology clinic in the Konya Education and Research Hospital with an eight-month history of progressive epigastric pain, weight loss (20 kg in 8 months), nausea and vomiting. He had developed a severe epigastric pain approximately 10 months earlier. Ultrasonography (US) had demonstrated gallbladder sludge without gallstone and Computerized tomography (CT) scan had demonstrated findings of acute necrotizing pancreatitis. He was managed conservatively at that time and discharged after two weeks of hospitalization. He was followed-up and two months later repeat CT scan demonstrated a cystic mass of about 5x5 cm in the body of the pancreas after the complaint of epigastric pain. He did not accept any intervention and did not regularly attend follow-up visits thereafter.

The physical examination on admission showed signs of dehydration, severe distention of the abdomen with tenderness and a mass in the upper abdomen. Laboratory examinations revealed hemoglobin of 14.6 g/dL, sodium of 130 mEq/L (normal range: 135-148 mEq/L) and potassium of 2.5 mEq/L (normal range 3.5- 5.1 mEq/L). Other laboratory values including serum and urinary amylase were normal. Abdominal US showed a cystic mass of 20x17 cm on the anterior side of the pancreas. A contrast-enhanced CT of the abdomen revealed a unilocular, hypodense, cystic mass of 21x17 cm on the body and tail of the pancreas displacing and compressing the stomach and the duodenal anses and splenic vein (Figure 1).

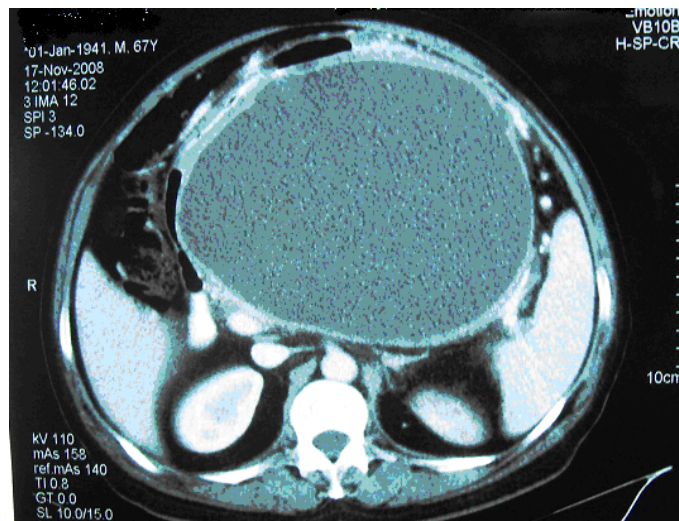


Figure 1: Abdominal computed tomography scan demonstrating giant pancreatic pseudocyst compressing the stomach and duodenum.

On upper gastrointestinal endoscopy, apparent bulging on the posterior wall of the stomach and inadequate expansion of the gastric lumen following insufflation were noted; there was no sign of portal hypertension. Once fluid and electrolyte disturbances were corrected, surgical cystogastrostomy was performed and 6500 ml of fluid content was aspirated during the procedure. After the procedure, the patient recovered well without complication and he was discharged on the 8th postoperative day. The patient was free of signs and symptoms during a three-month follow-up. Repeated CT of the abdomen obtained six weeks later revealed complete resolution of the pancreatic pseudocyst.

Discussion

Pancreatic pseudocysts account for approximately 75% of all pancreatic cystic lesions and are the most common complication of acute pancreatitis. In addition to the wide variation in the size, number and location of pancreatic pseudocysts, the clinical manifestations can also range from asymptomatic to fatal complications. Abdominal pain is the most common symptom and is present in approximately 90% of patients; early satiety, nausea, vomiting, weight loss (usually due to gastric outlet obstruction), and jaundice are the other manifestations. Physical examination may reveal abdominal tenderness, epigastric fullness or mass and signs of dehydration. Abdominal CT is the first choice for the diagnosis and provides more detailed information. Especially in the acute setting, CT is the better choice because the significant amount of bowel gas resulting from ileus or obstruction decreases the sensitivity of US. The major weakness of CT scanning is the relative inability to differentiate pancreatic pseudocyst from cystic neoplasms. EUS (endoscopic ultrasonography) is more appropriate in differentiating pseudocysts from other cystic lesions of the pancreas and can assist in transmural endoscopic drainage. During EUS, cyst fluid can be obtained for laboratory evaluation. Although magnetic resonance imaging and cholangiopancreatography are sensitive diagnostic modalities and depict choledocholithiasis far superiorly to CT or US, they are not generally used routinely because CT scanning offers all the diagnostic information required. We used CT scanning for diagnosis and found it to be sufficient. Endoscopic retrograde cholangiopancreatography (ERCP) is not necessary in diagnosis but drainage with ERCP is accomplished with a transpapillary approach when the pseudocyst communicates with the main pancreatic duct. ERCP is not performed in our hospital.

The management of pancreatic pseudocysts continues to evolve. The limited natural history data suggest that most pseudocysts usually resolve with supportive medical care. It has been shown in previous studies that acute fluid collection after pancreatitis due to non-alcoholic causes decreases from 9% to 5% after six months of follow-up; however, acute fluid collections after alcoholic pancreatitis decrease from 37% to 12%. The traditional surgical teaching of performing surgical cystenterostomy or cystgastrostomy for all pseudocysts persisting for more than six weeks or for all cysts >6 cm in size is no longer an accepted approach in the management of pancreatic pseudocysts. Although the indication and timing of the intervention in pancreatic pseudocysts related to pancreatitis are still controversial, there is an agreement that large, persistent and symptomatic cysts and cysts with complications (e.g., bleeding, infection, gastric or duodenal obstruction) should be drained [3-5].

When pseudocyst drainage was necessary in the past, surgical drainage was the only form of treatment; however, percutaneous and endoscopic methods have all been introduced to drain pancreatic pseudocysts depending on their size, number, location, presence or absence of communications with the pancreatic and bile duct, and the presence or absence of infection. For endoscopic cystgastrostomy or cystenterostomy, the cyst should be adherent to the wall of the stomach or duodenum creating an endoluminal bulge and the wall should not be more than 1 cm in thickness. The major complications of endoscopic pseudocyst drainage are development of infection, perforation and bleeding. Percutaneous catheter drainage under radiologic (CT or US) guidance is as effective as surgery in draining both sterile and infected pseudocysts but, it usually preferred for high-risk patients not suitable for operation and in the case of immature cysts with thin walls. Unsuccessful drainages are usually caused by large ductal leaks or obstruction of main pancreatic ducts; thus, percutaneous drainage should not be preferred in these patients. This technique is successful for resolving pseudocyst but carries a high risk of infection. Furthermore, the catheter tends to clog and may require repositioning and exchange. This procedure is contraindicated in patients who are poorly compliant and can not manage a catheter at home and in patients with cysts containing blood or solid material [6-8].

In conclusion, surgical drainage is also indicated in cases that malignancy cannot be ruled out, when the distance between the cyst wall and the viscus is more than 1 cm and

following failure or complications of endoscopic and percutaneous drainage. On the other hand, surgical, percutaneous and endoscopic pseudocyst drainage procedures have not been directly compared in high-quality prospective randomized studies and the majority of clinicians would still drain a cyst using the technique which they are more familiar. Pancreatic pseudocyst can cause of stomach and duodenum compression and it can be treated successfully with surgical cystgastrostomy.

References

1. O'Malley VP, Cannon JP, Postier RG. Pancreatic pseudocysts: cause, therapy, and results. *Am J Surg* 1985; 150: 680-2.
2. Cheruvu CV, Clarke MG, Prentice M, Eyre-Brook IA. Conservative treatment as an option in the management of pancreatic pseudocyst. *Ann R Coll Surg Engl* 2003; 85: 313-6.
3. Habashi S, Draganov PV. Pancreatic pseudocyst. *World J Gastroenterol* 2009; 15: 38-47.
4. Maringhini A, Uomo G, Patti R, Rabitti P, Termini A, Cavallera A, Dardanoni G, Manes G, Ciambra M, Laccetti M, Biffarella P, Pagliaro L. Pseudocysts in acute nonalcoholic pancreatitis (incidence and natural history). *Dig Dis Sci* 1999; 44: 1669-73.
5. Kourtesis G, Wilson SE, Williams RA. The clinical significance of fluid collections in acute pancreatitis. *Am Surg* 1990;56:796-9.
6. Szentes MJ, Traverso LW, Kozarek RA, Freeny PC. Invasive treatment of pancreatic fluid collections with surgical and nonsurgical methods. *Am J Surg* 1991;161:600-5.
7. Golash V, Cutress R. Laparoscopic cystogastrostomy for a giant pseudocyst of pancreas. *Surgeon*. 2005; 3: 37-41.
8. Sheng QS, Chen DZ, Lang R, Jin ZK, Han DD, Li LX, Yang YJ, Li P, Pan F, Zhang D, Qu ZW, He Q. Laparoscopic cystogastrostomy for the treatment of pancreatic pseudocysts: a case report. *World J Gastroenterol*. 2008;14:4841-3.