

*Case report - Olgu sunumu*

## **Segmental colonic tuberculosis perforation as a rare cause of intraabdominal abscess: a case report**

*İntraabdominal absenin nadir bir sebebi olarak segmental kolon tüberkülozu perforasyonu: olgu sunumu*

**Ayşe Albayrak, Belkız Aylu, Yavuz Albayrak, Fatih Albayrak, Hilmi Ataseven, Muhammed H. Uyanık**

Department of Clinical Bacteriology and Infectious Diseases (A. Albayrak, MD), Department of General Surgery (B. Aylu, MD, Y. Albayrak, MD), Department of Gastroenterology (H. Ataseven, MD), Erzurum Region Education and Research Hospital, TR-25040 Erzurum. Department of Internal Medicine (F. Albayrak, MD), Department of Microbiology and Clinical Microbiology (M. H. Uyanık, MD) Ataturk University School of Medicine, 25040 Erzurum.

### **Abstract**

Intestinal tuberculosis (TB) is a rare disease. Perforation is an extremely uncommon complication of mycobacterium tuberculosis infection. Herein, we present a rare case of perforated segmental colonic TB with an intraabdominal abscess focus. A 15-year-old female patient was admitted to our hospital with the complaints of abdominal pain, and intermittent vomiting. She had diffuse abdominal tenderness. The patient had a family history of pulmonary tuberculosis. During the laparotomy, a wedge resection of the area of the colon including the perforations was performed. Histopathological examination revealed epithelioid cell granulomas with Langhans type giant cells in the entire thickness of the wall of the colon and the paracolic lymph nodes, and evidence of caseation in the latter. Intestinal TB should also be kept in mind while investigating the causes of emergency surgery for conditions such as perforation, obstruction or bleeding of the intestines, especially in the endemic regions.

**Key words:** Segmental colonic tuberculosis, intraabdominal abscess, bowel perforation, caseation

### **Özet**

İntestinal tüberküloz (TB), nadir bir hastalıktır. İntestinal perforasyon mycobakteriyum tüberkülozisin oldukça nadir görülen bir komplikasyonudur. Bu makalede intraabdominal abses odağı olarak perforé segmental intestinal TB vakasını sunuyoruz. Karın ağrısı ve aralıklı kusma şikayeti olan 15 yaşında bayan hasta hastaneye başvurdu. Karnında yaygın hassasiyeti mevcuttu. Ailesinde akciğer TB hikayesi vardı. Hastaya yapılan laparatomide, perforé kolon segmentini içeren kama tarzı rezeksiyon yapıldı. Kolon ve parakolik lenf nodlarının histopatolojik incelenmesinde Langhans tipi dev hücrelerin bulunduğu epitelioid histiositler ve kazeifikasyon tespit edildi. Özellikle TB'nin endemik olarak gözlemlendiği bölgelerde perforasyon, obstrüksiyon veya kanama gibi acil cerrahi gereken durumlarda intestinal TB akılda tutulmalıdır.

**Anahtar sözcükler:** Segmental kolonik tüberküloz, inraabdominal apse, barsak perforasyonu, kazeifikasyon

**Geliş tarihi/Received:** April 4 2010; **Kabul tarihi/Accepted:** April 28 2010

### **Corresponding author:**

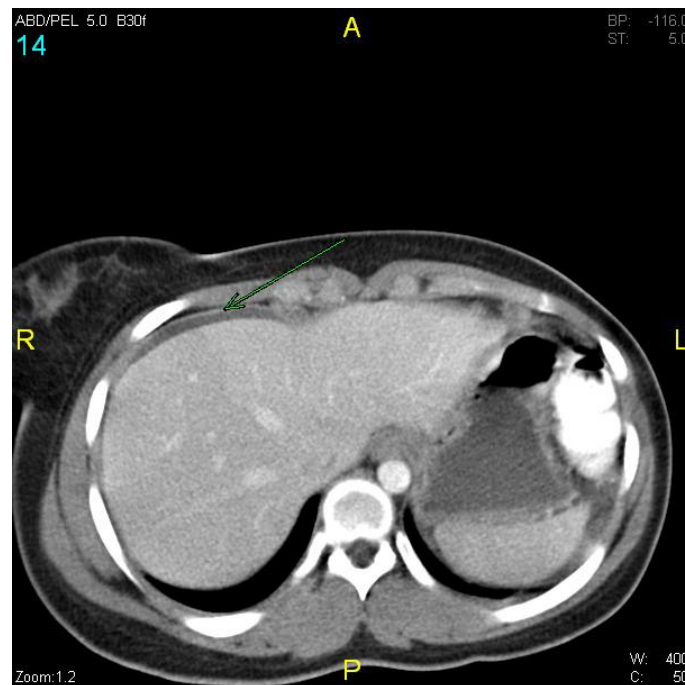
Dr.Ayşe Albayrak, Erzurum Region Education and Research Hospital, Department of Clinical Bacteriology and Infectious Diseases, TR-25040 Erzurum, E-mail: aysealbayerkerz@gmail.com

## Introduction

Intestinal tuberculosis (TB) is a rare disease. Diagnosis is often delayed due to the lack of specific symptoms and laboratory findings. As a result, effective treatment is delayed with ensuing morbidity and mortality [1, 2]. Perforation is an extremely uncommon complication of mycobacterium tuberculosis infection [3, 4]. Herein, we present a rare case of perforated segmental colonic TB with an intraabdominal abscess focus.

## Case report

A 15-year-old female patient was admitted to our hospital with a 2 day history of abdominal pain, and intermittent vomiting. She had diffuse abdominal tenderness. Her pulse was 110/minute, temperature 37.8°C, and blood pressure 130/70 mmHg. The patient had a family history of chest tuberculosis. Routine laboratory workup revealed a total leukocyte count of  $12.3 \times 10^3/l$  (88% neutrophils), hemoglobin of 11.4 g/dl, erythrocyte sedimentation rate of 84 mm/h, normal serum chemistry, and normal urine analysis. Chest radiograph was normal. An abdomen computed tomography (CT) without the application of contrast, no pathology was observed other than perihepatic fluid (Figure 1).



**Figure 1. Abdomen CT scan of the patient demonstrating a perihepatic fluid collection anterior to the liver.**

During the laparotomy, just above the incision line, fibrotic-inflammatory adhesions were seen between the peritoneum and the colon. The peritoneum was observed to be highly inflamed and weakened and a hard, 5x5 cm lesion with a necrotic core was observed between the transverse colon and the large curvature of the stomach. The transverse colon was fistulized into the necrotic tissue and there were three perforations approximately 5 mm apart in the transverse colon. Lymphadenopathy was noted in the mesentery. A wedge resection of the colon including the perforations was performed. Bridectomy was performed on the intraabdominal adhesions. Sixty mL of pus was aspirated from the mass and biopsies were taken from the peritoneum, intraabdominal lymph nodes and the peritoneum. The results of the culture of the intraabdominal abscess showed no growth but direct microscopic examination revealed acid resistant bacilli. Histopathological examination revealed epithelioid cell granulomas with Langhans type giant cells in the

entire thickness of the wall of the colon and paracolic lymph nodes, and evidence of caseation in the latter.

During the post-operative CT examination of the thorax and abdomen, budding was observed in the middle lobe of the left lung. Based on the findings, a diagnosis of intestinal TB secondary to pulmonary TB was made. Postoperatively, an anti-TB treatment for both intestinal tuberculosis and tuberculous abscess was ordered.

## Discussion

Tuberculous involvement of the colon is rare even in the presence of extensive pulmonary disease and tuberculosis of the colon comprises only 3 to 4% of intestinal tuberculosis [1, 2]. Segmental colonic tuberculosis refers to the involvement of the colon without ileocaecal region, and constitutes 9.2 per cent of all cases of abdominal tuberculosis. It commonly involves the sigmoid, ascending and the transverse colon [5]. Our case had segmental colonic TB infecting only the transverse colon. As symptoms are non-specific in intestinal TB cases, the diagnosis is difficult to make, and the mortality and morbidity of the disease are high [1, 6]. In such cases, the diagnostic procedure is surgical exploration or colonoscopy. As it is less invasive and it allows for histopathological and microbiological sampling, colonoscopy is the first choice. [7].

The management of gastro intestinal TB relies on anti-tuberculous drugs. Surgical intervention is reserved for intestinal TB complicated by perforation, obstruction, or uncontrollable haemorrhage [7]. In cases presenting with complications such as a perforation, an emergency laparotomy is performed before a diagnosis of intestinal TB is made, an evaluation of TB in other intraabdominal organs can not be carried out.

Intestinal TB should also be kept in mind while investigating the causes of emergency surgery for conditions such as perforation, obstruction or bleeding of the intestines, especially in geographical areas where TB is endemic. During the postoperative period, other intraabdominal organs should also be examined regarding the presence of infection in addition to the lungs. In the case of detection of a focus, the required treatment must be given.

## References

1. Harrigan RA, Kauffman FH, Love MB. Tuberculous psoas abscess. *J Emerg Med* 1995; 13: 493-8.
2. Cömert FB, Cömert M, Kùlah C, Taşçılar O, Numanođlu G, Aydemir S. Colonic tuberculosis mimicking tumor perforation: a case report and review of the literature. *Dig Dis Sci* 2006; 51: 1039-42.
3. Chaudhary A, Gupta NM. Colorectal tuberculosis. *Dis Colon Rectum* 1986; 29: 738-41.
4. Gupta NM, Motup T, Joshi K. Isolated colonic tuberculous perforation as a rare cause of peritonitis: report of a case. *Surg Today* 1999; 29: 273-5.
5. Sharma MP, Bhatia V. Abdominal tuberculosis. *Indian J Med Res* 2004; 120: 305-15.
6. Chakhaiyar P, Hasnain SE. Defining the mandate of tuberculosis research in a postgenomic era. *Med Princ Pract* 2004; 13: 177-84.
7. Leung VK, Law ST, Lam CW, Luk IS, Chau TN, Loke TK, Chan WH, Lam SH. Intestinal tuberculosis in a regional hospital in Hong Kong: a 10-year experience. *Hong Kong Med J* 2006; 12: 264-71.