

Case report-Olgu sunumu

Rituximab-induced serum sickness in a patient with refractory chronic immune thrombocytopenic purpura: a case report and review of the literature

Refrakter kronik immün trombositopenili bir hastada rituksimab ilişkili serum hastalığı: bir vaka raporu ve literatürün gözden geçirilmesi

Osman Yokuş, Özlem Şahin Balçık, Burak Uz*, Murat Albayrak, Abdullah Turasan

Department of Hematology (O. Yokuş, MD), Okmeydanı Teaching and Research Hospital, TR-34384 İstanbul, Department of Hematology (Ö.Ş. Balçık, MD), Fatih University School of Medicine, TR-06120 Ankara, Department of Hematology (B. Uz, MD), Hacettepe University School of Medicine, TR-06100 Ankara, Department of Hematology (M. Albayrak, MD), Dışkapı Yıldırım Beyazıt Teaching and Research Hospital, TR-06110 Ankara, Department of Dermatology (A. Turasan, MD), Kayseri Teaching and Research Hospital, TR-38010 Kayseri

Abstract

Although common side effects such as fever, chills and rigors are commonly seen during the first infusion of rituximab; delayed ones such as serum sickness and Steven-Johnson syndrome have rarely been reported. We report an adult patient with steroid resistant and splenectomized chronic immune thrombocytopenic purpura who presented with fever, arthralgia, asthma like respiratory symptoms, maculopapular rash, and palpable purpuric lesions 2 days after the third infusion of rituximab. Withdrawal of rituximab and subsequent treatment with i.v. steroid and antihistaminics improved the patient's clinical and physical findings. In such cases rituximab should be discontinued, complete and rapid resolution can be possible with systemic steroid treatment.

Keywords: Rituximab, chronic immune thrombocytopenic purpura, CD20, serum sickness, intravenous immunoglobulin

Özet

Ateş, titreme ve kasılma gibi yan etkiler ilk kez yapılan rituksimab infüzyonu sırasında sıkça görülmesine karşılık, serum hastalığı ve Steven-Johnson sendromu gibi gecikmiş yan etkiler nadir olarak bildirilmiştir. Steroide dirençli ve splenektomize kronik immün trombositopenili bir hasta, üçüncü rituksimab infüzyonundan iki gün sonra ateş, artralji, astım benzeri solunum sistemi semptomları, makülopapüler raş ve palpabl purpurik lezyonlar ile başvurdu. Rituksimabın kesilmesi, sonrasında intravenöz steroid ve antihistaminik tedavi uygulanması ile hastanın kliniği ve fiziki bulguları düzeldi. Bu gibi vakalarda rituksimabın kesilmesi ve sistemik steroid tedavi uygulanması ile tam ve hızlı bir düzelme sağlanabileceğini düşünmekteyiz.

Anahtar sözcükler: Rituksimab, kronik immün trombositopenik purpura, CD20, serum hastalığı, intravenöz immunoglobulin

Geliş tarihi/Received: July 25, 2010; **Kabul tarihi/Accepted:** January 6, 2011

***Corresponding author:**

Burak Uz, MD, Hematoloji Anabilim Dalı, Hacettepe Üniversitesi Tıp Fakültesi, TR-06100 Ankara. E-posta: burakuz@yahoo.com

Introduction

Immune Thrombocytopenic Purpura (ITP) is an acquired, autoimmune disorder which results from accelerated platelet destruction mediated by IgG autoantibodies in spleen. Usually, it shows a chronic pattern in adults. Management is predicated on the platelet

count and severity of bleeding. The use of steroids and intravenous immunoglobulin (IVIg) frequently allows the platelet count to increase but in most patients this effect is only transient after discontinuation of treatment and the chronic administration of these agents is toxic and expensive. The decision on about splenectomy is predicated on disease severity, side effects of medical therapy, and importantly on patient and physician preference [1]. However, nearly one-third of patients do not response and about 20% relapse [2]. More difficult cases of chronic ITP may require alternatives including, danazol, azathioprine, cyclophosphamide, and vinca alkaloids [3]. Anti-B cell monoclonal antibody treatment is a promising therapeutic modality in autoimmune diseases. Rituximab, a chimeric murine/human monoclonal anti-CD20 antibody, has been used as an alternative second-line therapy to splenectomy in selected patients with refractory chronic ITP because of its low toxicity rate and high response rate. The response rate of ITP to rituximab was 25-65% in adults and 31-63% in children [1].

Adverse events associated with rituximab treatment are mainly mild infusion-related reactions such as fever, nausea and headache [4]. Serum sickness which is a type III hypersensitivity reaction that results from the injection of a foreign protein, has been reported after administration of rituximab. About 6-20% of patients were reported to have developed rituximab induced serum sickness, which is more common among patients with autoimmune conditions than among those with hematologic malignancies [5]. It is possible that the polychemotherapy prescribed to patients with primary lymphoproliferative disorders prevents the development of these reactions [6].

Case report

A 48 year-old woman presented with petechiae on her upper and lower extremities and epistaxis. She was splenectomized 3 months ago with the diagnosis of steroid resistant ITP. The laboratory findings were as follows: white blood cell count: $8 \times 10^6/L$, hemoglobin: 13 g/dL, platelet count: $1 \times 10^9/L$, and erythrocyte sedimentation rate: 30 mm/h. Biochemical tests were all in normal ranges. Thrombocytopenia was confirmed with peripheral blood smear. Clinical and laboratory investigations revealed no evidence of infection or thromboembolic events.

Initially methylprednisolone 2 mg/kg/day was started. After 3 days of treatment with corticosteroid, her platelet count increased to $5 \times 10^9/L$. She then received azathioprine while continuing corticosteroid treatment. After one month, she had a poor response to corticosteroid, and azathioprine with a platelet count of $10 \times 10^9/L$. After this failed attempt, she received 2 courses of rituximab ($375 \text{ mg/m}^2/\text{week}$) infusions. The patient responded favorably to rituximab and achieved a platelet count of over $100 \times 10^9/L$ after three weeks. She received oral acetaminophen 500 mg and i.v. chlorphenamine as premedication therapy. She was scheduled to receive 4 weekly infusions of rituximab; however, 2 days after the third infusion, she experienced acute onset of fever, arthralgia, asthma like respiratory symptoms, maculopapular rash, and palpable purpuric lesions (Fig. 1a-b).

Dermatology division consulted the patient but she refused skin biopsy. She was considered to have a diagnosis of drug induced delayed skin reaction (serum disease?, leukocytoclastic vasculitis?). Methylprednisolone, an antihistaminic and H2 receptor blocker were administered. Her symptoms gradually resolved (Fig. 2a-b) in ten days and she was discharged from hospital.

Methylprednisolone was tapered and stopped on day 30. Even after discontinuation of methylprednisolone, she is in complete remission for 1 year, and her platelet count fluctuated between $400 \times 10^9/L$ and $500 \times 10^9/L$.

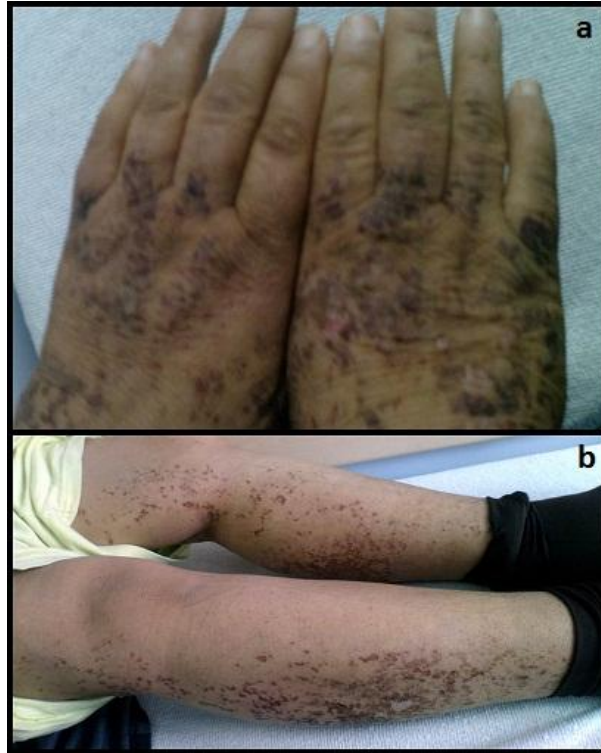

Figure 1a and b. Bilateral palpable purpuric lesions on her hands and lower extremities after the third rituximab infusion.

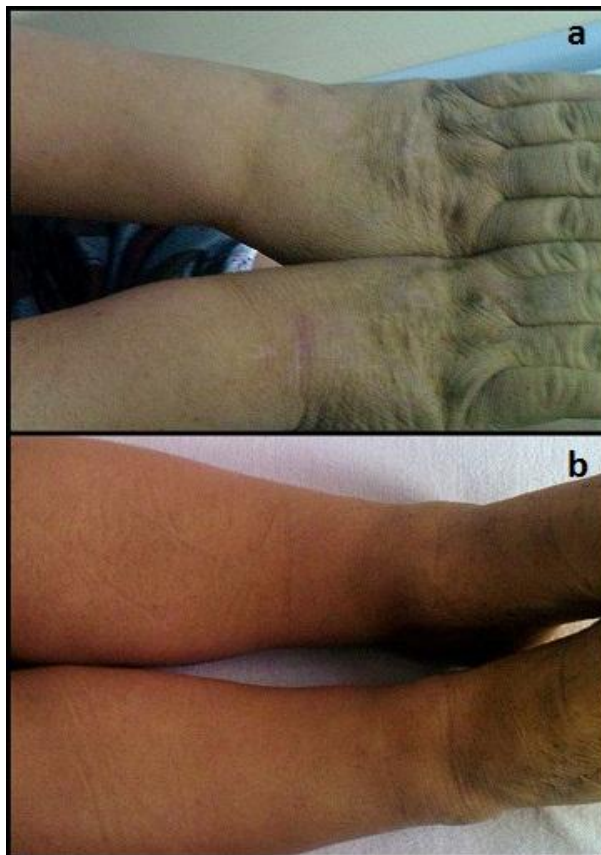


Figure 2a and b. The skin lesions resolved after the symptomatic therapy.

Discussion

Our patient with chronic ITP was refractory to splenectomy, steroid and azathioprin treatments. She was able to receive 3 courses of rituximab, because of having serum sickness 2 days after the third infusion. The diagnosis of serum sickness was based on the physical examination findings, improvement of the skin lesions and patient's complaints after withdrawal of rituximab, and response to treatment with steroid and antihistaminics. Two forms of reactions have been identified, acute and delayed, both apparently related to the presence of antibodies to the monoclonal components [7]. Acute side effects of rituximab are commonly seen during the first infusion in up to 50% of patients and include fever, chills and rigors [8, 9]. These adverse effects are generally transient, probably due to a greater degree of complement activation and proinflammatory cytokine release. On the other hand, the significant post-infusion syndromes, including Stevens-Johnson syndrome, serum sickness and vasculitis, typically occur some days after exposure [10]. The mechanisms behind these reactions are not well understood but are mostly attributed to cytokine release [11]. It is known that complement plays a pivotal role in the pathogenesis of side-effects due to rituximab treatment. The infusion of rituximab induces rapid complement activation, preceding the release of TNF- α , IL-6 and IL-8 [12]. A reduced clearance of immunocomplexes and/or an increased production of autoantibodies may activate immune response. Moreover, the underlying diseases (autoimmune diseases, chronic lymphocytic leukemia, follicular non-Hodgkin's lymphoma) may also play a role in the development of delayed or cutaneous reactions [10]. Because, side effects related to rituximab are especially low in healthy outpatients without comorbid medical conditions [13]. Finger et al. [6] reported two adult women (38 and 45-year-old) with severe hypergammaglobulinemia who were treated with rituximab infusions. Serum sickness-like symptoms were developed the day after second infusion and 7 days after the first infusion respectively. Both patients were started on corticosteroids with remission of the symptoms. According to the authors, it was possible that marked hypergammaglobulinemia may be related to delayed reactions to rituximab treatment [6]. In the study by Wang et al. [3], 3 (12.5%) of 24 pediatric (2-19 year of age) patients with chronic ITP developed serum sickness. Two of them had serum sickness after the second and third infusions, respectively, and had their subsequent treatments discontinued. However, despite receiving only 2 and 3 doses of rituximab, both of them were able to achieve complete response as seen in our patient. One patient had mild serum sickness after the first infusion who was treated with prednisone with a slow taper of the dose and tolerated the remaining infusions [3]. In a prospective study of 36 patients (18 months-18 year of age) with severe or chronic ITP, two patients, both nonresponders, had serum sickness; one, a 12 year-old male patient, presented with fever, fatigue, and rash after the second dose of rituximab, and the other, an 11-year-old female patient, developed fever, joint pain and swelling, conjunctival hyperemia, and cutaneous rash after the second rituximab dose. Rituximab was discontinued in these 2 patients [8]. A 8-year old boy with steroid dependent chronic ITP was diagnosed as having rituximab-induced serum sickness ten days after the second infusion of rituximab. He was treated with oral prednisolone successfully. Interestingly, the human anti-chimeric antibody (HACA) levels were high on day 27 after the second infusion of rituximab, while rituximab was undetected during this period [5]. However the diagnostic value of elevated HACA for serum sickness is under discussion [14]. These reports bring the total reported incidence of serum sickness in pediatric subjects with chronic ITP treated with rituximab to be 9,8% (6 out of 61) (Table 1).

Recently a long-term (at least 36 weeks) study with rituximab in 26 adult (18-76 year of age) patients with relapsed or refractory ITP have been reported. Only one patient soon after the second administration experienced a grade 3 serum sickness syndrome. After discontinuation of rituximab and a brief course of steroid treatment, all signs and symptoms were disappeared (Table 1). Younger age and a shorter interval between diagnosis and rituximab therapy appeared indicators of better outcome in this study [15].

Serum sickness associated with hepatitis C virus-related mixed cryoglobulinaemia in a 60-year-old woman was reported 7 days after the first course of rituximab treatment. It is completely remitted after administration of betamethasone and H1-blockers [16]. Occasional skin eruptions and erythema have been reported, with severe mucocutaneous toxicity such as Stevens-Johnson syndrome in one case [17]. Serum sickness related to rituximab was usually reported after second course of treatment (Table 1). Wang et al. reported only one case that occurred after third dose as seen in our patient (Table 1) [3]. Despite this, she achieved a partial response (platelet count $>100 \times 10^9/L$) and a complete response (platelet count $>150 \times 10^9/L$), after 3 weeks and 4 weeks, respectively, from the initial rituximab infusion. The skin lesions and other manifestations of serum sickness were treated by i.v. steroid and antihistaminics successfully. We believe that serum sickness observed in our patient could be explained at least partially with a delayed hypersensitivity reaction caused by an unknown antigen. However, we were not able to detect HACA levels or perform a skin biopsy throughout the treatment for a more accurate diagnosis.

Table 1. Reported rituximab-related serum sickness in pediatric and adult patients with chronic ITP

Publication(ref)	Age(min-max)/median	n	n*	infusion	treatment
Goto et al. [5]	8	1	1	Second	wd and steroid
Medeot et al. [15]	(18-76)/55	26	1	Second	wd and steroid
Bennett et al. [8]	(2.6-18.3)/11.2	36	2	Second/Second	wd/wd
Wang et al. [3]	(2-19)/12.3	24	3	First/Second/Third	wd/wd/steroid

Abbreviations: ref, reference number; n, number of patients; n*, number of patients with serum sickness; wd, withdrawal of rituximab infusion

Although toxicity is usually mild and reversible, clinicians should be aware of serum sickness as a serious adverse effect of rituximab with its increasing therapeutic use. Because patients, prior to the treatment with rituximab, usually receive antihistaminic therapy, the true frequency of these side-effects may be underestimated. Administering steroid during and after exposure to rituximab may prevent this delayed immune reaction for the patients, especially those with an autoimmune disease. With the expansion in the therapeutic use of monoclonal antibodies in a widening spectrum of disorders, it is advisable to take into consideration not only immediate reactions but also delayed ones.

References

1. Bussel J, Cines DB. Immune thrombocytopenic purpura, neonatal alloimmune thrombocytopenia, and posttransfusion purpura. In: Hoffman R, Benz Jr EJ, Shattil S, Furie B, Silberstein LE, McGlave P, Heslop H, Anastazi J (Eds). *Hematology Basic Principles and Practice*. 5th ed. Churchill Livingstone, Elsevier 2009; pp 2083-97.
2. Vianelli N, Galli M, de Vivo A, Intermesoli T, Giannini B, Mazzucconi MG, Barbui T, Tura S, Baccaranion M; Gruppo Italiano per lo Studio delle Malattie Ematologiche dell'Adulto. Efficacy and safety of splenectomy in immune thrombocytopenic purpura: longterm results of 402 cases. *Haematologica* 2005; 90: 72-7.
3. Wang J, Wiley JM, Luddy R, Greenberg J, Feuerstein MA, Bussel JB. Chronic immune thrombocytopenic purpura in children: assessment of rituximab treatment. *J Pediatr* 2005; 146: 217-21.
4. Winkler U, Jensen M, Manzke O, Schulz H, Diehl V, Engert A. Cytokine-release syndrome in patients with B-cell chronic lymphocytic leukemia and high lymphocyte counts after treatment with an anti-CD20 monoclonal antibody (rituximab, IDEC-C2B8). *Blood* 1999; 94: 2217-24.
5. Goto S, Goto H, Tanoshima R, Kato H, Takahashi H, Sekiguchi O, Kai S. Serum

- sickness with an elevated level of human anti-chimeric antibody following treatment with rituximab in a child with chronic immune thrombocytopenic purpura. *Int J Hematol* 2009; 89: 305-9.
6. Finger E, Scheinberg M. Development of serum sickness-like symptoms after rituximab infusion in two patients with severe hypergammaglobulinemia. *J Clin Rheumatol* 2007; 13: 94-5.
 7. Cheifetz A, Mayer L. Monoclonal antibodies, immunogenicity, and associated infusion reactions. *Mt Sinai J Med* 2005; 72: 250-6.
 8. Bennett CM, Rogers ZR, Kinnamon DD, Bussel JB, Mahoney DH, Abshire TC, Sawaf H, Moore TB, Loh ML, Glader BE, McCarthy MC, Mueller BU, Olson TA, Lorenzana AN, Mentzer WC, Buchanan GR, Feldman HA, Neufeld EJ. Prospective phase 1/2 study of rituximab in childhood and adolescent chronic immune thrombocytopenic purpura. *Blood* 2006; 107: 2639-42.
 9. Tonelli AR, Lottenberg R, Allan RW, Sriram PS. Rituximab-induced hypersensitivity pneumonitis. *Respiration* 2009; 78: 225-9.
 10. Hellerstedt B, Ahmed A. Delayed-type hypersensitivity reaction or serum sickness after rituximab treatment. *Ann Oncol* 2003; 14: 1792.
 11. Doan T, Massarotti E. Rituximab. *Drugs Today* 2005; 41: 785-97.
 12. van der Kolk LE, Grillo-Lopez AJ, Baars JW, Hack CE, van Oers MH. Complement activation plays a key role in the side-effects of rituximab treatment. *Br J Haematol* 2001; 115: 807-11.
 13. Davis TA, Grillo-López AJ, White CA, McLaughlin P, Czuczman MS, Link BK, Maloney DG, Weaver RL, Rosenberg J, Levy R. Rituximab anti-CD 20 monoclonal antibody therapy in non-Hodgkin's lymphoma: safety and efficacy of re-treatment. *J Clin Oncol* 2000; 18: 3135-43.
 14. Todd DJ, Helfgott SM. Serum sickness following treatment with rituximab. *J Rheumatol* 2007; 34: 430-3.
 15. Medeot M, Zaja F, Vianelli N, Battista M, Bacarani M, Patriarca F, Soldano F, Isola M, De Luca S, Fanin R. Rituximab therapy in adult patients with relapsed or refractory immune thrombocytopenic purpura: long-term follow-up results. *Eur J Haematol* 2008; 81: 165-9.
 16. Catuogno M, Rezai S, Priori R, Magrini L, Valesini G. Serum sickness associated with rituximab in a patient with hepatitis C virus-related mixed cryoglobulinaemia. *Rheumatology (Oxford)* 2005; 44: 406.
 17. Lowndes S, Darby A, Mead G, Lister A. Steven-Johnson syndrome after treatment with rituximab. *Ann Oncol* 2002; 13: 1948-50.