

*Case report-Olgu sunumu*

## Epidermoid tumor of the cerebellum in Behçet's disease

*Behçet hastalığında serebellar epidermoid tümör*

**Soner Yaycıoğlu, Hakan Ak\***

Department of Neurosurgery (Assist. Prof. S. Yaycıoğlu, MD., H. Ak, MD.), Adnan Menderes University School of Medicine, TR-09100 Aydın

**Abstract**

Behçet's disease a multisystem chronic idiopathic inflammatory and recurrent disease characterized by uveitis, oral aphthae, genital ulcers, and skin lesions. About 5-10 % of these patients show central nervous system involvement named as neuro-Behçet's disease. This involvement can be divided into two main categories; parenchymal and non-parenchymal. The most common involved sites are the brain stem and basal ganglia. In the literature, several case reports have reported neuro-Behçet's disease mimicking the brain tumor or tumors. In this report, we are presenting a 47 year old man suffering from Behçet's disease for 20 years and having an epidermoid tumor in cerebellum. Although the presence of epidermoid tumor in this patient was accepted as a coincidental finding in the light of the current literature; further studies are needed for the confirmation.

**Keywords:** Behçet's disease, neuro-Behçet's disease, magnetic resonance imaging, epidermoid tumor.

**Özet**

Behçet hastalığı üveit, ağızda aftlar, genital ülserler ve deri lezyonları ile karakterize olan çok sayıda sistemi etkileyebilen kronik idiyopatik, enflamatuar ve alevlenmelerle seyreden bir hastalıktır. Behçet hastalarının yaklaşık %5-10'unda merkezi sinir sistemi tutulumu görülmektedir ve bu tablo nöroBehçet hastalığı olarak adlandırılmaktadır. Bu tutulum parenkimal ve parankim-dışı olarak iki kategoriye ayrılmaktadır. En sık etkilenme beyin sapı ve bazal gangliyonlarda görülmektedir. Literatürde, beyin tümörü veya tümörlerini taklit eden nörobeçet vakaları bildirilmektedir. Bu yazıda serebellumda epidermoid tümör saptanan 47 yaşında ve 20 yıldır Behçet hastası olan bir erkek olgu sunulacaktır. Bu hastadaki epidermoid tümörün varlığı mevcut literatüre göre tesadüfi bir bulgu olarak kabul edilmesine rağmen bunun kesinliğinin hâlen doğrulanmaya ihtiyaç duyduğu kanısındayız.

**Anahtar sözcükler:** Behçet hastalığı, nöroBehçet hastalığı, manyetik rezonans görüntüleme, epidermoid tümör

**Geliş tarihi/Received:** November 18, 2010; **Kabul tarihi/Accepted:** March 24, 2011

**\*Corresponding author:**

Hakan Ak, MD., Nöroşirürji Anabilim Dalı, Adnan Menderes Üniversitesi Tıp Fakültesi, TR-09100 Aydın. E-mail: nsrsdrhakanak@yahoo.com

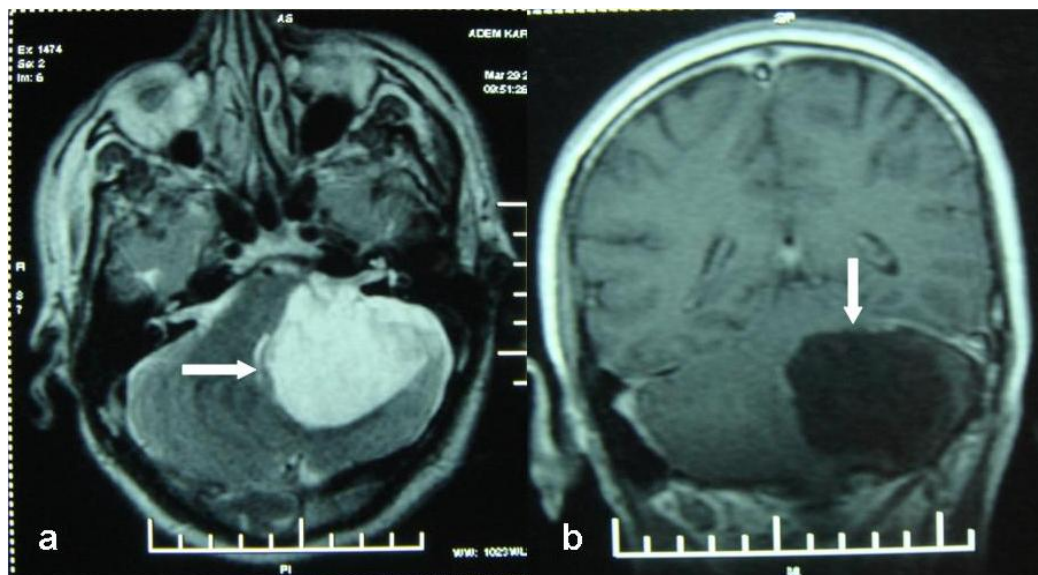
## Introduction

Behçet's disease is a multisystem chronic idiopathic inflammatory disease and about 5-10 % of these patients have central nervous system complications named as neuro-Behçet's disease (NBD) [1, 2]. Parenchymal involvement in NBD is frequently seen at brain stem, spinal cord, and cerebral hemispheres [3]. In Behçet's disease, different central nervous system lesions leading to different clinical pictures have been reported [4]. As far as we know, there is no data reporting the presence of epidermoid tumor of the cerebellum in Behçet's disease in the literature.

In this report, we are presenting a 47 year old man having epidermoid tumor at cerebellum suffering from Behçet's disease for 20 years.

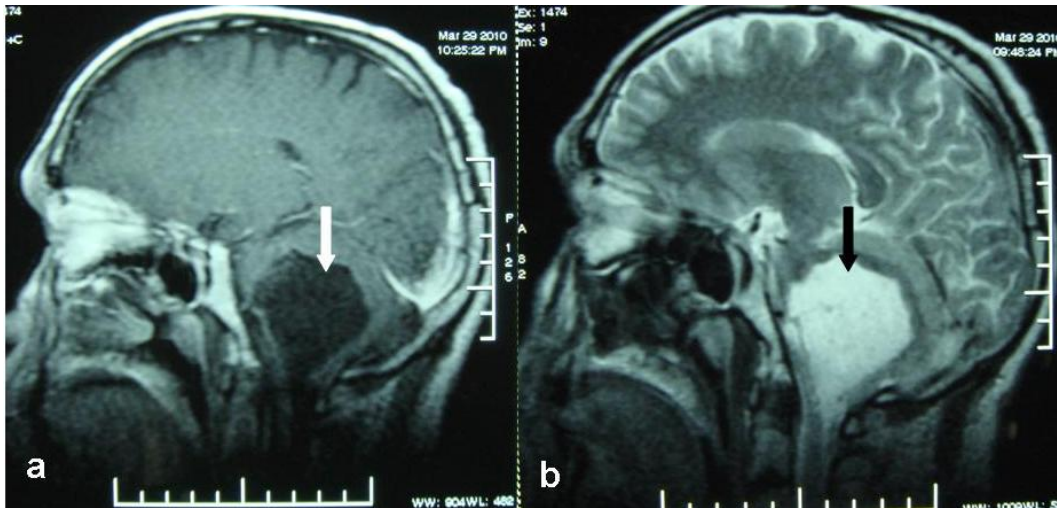
## Case report

A 47 year old man was admitted with the complaint of headache and ataxia for 2 months. His headache was more severe at the late hours of the morning without history of nausea, vomiting, epilepsy, and loss of consciousness. After admission he was found to have Behçet's disease for 20 years and was under remission. In physical examination there was blindness at the left eye due to greatly uveitis in. In neurological examination ataxia to the right site, especially when walking, was determined. At the right side panduler reflex and also Romberg test was positive and. Cranial magnetic resonance imaging (MRI) revealed a lesion at the left cerebellopontin angle, which was extending through the cisterns to the mesencephalon superiorly, inferiorly to the brain stem, which was causing a compression on brain stem. Lesion causing a diffusion restriction was consistent with epidermoid tumor (Figure 1, 2). MR angiography was normal.



**Figure 1a. Axial T2 (a) and coronal (b) T1 weighted cranial brain MR images showing lesion in the cerebellum (white arrows)**

Tumor was removed totally throughout left suboccipital craniectomy. It was dirty-white (pearl-like) in color and very fragile. Pathology report confirmed the diagnosis of an epidermoid tumor.



**Figure 2a.** Sagittal T1 a and T2 b weighted cranial (b) brain MR images showing lesion in the cerebellum (white and black arrows)

## Discussion

Behçet's disease a multisystem chronic idiopathic inflammatory and recurrent disease characterized by uveitis, oral aphtae, genital ulcers, and skin lesions [1, 2, 5]. Our patient had suffered from uveitis and oral lesions. Its etiology and pathogenesis could not be determined in the lights of data available in the literature. This disease is prevalent in Turkey, Japan, Middle East, and in many other Mediterranean countries [4, 5]. About 5-10 % of Behçet' disease cases may show central nervous system lesions named as neuroBehçet's disease [2]. Neurologic symptoms may become apparent for several years, even more than 10 years, after the appearance of initial symptoms [8]. Although there are still some limitations in the differential diagnosis with other lesions, MRI is currently the most sensitive method for the radiological diagnosis of NBD [6]. The advent of MRI enabled both the early and increased number of new neuro-Behçet cases by the way of detecting minute lesions [7]. In our case, MRI provided some clues about the definite diagnosis, however, arachnoid cyst constituted a greater percentage in our preoperative differential diagnosis. Abscess formation and low-grade astrocytomas were considered in the second line. Central nervous system involvement of Behçet's disease can be divided into two main groups; parenchymal and non-parenchymal. Non-parenchymal involvement is also known as neuro-vasculo-Behçet's disease. Central nervous system involvement includes brain stem involvement, hemispherical manifestations, spinal cord lesions, and encephalitic presentations [1]. The most common presentation is the brainstem involvement [9]. Next common sites are basal ganglia and white matter. Cerebellar involvement was reported only in a few studies [10, 11]. Many different presentations are also known in this disease [4]. Some studies reported the association with different neurological syndromes or pathologies [1]. Recently, Ho and Deruytter [12] have reported the association of this disease with cerebral abscess in one case and aneurysm of superior cerebellar artery in another case. Neuro Behçet's diseases (NBD) mimicking brain tumor or tumors have been reported in the literature [8, 10, 12, 13]. Histological findings of NBD can be summarized as perivascular cuffing of small lymphocytes, microcystic softening, demyelination, and gliosis [2, 10].

Coexistence of Behçet's disease and epidermoid tumor is coincidental. There is no known association between Behçet's disease and epidermoid tumor in the literature. Literature contains several reports about neuro-Behçet's diseases mimicking tumor, however, there is also no data about the incidence of certain types of tumor/s in Behçet's disease. Literature suggests that this could be a coincidental finding and, we do not, think any strong correlation between them. Therefore further studies are needed to support this idea and to provide information on common tumors in such patients.

## References

1. Borhani-Haghighi A, Samangoie S, Ashijazadeh N, Nikseresht A, Shariat A, Yousefipour G, Safari A. Neurological manifestations of Behcet's disease. *Saudi Med J* 2006; 27: 1542-6.
2. Evereklioglu C. Current concepts in the etiology and treatment of Behçet disease: major review. *Surv Ophthalmol* 2005; 50: 297-350.
3. Shahien R, Bowirrat. Neuro-Behçet's disease: a report of sixteen patients. *Neuropsychiatr Dis Treat* 2010; 6: 219-25.
4. Kidd D, Steuer A, Denman AM, Rudge P. Neurological complications in Behçet syndrome. *Brain* 1999; 122: 2183-94.
5. Tajima Y, Homma S, Sinpo K, Maruo Y, Moriwaka F, Tashiro K. Clinico-radiological findings of neuro-Behçet's syndrome. *Intern Med* 1994; 33: 136-41.
6. Heo JH, Lee ST, Chu K, Kim M. Neuro-Behcet's disease mimicking multiple brain tumors: diffusion-weighted MR study and literature review. *J Neurol Sci* 2008; 264: 177-81.
7. Kazui S, Naritomi H, Imakita S, Yamada N, Ogawa M, Sawada T. Sequential gadolinium-DTPA enhanced MRI studies in neuro-Behçet's disease. *Neuroradiology* 1991; 33: 136-9.
8. Matsuo K, Yamada K, Nakajima K, Nakagawa M. Beuro-Behçet disease mimicking brain tumor: case report. *AJNR Am J Neuroradiol* 2005; 26: 650-3.
9. Akman-Demir G, Serdaroglu P, Tasci B. The Neuro-Behcet Study Group. Clinical patterns of neurological involvement in Behcet's disease: evaluation of 200 patients. *Brain* Nov 1999; 122: 2171-82.
10. Park JH, Jung MK, Bang CO, Park HK, Sung KB, Ahn MY, Bae WK, Chi JG. Neuro-Behcet's disease mimicking a cerebral tumor: a case report. *J Korean Med Sci* 2002; 17: 718-22.
11. Koçer N, Islak C, Siva A, Saip S, Akman C, Kantarci O, Hamuryudan V. CNS involvement in neuro-Behcet syndrome: an MR study. *AJNR Am J Neuroradiol* 1999; 20: 1015-24.
12. Ho CL, Deruytter MJ. Manifestations of neuro-Behcet's disease. Report of two cases and review of the literature. *Clin Neurol Neurosurg* 2005; 107: 310-4.
13. Imoto H, Nishizaki T, Nogami K, Sakamoto K, Nomura S, Akimura T, Matsunaga T, Suzuki M. Neuro-Behcet's disease manifesting as a neoplasm-like lesion: Case report. *Neurol Med Chir* 2002; 42: 406-9.