

Case report-Olgu sunumu

Endoscopic management of biliary fasciolosis

Biliyer fasyoliyazın endoskopik tedavisi

Yaşar Tuna*

Department of Gastroenterology (Y. Tuna, MD), Akdeniz University School of Medicine, TR-07059 Antalya

Abstract

Fasciola hepatica is an endemic parasite in Turkey that belongs to the flatworm family. This parasite is seen commonly among domestic animals (such as goats, sheep, and cattle) and is sporadic in human. Biliary fascioliasis is a rare condition. It has a hepatic and a biliary stage. Symptoms during the acute phase include fever, right upper quadrant pain, eosinophilia, and hepatomegaly. The parasite may remain asymptomatic for many years in chronic stage of the infection. Here we present a case of biliary fascioliasis who was admitted to the hospital with episodes of severe abdominal pain, nausea and vomiting and was accidentally diagnosed by endoscopic retrograde cholangiopancreatography.

Keywords: Biliary fascioliasis; endoscopic retrograde cholangiopancreatography

Özet

Fasciola hepatica Türkiye’ de endemik bir parazittir. Yaprak solucanlar ailesinden olan bu parazit genellikle keçi, koyun, sığır gibi evcil hayvanlarda görülür. İnsan da ise sporadiktir. Biliyer *fasciola hepatica* nadir bir durumdur. Hepatik ve biliyer evrelere sahiptir. Akut fasyoliyazda semptomlar ateş, sağ üst kadrın ağrısı, eozinofili, ve hepatomegalidir. Enfeksiyonun kronik evresinde parazit yıllarca asemptomatik kalabilir. Bu makalede, şiddetli karın ağrısı atakları, bulantı ve kusma şikayetleri ile hastanemize başvurup, endoskopik retrograd kolanjiopankreatografi tetkiki ile tesadüfen biliyer fasyoliyaz tanısı alan bir olgu sunulmuştur.

Anahtar Sözcükler: Biliyer fasyoliyaz, Endoskopik Retrograd Kolanjiopankreatografi

Geliş tarihi/Received: December 09, 2010; **Kabul tarihi/Accepted:** December 28, 2010

*Corresponding author:

Yaşar Tuna, MD, Gastroenteroloji Anabilim Dalı, Akdeniz Üniversitesi Tıp Fakültesi, TR-07059 Antalya. E-mail: yasartuna61@hotmail.com

Introduction

The trematode *Fasciola hepatica* is a liver fluke that typically infects cattle, sheep, and goats, causing fasciolosis. It is transmitted to humans via contaminated water and vegetables. The larvae penetrate the intestinal wall and enter the peritoneal cavity, pass through the hepatic capsule and reach the liver tissue where they turn into mature parasites. They access the biliary tract from there [1]. Fascioliasis has been most commonly reported from Europe, Latin America, Middle East and Asia [2]. The most commonly encountered acute symptom and findings are fever, abdominal pain and eosinophilia. Nevertheless, in the chronic phase of the disease biliary obstruction, cholangitis and pancreatitis are most commonly seen [3-6].

In this case report, we present a rare case of fasciolosis that caused episodes of biliary obstruction and treated with endoscopic extraction.

Case report

A 44 year old female was admitted to our clinic with abdominal pain and nausea. She had been experiencing abdominal pain following meals mainly in the right upper quadrant for two days. Her pain was accompanied by nausea. She had applied to the emergency service with the same complaints for two times in a period of two months and her pain had relieved with analgesics. Her physical examination was normal except for right upper quadrant tenderness. In her laboratory work up her hemoglobin value was 11.2 g/dL, Leucocytes: 7100/mm³, eosinophil count 170/mm³, Plt: 284000/mm³, Urea: 12 mgr/dL, creatinine: 0,8 mg/dl, AST: 44 U/L, ALT: 48 U/L, GGT: 140 U/L. Abdominal ultrasonography showed a thickened wall of gallbladder with a 10 mm width of choledochus and a 3x8 mm echogenic structure was present at the proximal part of choledochus that lacked an acoustic shadow. There was a 5 mm stone in the gallbladder without acoustic shadow. The MR cholangiography showed a 12 mm wide choledochus and an 8mm hypointense image consistent with a stone in the distal edge of the choledochus (Figure 1).

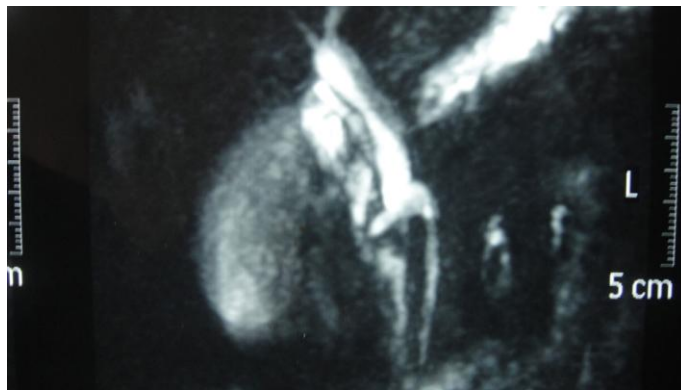


Figure 1. MR cholangiography revealing a parasite in common bile duct.

The endoscopic retrograde cholangiopancreatography showed that the common bile duct was 10mm and an image of 8mm wide, consistent with a stone was present in the distal edge of the common bile duct. Sphincterotomy was performed and alive fasciola hepatica parasite was fell into the duodenum. It was retrieved from the duodenum with a basket (Figure 2). At the follow-up visit, she was well and her clinical and laboratory assessments were within normal limits.

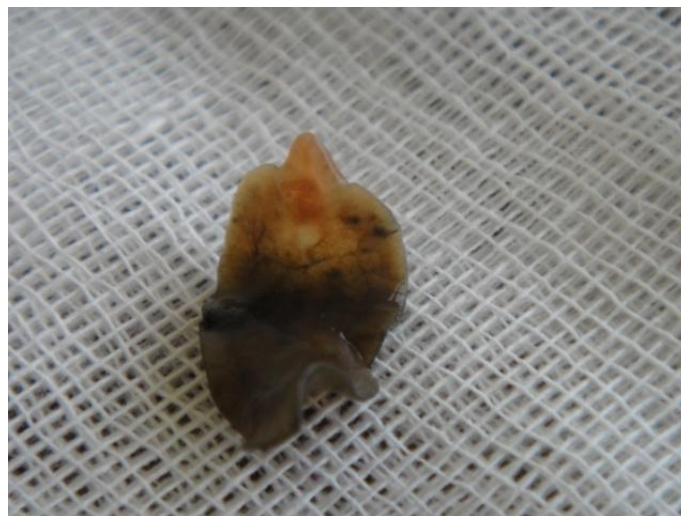

Figure 2. Fasciola hepatica in vitro.

Discussion

The patient was scheduled for the ERCP procedure with repetitive complaints of nausea and abdominal pain. Ultrasonography and MRCP imaging was suggesting a common bile duct stone. Cholestasis findings were apparent at admission. Endoscopic retrograde cholangiopancreatography (ERCP) was performed with the diagnosis of choledocholithiasis. A flat, stone-like image was seen during the ERCP procedure. The fasciola hepatica parasite was retrieved from choledochus with a balloon catheter. The patient's abdominal pain episodes were probably due to fasciola hepatica. The stone-like appearance with no acoustic shadow seen two months ago in the ultrasonography may be due to the parasite of the fasciola hepatica. The clinical presentation of fasciola hepatica depends on the two different phases of the disease. The acute phase is seen when parasite migrate to the parenchyma of the liver and may last up to 3 months following the oral ingestion of the metacercariae. The metacercariae travels to the duodenal wall, peritoneal cavity, liver parenchyma and finally bile ducts and matures after ingestion [5]. In the initial hepatic invation, fever, abdominal pain, eosinophilia, hepatomegaly and typical acute phase findings may be observed [6]. Ascites, hepatitis, subcapsular bleeding, hepatic necrosis, pulmonary infiltration and effusion have been reported during this phase [2, 6]. The chronic or biliary stage begins with the migration of the mature parasite to the bile duct and may stay asymptomatic for years. It causes bile duct inflammation, epithelial hyperplasia and fibrosis [7]. They may also lead to biliary obstruction [4, 8], pancreatitis [9] and hemobilia [2, 5]. The patient was scheduled for the ERCP procedure with repetitive complaints of nausea and abdominal pain and her ultrasonography and MRCP imaging was suggesting a common bile duct stone. Cholestasis findings were apparent at admission. However after the patients complaints repeated for a couple of times, MRCP and ultrasonography imaging was performed. Then an ERCP was performed. A flat, stone-like image was seen during the ERCP. The fasciola hepatica parasite was retrieved from the common bile duct with a balloon catheter. The abdominal pain episodes were probably due to fasciola hepatica. The stone-like appearance with no acoustic shadow seen two months ago in the ultrasonography may be due to fasciolosis. The diagnosis is usually difficult because it has no specific clinical presentation. The ELISA test is sensitive for diagnosis during the acute phase [6, 10]. During the chronic phase the diagnosis can be established by parasitological examination of feces or duodenal fluid samples with a low sensitivity [2, 11]. In our case, ultrasonography and MRCP was performed following clinical suspicion which showed, stone-like image and we aimed to treat it with ERCP. An incidentally fasciola hepatica was extracted with ERCP. Multiple cases of obstructive jaundice due to fasciola hepatica have been reported. The gold standard for the imaging of bile ducts in such patients is ERCP [4, 8, 12]. Treatment with antiparasitic medication is also recommended. Praziquantel 30-75 mg/d, bithional 30 mg/d [13, 14], triclobendazole 5-10 mg [15] are effective medications. These medications are difficult to obtain in Turkey. Albendazole, metronidazol, and niclofolan are other agents that have been used [15, 17, 18]. In the chronic phase ERCP can be used to treat biliary obstruction and following sphincterotomy parasite extraction can be performed with a basket or balloon catheters [4, 8, 12].

In conclusion chronic fasciola hepatica can rarely cause episodic abdominal pain. Fasciolosis should be a part of the differential diagnosis of common bile duct obstruction. In patients who have mild biliary obstruction findings such as the present case, ERCP should be used for diagnosis and treatment of biliary fascioliasis.

References

1. Mahmoud AAF. Trematodes (Schistosomiasis) and other flukes. In: Mandell GL, Bennett JE, Dolin R eds. Mandell, Douglas, Bennett's Principles and practice of infectious diseases, 5th ed. New York: Churchill Livingstone, 2000; 2950-5.

2. Harinasuta T, Pungpak S, Keystone JS. Trematode infections. Opisthorchiasis, clonorchiasis, fascioliasis, and paragonimiasis. *Infect Dis Clin North Am* 1993; 7: 699-716.
3. Graham CS, Brodie SB, Weller PF. Imported *Fasciola hepatica* infection in the United States and treatment with triclabendazole. *Dis Clin Infect* 2001; 33: 1-5.
4. El-Newihi HM, Waked IA, Mihas AA. Biliary complications of *Fasciola hepatica*: the role of endoscopic retrograde cholangiography in management. *J Clin Gastroenterol* 1995; 21: 309-11.
5. Reddy DN, Sriram PV, Rao GV. Endoscopic diagnosis and management of tropical parasitic infestations. *Gastrointest Endosc Clin N Am* 2003; 13: 765-73.
6. Price TA, Tuazon CU, Simon GL. Fascioliasis: case reports and review. *Clin Infect Dis* 1993; 17: 426-30.
7. Carpenter HA. Bacterial and parasitic cholangitis. *Mayo Clin Proc* 1998; 73: 473-8.
8. Ozer B, Serin E, Gümürdülü Y, Gür G, Yılmaz U, Boyacıoğlu S. Endoscopic extraction of living *fasciola hepatica*: case report and literature review. *Turk J Gastroenterol* 2003; 14: 74-7.
9. Echenique-Elizondo M, Amondarain J, Lirón de Robles C. Fascioliasis: an exceptional cause of acute pancreatitis. *JOP* 2005; 6: 36-9.
10. Carnevale S, Rodríguez MI, Santillán G, Labbé JH, Cabrera MG, Bellegarde EJ, Velásquez JN, Trgovcic JE, Guarnera EA. Immunodiagnosis of human fascioliasis by an enzyme-linked immunosorbent assay (ELISA) and a micro-ELISA. *Clin Diagn Lab Immunol* 2001; 8: 174-7.
11. Adachi S, Kotani K, Shimizu T, Tanaka K, Shimizu T, Okada K. Asymptomatic fascioliasis. *Intern Med* 2005; 44: 1013-5.
12. Gulsen MT, Savas MC, Koruk M, Kadayifci A, Demirci F. Fascioliasis: a report of five cases presenting with common bile duct obstruction. *Neth J Med* 2006; 64: 17-9.
13. Arjona R, Riancho JA, Aguado JM, Salesa R, González-Macías J. Fascioliasis in developed countries: a review of classic and aberrant forms of the disease. *Medicine (Baltimore)* 1995; 74: 13-23.
14. Farag HF, Salem A, el-Hifni SA, Kandil M. Bithionol (Bitin) treatment in established fascioliasis in Egyptians. *J Trop Med Hyg* 1988; 91: 240-4.
15. Loutan L, Bouvier M, Rojanawisut B, Stalder H, Rouan MC, Buescher G, Poltera AA. Single treatment of invasive fascioliasis with triclabendazole. *Lancet* 1989; 2: 383.
16. Nik-Akhtar B, Tabibi V. Metronidazole in fascioliasis: report of four cases. *J Trop Med Hyg* 1977; 80: 179-80.
17. Chen MG, Mott KE. Progress in assesment of morbidity due to *Fasciola hepatica* infection: a review of recent literature. *Trop Dis Bull* 1990; 87: R1-R38.
18. Eckhardt T, Heckers H. Treatment of human fascioliasis with niclofolan. *Gastroenterology* 1981; 81: 795-8.