

An aggressive Basal Cell Carcinoma with multiple focuses and distant lung metastasis: case report

Multipl odaklı, agresif davranışlı ve uzak metastaz içeren Bazal Hücreli Karsinom

Havva Erdem*, Nilüfer Kadioğlu, Ali Kemal Uzunlar, Ümran Yıldırım, Murat Oktay, Cem Şahiner, Derya Özçelik, Hakan Turan

Department of Pathology (Assist. Prof. H. Erdem, MD, N. Kadioğlu, MD, Prof. A. K. Uzunlar, MD, Assoc. Prof. Ü. Yıldırım, MD, Assist. Prof. M. Oktay, MD, C. Şahiner, MD), Department of Plastic surgery (Prof. D. Özçelik, MD), Department of Dermatology (Assist. Prof. H. Turan, MD), Düzce University School of Medicine, TR-81000 Düzce

Abstract

Basal cell carcinoma (BCC) is a malignant neoplasm derived from nonkeratinizing cells that originate from the basal layer of the epidermis and it is the most common type of skin cancer in humans. Giant BCC (i.e. greater than 5 cm in diameter) is quite rare and comprises 0.5 percent of all BCC. Despite the high incidence of BCC, metastasis of this tumor is rare, with rates ranging from 0.0028% to 0.55% of all BCC cases. In this case, the tumour reached a giant size and had a pulmonary metastasis. We aimed to emphasize that although BCC's are usually indolent; the importance of adequate surgery and chemoradiotherapy should always be considered in indicated cases.

Keywords: Basal cell carcinoma, metastasis, giant size, adequate surgery

Özet

Bazal hücreli karsinom (BHK) epiderminin bazal tabakasından kaynaklanan ve nonkeratinize hücrelerden oluşan en yaygın cilt tümörüdür. Dev BHK (yani çapı 5 cm'den büyük) oldukça nadirdir ve tüm BHK'ların %0,5' ini oluşturmaktadır. BHK insidansı yüksek olmasına rağmen, bu tümörün metastaz oranı tüm vakaların %0,0028-%0,55 arasında değişmektedir. Bu vakada tümör dev boyuta ulaştı ve akciğer metastazı vardı. Burada, BHK'lar genellikle yavaş seyirli olmasına rağmen gerekli vakalarda yeterli cerrahi ve kemoradyoterapinin önemini vurgulamak istedik.

Anahtar sözcükler: Bazal hücreli karsinom, metastaz, dev çap, yeterli cerrahi

Geliş tarihi/Received: April 07, 2012; **Kabul tarihi/Accepted:** October 15, 2012

***Corresponding author:**

Dr. Havva Erdem, Patoloji Anabilim Dalı, Düzce Üniversitesi Tıp Fakültesi, TR-81000 Düzce. E-mail: drhavvaerdem@hotmail.com

Introduction

Basal cell carcinomas (BCC) are the most common cutaneous tumors, accounting for approximately 70% of all malignant diseases of the skin [1]. BCC develop predominantly in sun-damaged skin in individuals who are fair skinned and prone to sunburn. Typically they have a pearly appearance with telangiectasia that may appear as a papule or nodule that can be eroded or ulcerated. The multiple variants of basal cell carcinoma are cords of basaloid cells and connected by the common histological feature of lobules, columns, bands associated with scant cytoplasm and artefactual retraction spaces between the tumour and stroma. It often presents a characteristic outer palisade of cells associated with a surrounding loose fibromucinous stroma [2]. BCC generally occur as single

lesions, although the occurrence of several lesions, either simultaneously or subsequently, is not infrequent [3]. It is usually encountered when it is small in size. Giant BCC (i.e. greater than 5 cm in diameter) is quite rare and comprises 0.5 percent of all BCC [4]. Basal cell carcinomas (BCC) are locally invasive tumors of slow progression and are seldom metastatic [6-9] and rates ranging from 0.0028% to 0.55% of all BCC cases [5]. Because of these characteristics, doubts have been raised regarding their malignancy. Occasional cases of highly invasive [6], sometimes metastatic [7,8] forms are nevertheless observed. Some histological subtypes, e.g. infiltrative aggressive-type, seem to have a higher potential for recurrence [9]. Although most basal cell carcinomas are slow-growing, relatively non-aggressive tumors that are cured by most methods of treatment, a minority have an aggressive behavior with local tissue destruction and, rarely, metastasis [10]. Aggressive subtypes have been linked with chronic sun exposure [10]. These aspects will be considered in further detail after the histopathology has been discussed.

Case report

A 57-years man with a smoking history of 10 years was admitted to our hospital's Plastic and Reconstructive surgery department with a complaint of a lesion that covered his left eye. Lesion was inflamed and necrotic. The patient had a surgery from his right pinna in 1999. He had noticed lesions above his right eyebrow, on his nose and on his right hand after the surgery (figure 1).

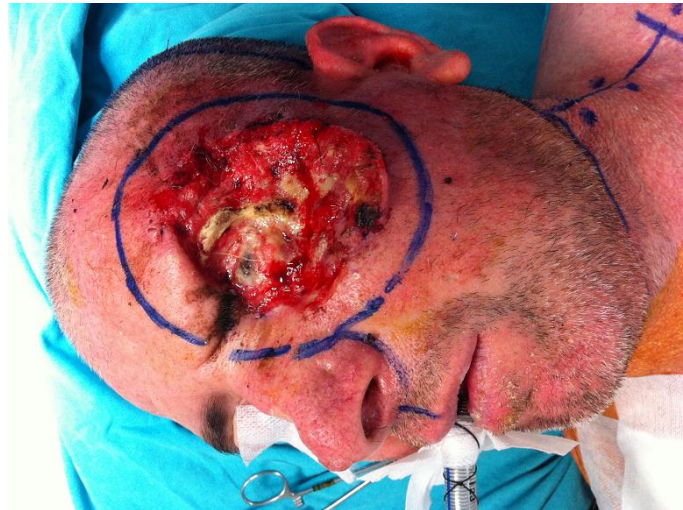

Figure 1. A complaint of a lesion that covered left eye.

He had neglected and had not any treatment for his recurrent lesions until the year 2007. Biopsy was performed from these lesions in 2007. Microscopically the tumour cells invaded through the dermis, with palisading of the cells at the periphery. The tumor cells had a basophilic cytoplasm, increased nucleo/cytoplasmic ratio, prominent nucleoli, ill defined cell border. The case was diagnosed as BCC according to histopathological findings. Surgical excision was performed. He was suggested to take radiotherapy, because tumour surgery line was observed positive. He started radiotherapy but did not complete the treatment. Lesions had covered his left eye in 2011 then he was admitted to our hospital. Biochemical findings were within normal limits. A nodular lesion at right medial lobe of his lung with a diameter of 8.5 x 8 mm and 1 lymphadenopathy at left submandibular region were seen in dynamic contrast magnetic resonance imaging (MRI). These findings were considered to be a metastasizing lesion. Frozen section was performed to the lesion. Microscopically the tumour cells had hyperchromatic nucleus, increased N/S ratio, basophilic cytoplasm with palisading. Case was diagnosed as BCC (figure 2). Nodular lesion at lung was surgically removed (figure 3). Then eye enucleation, maxilla

anterior segment excision, left servical neck dissection was performed. Macroscopically tumour was 7.5 x 4 x 2 cm. Histopathologically there were palisading of the cells at the periphery. The tumor cells had a basophilic cytoplasm, increased N/S ratio, prominent nucleoli, ill defined cell border like the primary tumour. Tumour cells infiltrated the subcutaneous tissue with perineural invasion. It was diagnosed as infiltrating types of BCC. He began to receive chemotherapy and no recurrence was noted during 6 months follow-up.

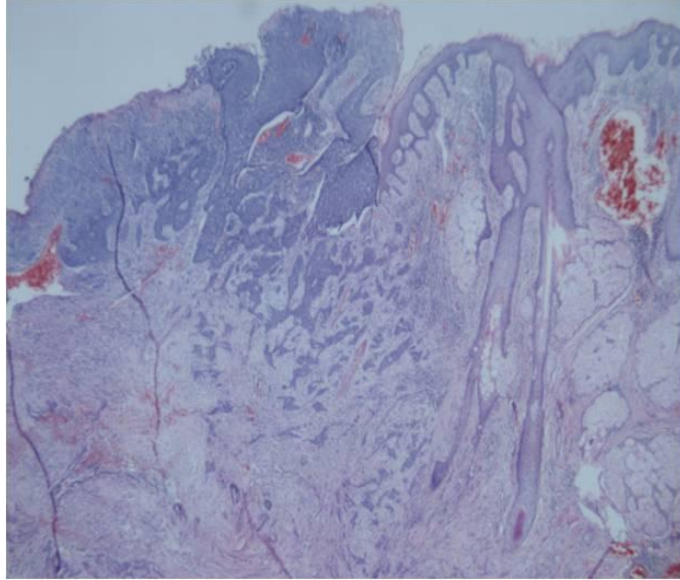


Figure 2. The tumor cells increased N/S ratio (hematoxylin- eosine x 100).

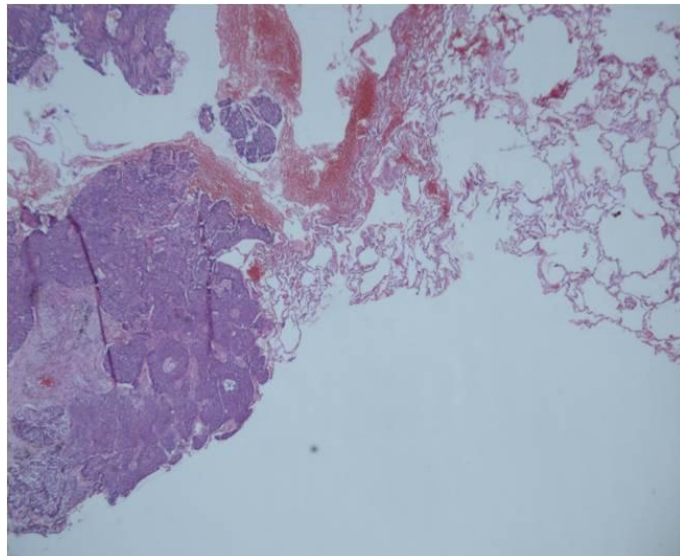


Figure 3. Palisading of the cells adjacent to alveoli (hematoxylin- eosine x 100).

Discussion

The first report of metastatic basal cell carcinoma (MBCC) in the literature was in 1894 by Beadles [11]. The usual criteria used for the acceptance of metastatic basal cell carcinoma are a previous or actual primary lesion in the skin and a metastatic lesion that has a histological picture similar to that of the primary, and which could not have arisen by direct extension from the primary lesion [10].

The formal diagnostic criteria for MBCC defined by Lattes and Kessler in 1951 include the following conditions: 1) the primary lesion must originate in the epidermis or follicular skin and not mucinous tissue, 2) spread must be to a distant site and not represent simple extension, 3) the primary and metastatic lesions must have a similar histologic appearance of BCC, and 4) no squamous cell features may be present. Risk factors associated with the rare occurrence of metastasis include tumor size of less than 2cm, multiple primary tumors in the region of the head and neck, significant tumor depth, fair skin, middle age, and male gender. Risk of metastasis has been further shown to specifically correlate with the size of the primary tumor; tumors greater than 3cm conferring 2 percent risk, greater than 5cm conferring 25 percent risk, and greater than 10cm conferring 50 percent risk. Immunocompromised patients and those with primary BCC of the head and neck (65-88% of all BCC) are also more likely to have metastatic disease [12]. In this case the primary lesion originated in the epidermis, lung was the metastasizing site and histopathologically it was the same as it was seen in the epidermis. And there were signs of squamous cell features. According to these diagnostic criteria; the criteria for MBCC defined by Lattes and Kessler was fulfilled (originate in the epidermis, distant site, similar histologic appearance e.g.). Metastases occur most commonly in the regional lymph nodes [10]. Metastatic basal cell carcinoma was diagnosed by sentinel lymph node biopsy in one case [10]. It was only carried out because lymphatic invasion was present in the primary cutaneous basal cell carcinoma. Bones, lungs, and liver are less frequent sites of involvement [10]. This case was found to have pulmonary metastasis and recurrences. Histological types of BCC have been associated with different results and prognosis. Tumors can be classified as nodular, superficial, micronodular, morpheic variety, infiltrating, pigmented, metatypic and fibroepithelioma of Pinkus [13]. Barbaud et al. [8] performed a retrospective histological and immunohistochemical study on 66 basal cell carcinomas (BCC). They showed that all the clinically recurrent tumors were infiltrative aggressive-type BCC. Gropper et al. [14] reported a metastatic basal cell carcinoma (nodular, adenoid infiltrative morphology) of the posterior neck. This case was reported as infiltrating types of BCC. The 5-year recurrence rate for basal cell carcinomas is approximately 5%, although this varies with the type of treatment [15]. Although one study found almost no difference in the recurrence rate of completely excised tumors and those with tumor excision at one margin, the distance to the closest resection margin is an important predictor of recurrence [16-19]. The goal of treatment is complete excision of the tumor with preservation of surrounding structures in a way aesthetically acceptable [19, 20]. Mohs' micrographic surgery is the standard treatment for all nonmelanoma skin cancer [20-22]. In a clinical trial by Kwan et al. [22], on 61 samples of patients with BCC diagnosis and treated with radiotherapy, a 4-year local disease control was achieved in 86%, finding no evidence of factors affecting loco-regional control. Median time of relapse was 40.5 months and relapses were locally situated in all cases. The patient had a surgery from his right pinna in 1999. He had noticed lesions above his right eyebrow, on his nose and on his right hand after the surgery. He had neglected and had not any treatment for his recurrent lesions until the year 2007. Low level of knowledge about skin tumors may be the explanation in some cases and a low social milieu, inadequate hygienic culture associated with poverty. Slowly growing and old age, not painful neoplasm may also result in a delay in seeking medical advice [23]. Giant BCC presents some common epidemiological factors that include multiplicity of tumors, race, development on sun-covered areas, neglect and tumor chronicity. Immunodeficiency and genetic predisposition to BCC in other family members are not consistent factors, whereas patients who develop a single small BCC, giant BCC frequently develops on skin that is not typically exposed to sunlight, including the back, shoulder, leg and thigh [24]. Our patient applied to hospital in 1999 and underwent surgery treatment. But he did not receive radiotherapy and chemotherapy.

In conclusion, when BCC is left untreated for any reason it can reach giant size and can

metastasize. Therefore, patients should be followed up.

References

1. Weedon D. Tumors of epidermis. In Tumors of Weedon's Skin Pathology. 3rd ed. Weedon D (Eds). New York: Churchill-Livingstone Elsevier; 2010: 682-3.
2. Leboit PE, Burg G, Weedon D, Sarasin A. ed. World Health Organization Classification Of Tumours Pathology & Genetics Skin Tumours, Lyon,2006
3. Elder DE, Elenitsas R, Johnson BL Jr, Murphy GF. Lever's Histopathology of the Skin. 9th ed. Philadelphia, PA: Lippincott Williams and Wilkins 2005: 836-49.
4. de Bree E, Laliotis A, Manios A, Tsiftsis DD, Melissas J. Super giant basal cell carcinoma of the abdominal wall: still possible in the 21st century. *Int J Dermatol* 2010; 49: 806-9.
5. Seo SH, Shim WH, Shin DH, Kim YS, Sung HW. Pulmonary metastasis of Basal cell carcinoma. *Ann Dermatol* 2011; 23: 213-6.
6. Ko CB, Walton S, Keczek K. Extensive and fatal basal cell carcinoma: a report of three cases. *Br J Dermatol* 1992; 127: 164-7.
7. Mikhail GR, Nims LP, Kelly AP Jr, Ditmars DM Jr, Eyler WR. Metastatic basal cell carcinoma: review, pathogenesis, and report of two cases. *Arch Dermatol* 1977; 113: 1261-9.
8. Barbaud A, Simon M, Parache RM, Serre G. Immunohistochemical characterization of the differentiation state of basal cell carcinomas with special interest for infiltrating relapsing tumors. *Eur J Dermatol* 1998; 8: 320-4.
9. Bozikov K, Taggart I. Metastatic basal cell carcinoma: is infiltrative/morpheaform subtype a risk factor? *Eur J Dermatol* 2006; 16: 691-2.
10. Weedon D. Tumors of epidermis. In Tumors of Weedon's Skin Pathology. 3rd ed. Weedon D (Eds). New York: Churchill-Livingstone Elsevier; 2010: 690-1.
11. Ten Seldan R, Helwig R. Types histologiques des tumeurs cutanées. In: Ten Seldan R, Helwig R (Eds). Classification histologique internationale des tumeurs. Genève: WHO Inc 1975: 49-50.
12. Ozgediz D, Smith EB, Zheng J, Otero J, Tabatabai ZL, Corvera CU. Basal cell carcinoma does metastasize. *Dermatol Online J* 2008; 14: 5.
13. Rigel DS, Robins P, Friedman RJ. Predicting recurrence of basal-cell carcinomas treated by microscopically controlled excision: A recurrence index score. *J Dermatol Surg Oncol* 1981; 7: 807-10.
14. Gropper AB, Girouard SD, Hojman LP, Huang SJ, Qian X, Murphy GF, Vleugels RA. Metastatic basal cell carcinoma of the posterior neck: case report and review of the literature. *J Cutan Pathol* 2012; 39: 526-34.
15. Rowe DE, Carroll RJ, Day CL Jr. Long-term recurrence rates in previously untreated (primary) basal cell carcinoma: implications for patient follow-up. *J Dermatol Surg Oncol* 1989; 15: 315-28.
16. Hauben DJ, Zirkin H, Mahler D, Sacks M. The biologic behavior of basal cell carcinoma: analysis of recurrence in excised basal cell carcinoma: Part II. *Plast Reconstr Surg* 1982; 69: 110-6.
17. Dixon AY, Lee SH, McGregor DH. Factors predictive of recurrence of basal cell carcinoma. *Am J Dermatopathol* 1989; 11: 222-32.
18. Dixon AY, Lee SH, McGregor DH. Histologic features predictive of basal cell carcinoma recurrence: Results of a multivariate analysis. *J Cutan Pathol* 1993; 20: 137-42.
19. Chakrabarty A, Geisse JK. Medical therapies for non-melanoma skin cancer. *Clin Dermatol* 2004; 22: 183-8.
20. Gibbs P, Gonzalez R, Lee LA, Walsh P. Medical management of cutaneous malignancies. *Clin Dermatol* 2001; 19: 298-304.
21. Seegenschmiedt MH, Oberste-Beulmann S, Lang E, Lang B, Guntrum F, Olschewski T. Radiotherapy for basal cell carcinoma. Local control and cosmetic outcome. *Strahlenther Onkol* 2001; 177: 240-6.

22. Kwan W, Wilson D, Moravan V. Radiotherapy for locally advanced basal cell and squamous cell carcinomas of the skin. *Int J Radiat Oncol Biol Phys* 2004; 60: 406-11.
23. Varga E, Korom I, Raskó Z, Kis E, Varga J, Oláh J, Kemény L. Neglected Basal cell carcinomas in the 21st century. *J Skin Cancer* 2011; 2011: 392151.
24. Heo YS, Yoon JH, Choi JE, Ahn HH, Kye YC, Seo SH A case of superficial giant Basal cell carcinoma with satellite lesions on scalp. *Ann Dermatol* 2011; 23: S111-5.