

Percutaneous radiologic gastrostomy

Perkütan radyolojik gastrostomy

Hasanali Durmaz, Arda Halil Ceylan, Erdem Birgi, Onur Ergun, Baki Hekimoğlu

University of Health Sciences, Diskapi Yildirim Beyazit Training and Research Hospital, Department of Radiology

Corresponding author: Hasanali Durmaz, University of Health Sciences, Diskapi Yildirim Beyazit Training and Research Hospital, Department of Radiology

E-mail: dr.hasan.ali.durmaz@hotmail.com

Received/Accepted: May 31, 2019./June 25, 2019

Conflict of interest: There is not a conflict of interest.

SUMMARY





Objective: This study aimed to evaluate the success and complication rates of percutaneous radiological gastrostomy (PRG).

Method: The patients who had PRG in our interventional radiology unit between June 2012 and December 2018 were included in the study. Patients' procedure reports and images were evaluated retrospectively. Patients' age, gender, diagnosis, technical success, and rate of complications of the procedure were the research parameters.

Results: A total of 23 patients were referred for PRG. (mean age 63.1 years range: 20-90 years) Indications for PRG were head-neck cancer, other cancers, stroke, and other neurologic disorders in 9 (39.2%), 6 (26.1%), 5 (21.7%) and 3 (13%) patients, respectively. Four patients had a replacement with a new gastrostomy catheter, and 19 patients had PRG for the first time. In the present study, the technical success rate was 100%. In 5 patients, minor complications were occurred in 30-day follow up (21.7%). Three patient died due to other comorbidities. There were no major complications.

Conclusions: PRG is a practical and safe procedure with a high success and low complication rates in patients with a need for enteral feeding.

Keywords: Percutaneous, radiological, gastrostomy

-  Hasanali Durmaz
-  Arda Halil Ceylan
-  Erdem Birgi
-  Onur Ergün

ORCID IDs of the authors:

H.D. 0000-0003-3230-9240

A.H.C.0000-0002-9409-9288

E.B. 0000-0001-7808-7300

O.E. 0000-0002-0495-0500

ÖZET

Amaç: Bu çalışmada merkezimizde perkütan radyolojik gastrostomi (PRG) uygulanan hastalardaki işlem başarı ve komplikasyon oranlarını sunmak amaçlanmıştır.

Yöntem: Girişimsel radyoloji ünitemizde Haziran 2012- Aralık 2018 tarihleri arasında PRG uygulanan hastalar çalışmaya dahil edilerek bu hastaların dosyaları, işlem görüntüleri ve raporları geriye dönük incelendi. Hastaların yaş, cinsiyet, tanı, işlem başarısı ve komplikasyonları not edildi.

Bulgular: PRG uygulanan toplam 23 hastanın 6'sı erkek (%26.1) 17'si kadın (%73.9) ve yaş ortalamaları 63.1 yıldır (aralık: 22-90 yıl). 9 hastada baş boyun kanseri (%39.2), 6 hastada diğer maligniteler (%26.1), 5 hastada SVO (%21.7) ve 3 hastada (%13) diğer nörolojik bozukluklar nedeniyle gastrostomi ile beslenmeye geçildi. 4 hastada mevcut katater değişimi yapılırken 19 hastada ilk defa PRG uygulandı. İşlem başarı oranı %100'dü. 30 günlük takipte 5 hastada minör komplikasyon (%21.7) izlenirken majör komplikasyon yaşanmadı. 3 hasta işlem ile ilişkili olmayan nedenlerle kaybedildi.

Sonuç: PRG, enteral beslenme ihtiyacı mevcut hastalarda yüksek başarı ve düşük komplikasyon oranlarıyla uygulanabilen pratik ve güvenli bir yöntemdir.

Anahtar sözcükler: Perkütan, radyolojik, gastrostomi

INTRODUCTION

Gastrostomy is a procedure used for an alternative enteral feeding route by inserting a catheter into the stomach in patients whose oral intake is inadequate or impossible and to provide decompression in gastrointestinal system obstructions. There is a need for gastrostomy in cases that lead to impaired swallowing functions, especially in head and neck malignancies and neurological disorders. Gastrostomy is the preferred method for long-term enteral nutrition in head and neck malignancies. Neurological diseases such as cerebrovascular accident (CVA), amyotrophic lateral sclerosis (ALS) and multiple sclerosis (MS) increase the risk of aspiration by impairing swallowing function. In such cases, feeding with gastrostomy becomes an option ¹.

Gastrostomy can be performed by surgical, endoscopic, or interventional radiological methods. Currently, surgical gastrostomy has been replaced by percutaneous endoscopic (PEG) and percutaneous radiological gastrostomy (PRG). There are various percutaneous gastrostomy methods, and different success rates have been reported in the literature. PRG is applied with the guidance of radiological imaging techniques and is less invasive compared to surgical and endoscopic methods. Compared to PEG, the tube-related complication rate is lower, and the procedure success rate is higher ². Minor complications following PRG are catheter obstruction, superficial skin infection around the catheter, leakage around the catheter and minor bleeding; major complications include peritonitis, abscess formation, necrotizing skin infections, internal bleeding, viscous perforation and death ^{1,3}.

In this study, we aimed to share the technical success and complication rates in patients undergoing PRG in our interventional radiology clinic and to contribute to the literature by transferring our experience in this field.

MATERIAL AND METHODS

Between June 2012 and December 2018, 23 patients underwent PRG in our interventional radiology unit were included in the study. The demographic data, images, and procedure reports of the patients were evaluated retrospectively. Age, gender, diagnosis, the success of the procedure, and postoperative complications were recorded. The data were analyzed by SPSS 23.0 statistical package program. Descriptive statistics were presented as mean, median (min; max), frequency distribution, and percentage. After explaining the procedure to the patients and their

relatives, written informed consent was obtained by informing them about the complications that may occur due to the procedure. The study was conducted by the Helsinki Declaration, and the approval of the ethics committee was obtained from our institution.

Hemogram and bleeding parameters of all patients were checked before the procedure. Patients with platelet counts above 50.000/ μ L and INR values below 1.5 selected for the procedure. The presence of colon interposition, hiatal hernia, and previous gastric surgery history was investigated. Patients with gastric varices and ascites as well as patients with a history of gastric surgery and gastric malignancy were evaluated as not suitable for PRG. The procedures were performed in the interventional radiology unit under fluoroscopy guidance. Colon interposition, liver, and spleen positions were evaluated by ultrasound (US) and computed tomography (CT) before the procedure. Routine antibiotic prophylaxis, sedation, or general anesthesia were not applied. All procedures were performed under local anesthesia.

During the procedure, the patients were in the supine position and monitored for vital signs. The nasogastric catheter was placed, and the stomach was inflated with air (Figure 1). Sterilization with povidone-iodine was performed after the entrance site was determined as lateral to rectus muscle at the subcostal area by fluoroscopy. After the injection of the local anesthetic agent into the planned insertion site, approximately 1-2 mm incision was made with a scalpel. Access to the gastric lumen was achieved through the distal corpus section by inserting 18-G needle that loaded with T-fastener (Harpon, Balt Extrusion®, Montmorency, France). Special attention was paid not to puncture the posterior wall. (Figure 2). After confirming that the needle was in the stomach lumen by injecting contrast agent, the T-fastener was advanced through the needle to the stomach lumen, and the gastric wall was fixed by hanging on the abdominal wall. Gastropexy was then performed with a second T-fastener adjacent to the entry site, leaving the appropriate space for catheter 342end. After the gastropexy needle was re-entered into the stomach between two T-fasteners fixed to the skin and confirmed to be in the lumen with a contrast agent, 0.035-inch J-typed hard guide wire was sent into the stomach lumen. The tract was expanded several times with the aid of dilators of the appropriate diameter advanced over the wire, and a 14 Fr (French) pigtail catheter (Flexima®, Boston Scientific, USA) was inserted into the stomach. Following

catheter insertion, the position of the catheter in the gastric lumen was confirmed by contrast agent injected from the catheter (Figure 3). After the procedure, patients were followed up for 24 hours for complications such as bleeding and

peritonism. After 24 hours, the ending was started by gastrostomy if no complication was observed. T-fasteners used for gastropexy were cut from the proximal part, and external parts were removed seven days after the procedure.

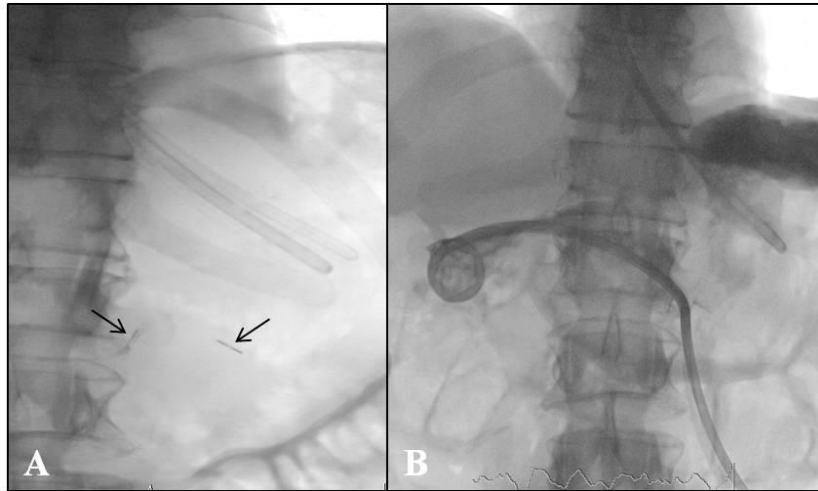


Figure 1: In the fluoroscopy images of the patient who underwent percutaneous radiological gastrostomy; the nasogastric catheter is inflated (A), and a 14 Fr catheter is inserted into the gastric lumen, followed by contrast (B) (black arrows: T-fastener).

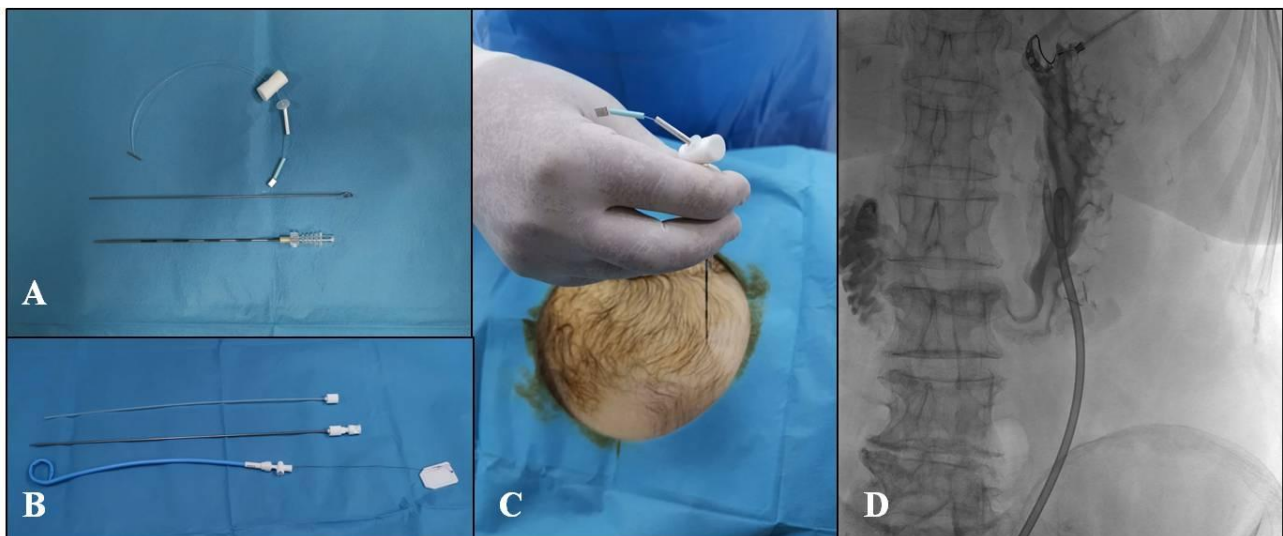


Figure 2: The gastropexy needle and T-fastener (A) and 14 Fr pigtail catheters (B) used during the percutaneous radiological gastrostomy procedure, the site of entry in the left subcostal region, the catheter in the gastric lumen stained with contrast agent and the contrast-stained gastric lumen are visible. (D).

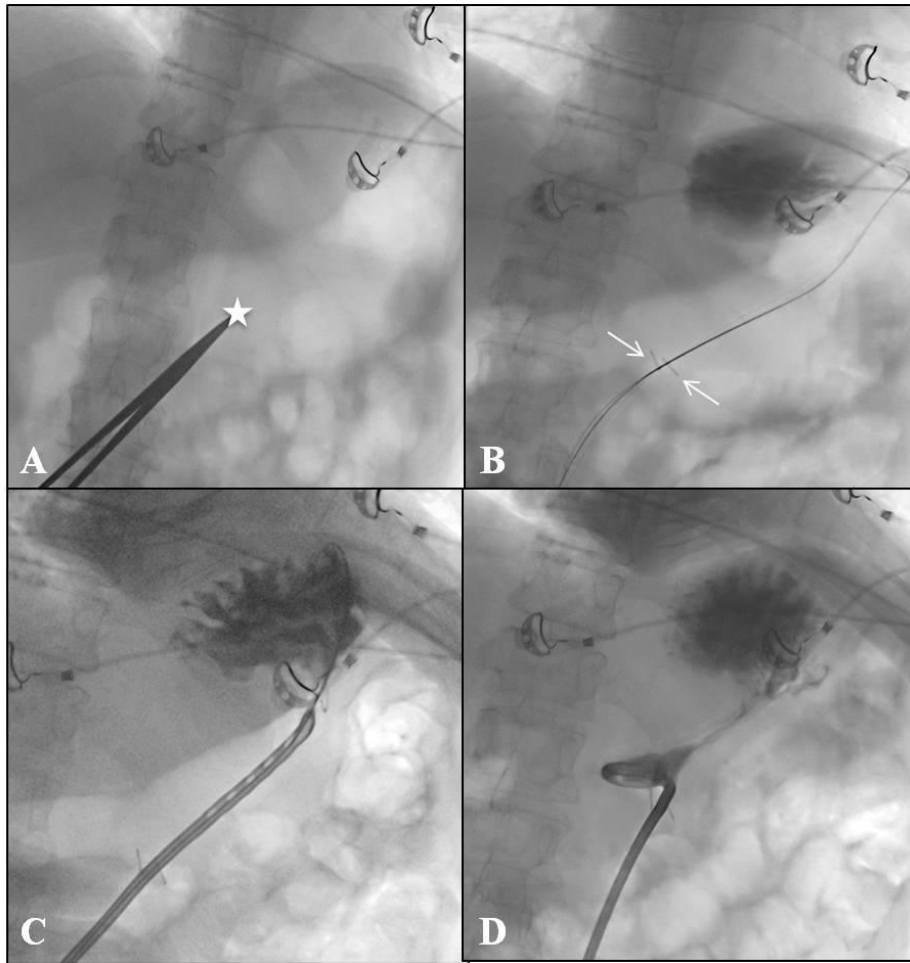


Figure 3: Gastropexy needle insertion to the stomach, which is inflated with a nasogastric catheter and distended, is indicated with portegue (white star) on the skin (A). After gastropexy was performed with two T fasteners (white arrows: T-fastener), 0.035-inch J-tip stiff guidewire was sent to the stomach lumen (B). The catheter was advanced over the guidewire (C), and the catheter was inserted into the gastric lumen and controlled with contrast media administration (D).

RESULTS

A total of 23 patients included in the study [6 male (26.1%), 17 female (73.9%)], and the mean age was 63.1 years (range: 22-90 years). The clinical pathologies causing swallowing dysfunction and requiring gastrostomy were investigated, and the most common pathology was found as head and neck malignancy (39.2%). Other pathologies were malignancies other than head and neck malignancies (26.1%), CVA (21.7%), and other neurological disorders (13%). PRG was performed for the first time in 19 patients, and existing gastrostomy catheter was changed in 4 patients. The technical success rate was 100%. Gastroesophageal reflux was observed in one patient, and existing gastrostomy was converted to the gastrojejunostomy by advancing

the catheter to the jejunum. Two patients had discharge at the catheter insertion site, and catheters were exchanged with larger diameter (16 Fr) catheters. Also, wound care and appropriate antibiotherapy were recommended to these two patients with signs of infection such as redness and swelling at the catheter insertion site. Two patients were admitted because of the obstruction of the catheter due to the enteral nutrition product, and the lack of adequate catheter care and the existing catheters were replaced with 16 Fr catheter. According to these data, 21.7% of the patients had minor complications. During the 30-day follow-up, three patients died due to PRG-independent causes. None of the patients had major complications such as procedure-related mortality, viscous perforation, or peritonitis.

DISCUSSION

Enteral nutrition should be the preferred method of feeding in patients with normal gastrointestinal system functions due to low morbidity and mortality rates⁴. The current approach is to initiate enteral nutrition within the first 24-48 hours in critically ill patients with no oral intake⁵. It has been reported in the literature that nutritional status improves as a result of enteral feeding in addition to maintaining intestinal physiology and barrier functions and decreasing morbidity rates⁶.

Enteral feeding is provided by tube, catheter, or stoma⁴. While nasogastric or orogastric tubes can be used in the short term, gastrostomy or gastrojejunostomy should be preferred for a feeding lasting more than four weeks⁷.

Gastrostomy is a method used for nutritional support in patients with head and neck cancer, neurological disorders such as CVA, ALS, MS, and esophageal dysmotility. It can also be used for decompression of chronic gastrointestinal obstructions and gastric motility disorders due to various reasons such as metastasis¹. Percutaneous gastrostomy methods are preferred to surgical gastrostomy because of the lack of general anesthesia, low mortality rates, practical and easy application⁸. In the literature, the success rate of PRG studies with large patient groups is reported to be 95-100% with major, minor complication rates and procedure-related mortality rate 0.5-6%, 2.9-15%, and 0-1.9%, respectively⁹⁻¹⁸. These results show that PRG is a safe and effective procedure. In our study, similar technical success rates were found, and minor complication rates were found to be slightly higher than the literature. This is thought to be because the majority of patients are terminal cancer patients and that catheter care is inadequate. Complication rates reported for surgical gastrostomy and PEG were 1-35% and 17-32%, respectively¹⁹⁻²⁵. Also, PRG is the method of choice in patients with respiratory dysfunction due to the fact PRG can be applied without anesthesia and in patients with hypopharyngeal or esophageal stenosis that cannot be passed by endoscope because almost all can easily be passed through with hydrophilic wires²⁶.

There are a few disadvantages to PRG. Catheters inserted with PRG are frequently occluded due to their small diameter. They are also dislodged more frequently than the mushroom-retained tubes used for PEG²⁷. Complications of this type were tried to be overcome by another radiological method known as an antegrade method in which

PEG and PRG were synthesized technically. In this method, unlike our method, a 10 mm sheath is sent to the stomach lumen with a stiff guide wire and the tip of the sheath is directed to the esophagus, and the guide wire in the sheath is advanced to the patient's mouth. Then the snare catheter is loaded into the sheath instead of the wire. With this snare catheter, a 20 Fr mushroom-retained gastrostomy tube is inserted antegrade into the stomach and fixed with a stabilizing disc. In a single-center study conducted by Ahmed et al. with 300 patients using this method, the success rate of the procedure was 98.4%, the minor complication rate in 30-day follow-up was 4.3%, and one patient was died due to procedure-related reasons. The only major complication recorded except procedure-related death was aspiration with a rate of 2%. The incidence of tube obstruction was 1%. 20 Fr mushroom-retained PEG tubes preventing tube dislocation and occlusion were important advantages of this method²⁸.

The use of T-fastener systems in PRG is already a matter of debate. T-fastener prevents peritoneal catheterization, peritoneal leakage, and migration of the catheter to the peritoneum according to the group of practitioners who use this system routinely²⁹. According to another group, gastropexy increases the risk of bleeding and may cause ischemia and necrosis of the skin³⁰. In the study of Dewald et al. catheter dislocation was observed in 41% of the patients at 1-week follow-up, but it was stated that the catheter could easily be re-inserted from the tract formed by gastropexy. In the same study, only two patients (2.8%) were reported to have deterioration in tract⁹. In the study of Bell et al. without gastropexy, this rate was 68%¹⁰. In our study, there was no deterioration in the tract in patients who underwent catheter revision.

Gastropexy is simple to practice and does not cause a longer procedure time. In a study of Dewald et al. comparing 1000 patients with and without gastropexy, the complication rate was found to be equal or less in patients who underwent gastropexy, and that gastropexy did not increase the risk of procedure complications^{9,12}. In a study by Moller et al. mortality rate was reported as 3.2%. This is one of the highest mortality rates in the literature. In this study, gastropexy was not performed, and 2 out of 3 patients were diagnosed with peritonitis or shifting of the catheter into the abdomen³¹. Thornton et al. compared patients with and without gastropexy and reported a major complication rate of 10% in patients without

gastropepy and recommended routine use of gastropepy²⁹. Therefore, we think that catheter placement is more effective and safer after routinely performing gastropepy with two T-fasteners in our interventional radiology department.

Timing of the removal of the gastropepy suture has rarely been reported in the literature. In the study of Lorentzen et al. sutures were removed ten days after the procedure. In our study, this period was seven days. There is no consensus on the number of gastropepies and there are different applications. In the study of Lorentzen et al., single T-fastener was used to hang the stomach wall to the abdominal wall during the procedure, and sutures were removed immediately. The balloon of PEG tubes was used instead of T-fasteners to hang the gastric wall for long-term gastropepy providing tract maturation¹⁸. In the study of Thornton et al. 4 gastropepies were routinely applied²⁹.

Limitations of our study include retrospective evaluation of patients, insufficient number of samples, and lack of long-term data on patients' nutritional status.

In conclusion, PRG has advantages such as being practical and also suitable in a large patient population, including the patient group whom endoscopic gastrostomy is not an option for due to hypopharyngeal or esophageal stenosis. PRG is an effective and safe procedure with lower complication rates than endoscopic and surgical gastrostomy⁹.

REFERENCES

- Covarrubias DA, O'Connor OJ, McDermott S, Arellano RS. Radiologic percutaneous gastrostomy: a review of potential complications and an approach to managing the unexpected outcome. *AJR Am J Roentgenol.* 2013;200(4):921-31.
- Bazarah SM, Al-Rawas M, Akbar H, Qari Y. Percutaneous gastrostomy and gastrojejunostomy: radiological and endoscopic approach. *Ann Saudi Med.* 2002;22:38-42.
- Galaski A, Peng WW, Ellis M, Darling P, Common A, Tucker E. Gastrostomy tube placement by radiological versus endoscopic methods in an acute care setting: A retrospective review of frequency, indications, complications, and outcomes. *Can J Gastroenterol.* 2009;23(2):109-114.
- Kozeniecki M, Fritzshall R. Enteral nutrition for adults in the hospital setting. *Nutr Clin Pract.* 2015;30:634-651.
- McClave SA, Taylor BE, Martindale R, et al. the Society of Critical Care Medicine and the American Society for Parenteral and Enteral Nutrition (2016), Guidelines for the Provision and Assessment of Nutrition Support Therapy in the Adult Critically Ill Patient. *JPEN J Parenter Enteral Nutr.* 2016;40:159-211.
- DiSario JA. Endoscopic approaches to enteral nutritional support. *Best Pract Res Clin Gastroenterol.* 2006;20:605-30.
- Pash E. Enteral Nutrition: Options for Short-Term Access. *Nutr Clin Pract.* 2018;33(2):170-176.
- Wollman B, D'Agostino HB. Percutaneous radiologic and endoscopic gastrostomy: a 3-year institutional analysis of procedure performance. *AJR Am J Roentgenol.* 1997;169:1551-1553.
- Dewald CL, Hiette PO, Sewall LE, Fredenberg PG, Palestrant AM. Percutaneous gastrostomy and gastrojejunostomy with gastropepy: experience in 701 procedures. *Radiology.* 1999;211:651-6.
- Bell SD, Carmody EA, Yeung EY, Thurston WA, Simons ME, Ho CS. Percutaneous gastrostomy and gastrojejunostomy: additional experience in 519 procedures. *Radiology.* 1995;194:817-20.
- De Baere T, Chapot R, Kuoch V, Chevallier P, Delille JP, Domenge C, et al. Percutaneous gastrostomy with fluoroscopic guidance: single-center experience in 500 consecutive cancer patients. *Radiology.* 1999;210:651.
- Ryan JM, Hahn PF, Boland GW, McDowell RK, Saini S, Mueller PR. Percutaneous gastrostomy with T fastener gastropepy: results of 316 consecutive procedures. *Radiology.* 1997;203:496-500.
- Qanadli SD, Barre O, Mesurole B, el Hajjam M, Mulot RO, Strumza P, et al. Percutaneous gastrostomy for enteral nutrition: long-term follow-up of 176 procedures. *Can Assoc Radiol J.* 1999;50:260-4.
- Hicks ME, Surratt RS, Picus D, Marx ME, Lang EV. Fluoroscopically guided percutaneous gastrostomy and gastroenterostomy: analysis of 158 consecutive cases. *Am J Roentgenol.* 1990;154:725-8.

15. Saini S, Mueller PR, Gaa J, Briggs SE, Hahn PF, Forman BH, et al. Percutaneous gastrostomy with gastropexy: experience in 125 patients. *Am J Roentgenol.*1990; 154:1003–6.
16. Deurloo EE, Schultze Kool LJ, Kroger R, van Coevorden F, Balm AJ. Percutaneous radiological gastrostomy in patients with head and neck cancer. *Eur J Surg Oncol.* 2001;27:94–7.
17. Giuliano AW, Yoon HC, Lomis NN, Miller FJ. Fluoroscopically guided percutaneous placement of large-bore gastrostomy and gastrojejunostomy tubes: review of 109 cases. *J Vasc Interv Radiol.*2000;11:239–46.
18. Lorentzen T, Nolsøe CP, Adamsen S. Percutaneous radiologic gastrostomy with simplified gastropexy technique under ultrasonographic and fluoroscopic guidance: experience in 154 patients. *Acta Radiol.* 2007;48(1):13-9.
19. Au FC. The Stamm gastrostomy: a sound procedure. *Am Surg* 1993;59:674–5.
20. VanSonnenberg E, Wittich GR. Percutaneous gastrostomy and gastroenterostomy. II. Clinical experience. *Am J Roentgenol.* 1986;146:577–80.
21. Linder J, Elias EG. Complications of operative and endoscopic gastrostomies. *Maryland Med J.* 1992;41:219–21.
22. Rosenzweig TB, Palestrant AM, Esplin CA, Gilsdorf RB. A method for radiologic-assisted gastrostomy when percutaneous endoscopic gastrostomy is contraindicated. *Am J Surg.* 1994;168:587–91.
23. Ho C-S, Yeung EY. Percutaneous gastrostomy and transgastric jejunostomy. *Am J Roentgenol.* 1992;158:251–7.
24. Calton WC, Martindale RG, Gooden SM. Complications of percutaneous endoscopic gastrostomy. *Mil Med.* 1992;157:358–60.
25. Petersen TI, Kruse A. Complication of percutaneous endoscopic gastrostomy. *Eur J Surg.* 1997;163:351–6.
26. Chio A, Galletti R, Finocchiaro C, et al. Percutaneous radiological gastrostomy: a safe and effective method of nutritional tube placement in advanced ALS. *J Neurol Neurosurg Psychiatry.* 2004;75:645–647.
27. Cosentini EP, Sautner T, Gnant M, Winkelbauer F, Teleky B, Jakesz R. Outcomes of surgical, percutaneous endoscopic, and percutaneous radiologic gastrostomies. *Arch Surg.* 1998;133(10):1076-83.
28. Ahmed O, Jilani D, Sheth S, Giger M, Funaki B. Radiologically Guided Placement of Mushroom-retained Gastrostomy Catheters: Long-term Outcomes of Use in 300 Patients at a Single Center. *Radiology.* 2015;276(2):588-96
29. Thornton FJ, Fotheringham T, Haslam PJ, et al. Percutaneous radiological gastrostomy with and without T-fastener gastropexy: a randomised comparison study. *Cardiovasc Intervent Radiol.* 2002;25:467–471
30. Lyon Sm, Pascoe DM. Percutaneous Gastrostomy and Gastrojejunostomy *Semin Interven Radiol.* 2004;21(3):181-9
31. Möller P, Lindberg CG, Zilling T. Gastrostomy by various techniques: evaluation of indications, outcome and complications. *Scand J Gastroenterol.* 1999;10:1050–4.