

Ocular parameters quantified by the swept-source optical coherence tomography in celiac disease

Çölyak hastalığında swept-source optik koherens tomografi ile ölçülen oküler parametreler

Arif Ülkü Yener¹, Muhammet Yener Akpınar², Evrim Karamanoğlu², Ferdane Pirinççi Sapmaz², Yaşar Nazlıgöl²

¹Department of Ophthalmology, Keçiören Training and Research Hospital, Ankara, Turkey

²Department of Gastroenterology, Keçiören Training and Research Hospital, Ankara, Turkey

Corresponding author: Arif Ülkü Yener, MD, Department of Ophthalmology, Keçiören Training and Research Hospital, Ankara, Turkey

E-mail: arifulkuyener@hotmail.com

Received/Accepted: August 14, 2020 /September 21, 2020

Conflict of interest: There is not a conflict of interest.

SUMMARY






Objective: To measure anterior and posterior segmental ocular parameters in patients with celiac disease using swept-source optical coherence tomography and compare with those of healthy subjects.

Method: Fourteen patients with celiac disease referred from the gastroenterology clinic and 14 control subjects selected from the individuals with minor complaints who admitted the ophthalmology outpatient clinic were included in the study. Mean and segmental retinal nerve fiber layer thickness in four quadrant, average and sectoral ganglion cell inner plexiform layer thickness in six quadrant, foveal and parafoveal vessel density in four quadrant, optic nerve head parameters, including rim area, disc area, horizontal cup-to-disc ratio, vertical cup-to-disc ratio, cup volume, and additionally superficial/deep foveal avascular zone areas, choroidal thickness, and central corneal thickness of patients and controls were quantified using swept-source optical coherence tomography.

Results: Among all the measurements, retinal nerve fiber layer in nasal quadrant and subfoveal choroid of patients were significantly thicker than those of controls. Nasal quadrant retinal nerve fiber layer thickness for patients and controls were $91.62 \pm 15.27 \mu\text{m}$ and $79.93 \pm 10.43 \mu\text{m}$, respectively ($P=0.02$). Choroidal thickness was $377.69 \pm 50.77 \mu\text{m}$ for patients and $310.93 \pm 95.13 \mu\text{m}$ for controls ($P=0.03$).

Conclusions: Even though celiac disease is primarily a disease of small intestine, this study demonstrated that the disorder can affect the eye as an extra intestinal involvement.

Keywords: Celiac disease; optical coherence tomography; choroidal thickness; retinal nerve fiber layer thickness

-  Arif Ülkü Yener
-  Muhammet Yener Akpınar
-  Evrim Karamanoğlu
-  Ferdane Pirinççi Sapmaz
-  Yaşar Nazlıgöl

ORCID IDs of the authors:

A.Ü.Y. 0000-0002-0039-0438

M.Y.A. 0000-0003-0903-4664

E.K. 0000-0001-8887-3428

F.P.S. 0000-0003-1278-110X

Y.N. 0000-0003-1926-4594

ÖZET

Amaç: Çölyak hastalarında swept-source optik koherens tomografi kullanarak ön ve arka segment göz parametrelerini ölçmek ve bunları sağlıklı kişilerinkilerle karşılaştırmak.

Yöntem: Gastroenteroloji kliniğinden sevk edilen 14 çölyak hastası ve ufak şikayetlerle göz polikliniğine müracaat eden hastalardan seçilen 14 sağlıklı kontrol çalışma kapsamına alındı. Hastaların ve kontrol grubunun ortalama ve dört kadranda retina sinir lifi tabakası kalınlığı, ortalama ve altı kadranda gangliyon hücre iç pleksiform tabakası kalınlığı, foveal ve fovea çevresi 4 kadranda damar yoğunluğu; rim alanı, disk alanı, yatay çukurluk/disk oranı, dikey çukurluk/disk

oranı ve çukurluk hacmi gibi optik sinir başı parametreleri ve ayrıca yüzeysel/derin foveal damarsız bölge alanı, koroid kalınlığı ve merkezi kornea kalınlığı swept-source optik koherens tomografi cihazı yardımıyla ölçüldü.

Bulgular: Bütün ölçüm sonuçları arasında hastalardaki nasal kadran retina sinir lifi ve fovea altı koroid kontrol grubundan anlamlı derecede daha kalındı. Hastaların ve kontrollerin nasal kadran retina sinir lifi tabakası kalınlığı sırasıyla $91.62 \pm 15.27 \mu\text{m}$ ve $79.93 \pm 10.43 \mu\text{m}$ idi ($P=0.02$). Hastalar için koroid kalınlığı $377.69 \pm 50.77 \mu\text{m}$, kontroller için $310.93 \pm 95 \mu\text{m}$ idi ($P=0.03$).

Sonuç: Çölyak, öncelikli olarak bir ince bağırsak hastalığı olsa da bu çalışma hastalığın bağırsak dışı bir tutulum yeri olarak gözü de etkileyebileceğini göstermiştir.

Anahtar sözcükler: Çölyak hastalığı, optik koherens tomografi, koroid kalınlığı, retina sinir lifi tabakası kalınlığı.

INTRODUCTION

Celiac disease (CD) is a gluten sensitive autoimmune disorder of small intestine that affects genetically predisposed individuals. Diarrhea, steatorrhea and malabsorption are the gastrointestinal originated classical symptoms. Half of the CD patients presents extraintestinal findings, such as anemia, osteoporosis, dermatitis and neurological problems¹⁻³. The clinical appearance of CD is related to having genetic and immunological factors with age of onset, extent of mucosal deterioration, dietary habits and sex⁴. CD is essentially diagnosed by the presence of predisposing genetic factor of human leukocyte antigen (HLA), positive biopsy and serological antibodies upon the diet with gluten. CD may present in different forms⁵. The classical form may occur at any age of life and is often characterized by crypt hyperplasia and villous atrophy. The atypical form is characterized by positive serology, limited abnormalities of small intestinal mucosa, but associated with extra intestinal manifestations, including osteoporosis, neuropathy and anemia. The latent form is defined by the presence of predisposing gene HLD-Q2 and HLD-Q8, normal intestinal mucosa and possible positive serology. In refractory form, usually after age 50 years, some patients initially respond to a gluten free diet and develop recurrent symptoms.

Gliadin peptides strongly bind to HLA, especially HLD-Q2 and HLD-Q8, expressed on antigen-presenting cells. Since gliadin peptides are resistant to gastrointestinal enzymes, they cause an inflammatory reaction that results in damage to intestinal mucosa and affect permeability⁶⁻¹⁰. CD is triggered by the ingestion of gliadin and other related prolamins in genetically susceptible subjects. Wheat, barley and rye induce CD¹¹⁻¹³. Although the diagnosis of CD can be made based on clinical and laboratory clues, histology of the proximal small intestinal mucosa is still the diagnostic gold standard and must always be performed. Marsh and Oberhuer classified the histopathology of intestinal mucosa in CD patients as 6-stage grading^{14,15}.

The aim of this study was to demonstrate whether the celiac disease affects the eye as a systemic autoimmune inflammatory disorder.

MATERIAL AND METHODS

Subjects

Patients with CD and controls were recruited in the study in accordance with the tenets of Declaration of Helsinki and written consents were obtained from all of the patients and controls. The study protocol was reviewed and approved by the Ethic Committee of Hospital before starting to study. Patients were between 20 and 62, control subjects were between 25 and 66 years of age. Fourteen CD patients were referred from the gastroenterology clinic and 14 healthy controls were selected from the individuals admitting to ophthalmology department for refraction examination or minor complaints. Control subjects were deemed to be normal if any previous history of systemic or ocular disease were absent or a normal appearance of retina and optic disc in clinical examination were present. A randomly selected eye of patients and controls were assessed in the study. Both normal individuals and patients eligible for the study underwent a complete ophthalmologic examination consisting of the best corrected visual acuity level, slit-lamp biomicroscopy and dilated funduscopy.

Exclusion criteria were history or clinical evidence of retinal disease, presence of macular edema, diabetic retinopathy, previous ocular surgery or laser photocoagulation and medications known to affect retina or choroid. Eyes with quality images less than 50 due to segmentation algorithm failures, motion artifacts or poorly focusing were excluded from the analysis. The data of patients and controls, including ages, spherical equivalent refractive error, best-corrected visual acuity, gonioscopy, slit-lamp microscopy, intraocular pressure with Goldmann applanation tonometer were recorded. Peripapillary retinal nerve fiber layer (RNFL), macular ganglion cell inner plexiform layer, optic nerve head parameters, central corneal thickness, choroidal thickness (CT), vessel density in macula,

as well as deep and superficial foveal avascular zone areas were quantified by the swept-source optical coherence tomography (OCT).

Optical Coherence Tomography

Images were obtained through the undilated pupils using swept-source OCT. This deep range imaging OCT (DRI OCT, Topcon, Tokyo, Japan) device uses a swept laser with a wavelength of 1050 nm and the wide angle (12x9 mm) scan centered on the posterior pole. This longer wavelength allows a deeper penetration into the tissue and it is therefore possible to obtain images of the macula and optic nerve head in a single scan. The 12x9 mm scan comprises 256 B-scans, each consists of 512 A-scans. For a wide angle scan, SS-OCT obtains 100.000 A-scans per second with an axial resolution of 8 μm and lateral resolution of 20 μm in tissue. All anterior and posterior segmental parameters were measured automatically using the built-in segmentation software algorithms.

To measure average or sectoral ganglion cell inner plexiform layer thickness, a circle of 6 mm in diameter is automatically centered on the fovea. Ganglion cell inner plexiform layer is the distance from the interface between the nerve fiber layer and ganglion cell layer to the interface between the inner plexiform layer and inner nuclear layer. Nerve fiber layer is the thickness between the internal limiting membrane and the interface between the nerve fiber layer and ganglion cell layer. For the measurements of RNFL and optic nerve head parameters, a peripapillary circle of 3.4 mm in diameter is automatically centered on the optic disc. Topcon swept-source OCT is equipped with the anterior segment analysis mode, which was used in this study for corneal imaging and central corneal thickness.

OCT angiography allows visualisation of superficial capillary plexus, deep capillary plexus and choriocapillaris. The superficial network extends from 3 μm below the internal limiting membrane to 15 μm below the inner plexiform layer. The deep capillary network is the distance from 15 to 70 μm beneath the inner plexiform layer. In this study, OCT images of the superficial and deep capillary networks were generated separately using the automated software algorithm of the machine. The borderline of the foveal avascular zone was outlined manually and the foveal avascular zone area was then calculated by the software. Vascular density is defined as the percentage of the area occupied by the vessels within the total measured area. The percentages of vessels calculated in parafoveal superior, inferior,

nasal and temporal sectors and at the fovea center are automatically determined. The inner and outer rings with a diameter of 1 and 2.5 mm around the fovea are considered for evaluation. Angio analytics software evaluates the relative density of flow as a percentage of the total area.

Statistical Analysis

Statistical analysis was performed using the statistical package for the social science, SPSS version 22 (SPSS, Inc., Chicago, IL). The normality of distribution of the quantitative variables was determined with the Shapiro-Wilk test. For distributed variables and median, mean and standard deviation were used as descriptive statistics. To compare variables between two independent groups, the Mann-Whitney U test was used for non-normally distributed variables. Normally distributed average or quadrant RNFL thickness, average or sectoral ganglion cell inner plexiform layer thickness, optic nerve head parameters, CT, central corneal thickness, foveal and parafoveal vessel density, superficial and deep foveal avascular zone areas were compared between the patients with CD and control eyes using the independent sample t test. $P < 0.05$ was considered statistically significant.

RESULTS

A randomly selected eye of patients and controls were enrolled in the study. The mean ages of 14 patients with CD (6 males and 8 females) and 14 controls (6 males and 8 females) were 40.8 ± 10.9 and 45.4 ± 12.2 , respectively, ($P=0.32$). Both the patients and controls had no systemic disease, including diabetes mellitus, hypertension and cardiovascular disease. Patients did not use ocular anti-hypertensive medication or any other drug affecting the eye at the time of OCT imaging. In this study, OCT images of the neural and vascular structures and corneal thickness were generated separately by the swept-source OCT. Among the ocular parameters, nasal quadrant RNFL in patients was significantly thicker than controls. (91.62 ± 15.27 μm and 79.93 ± 10.43 μm , respectively, $P=0.02$) (Table 1). Choroidal thickness in patients was significantly greater than healthy participants (377.69 ± 50.77 μm vs 310.93 ± 95.13 μm , $P=0.03$) (Table 2). Average and sectoral ganglion cell inner plexiform layer thickness did not differ between the groups (Table 3). Figure 1 illustrates the mean, four quadrant and clock-hour RNFL thickness of a CD patient, whereas the CT is demonstrated in Figure 2.

Table 1: Retinal nerve fiber layer and optic nerve head parameters of patients and controls

	Mean±SD (μm)	Mean±SD (μm)		95% Confidence Interval	
RNFL	Patient eye	Control eye	P	Lower limit	Upper limit
Average	113.62±9.44	109.79±11.08	0.34	-4.36	12.02
Superior	138.62±11.43	135.86±15.33	0.60	-8.03	13.54
Inferior	143.23±16.52	135.21±38.72	0.49	-15.92	31.95
Nasal	91.62±15.27	79.93±10.43	0.02	1.38	21.98
Temporal	78.85±14.49	81.50±11.00	0.59	-12.80	7.49
ONH					
Rim area	1.46±0.47	1.45±0.43	0.96	-0.35	0.36
Disc area	2.10±0.35	2.11±0.33	0.96	-0.27	0.26
HCDR	0.49±0.24	0.59±0.18	0.24	-0.26	0.07
VCDR	0.47±0.22	0.55±0.13	0.24	-0.22	0.06
Volume	0.14±0.14	0.13±0.14	0.80	-0.10	0.12

SD: Standard deviation, RNFL: retinal nerve fiber layer, ONH: optic nerve head

HCDR: horizontal cup-to-disc ratio, VCDR: vertical cup-to-disc ratio

Table 2: Posterior segment vascular parameters and central corneal thickness

	Mean±SD	Mean±SD		95% Confidence Interval	
FAZ area	Patient eye	Control eye	P	Lower limit	Upper limit
Superficial (μm ²)	307.82±139.87	297.95±136.37	0.85	-99.65	119.38
Deep (μm ²)	453.61±262.62	439.47±227.31	0.88	-180.13	208.41
Vessel density					
Fovea (%)	18.80±4.64	20.71±3.73	0.24	-5.24	1.42
Superior (%)	49.15±2.96	49.49±2.88	0.76	-2.66	1.97
Inferior (%)	49.24±3.38	49.11±2.16	0.91	-2.46	2.72
Nasal (%)	44.54±3.08	43.92±4.76	0.69	-2.56	3.82
Temporal (%)	47.62±1.81	46.51±2.40	0.18	-0.58	2.81
CT (μm)	377.69±50.79	310.93±95.13	0.03	5.60	127.92
CCT (μm)	517.33±19.02	526.15±31.20	0.40	-30.43	12.79

SD: standard deviation, FAZ: foveal avascular zone, CT: choroidal thickness, CCT: central corneal thickness

Table 3: Ganglion cell inner plexiform layer thickness in celiac patients and controls

	Mean±SD (μm)	Mean±SD (μm)		95% Confidence Interval	
GCIPL	Patient eye	Control eye	P	Lower limit	Upper limit
Superior	71.25±4.18	71.57±6.23	0.87	-4.58	3.90
Superonasal	74.69±4.32	70.07±4.87	0.44	-5.04	2.28
Inferonasal	74.69±3.66	75.21±3.94	0.73	-3.54	2.50
Inferior	70.69±3.51	70.95±6.14	0.90	-4.33	3.85
Inferotemporal	74.62±3.88	75.21±4.50	0.71	-3.94	2.75
Superotemporal	72.77±3.37	73.42±5.33	0.70	-4.22	2.90
Average	73.31±3.42	73.57±6.23	0.86	-3.46	2.93

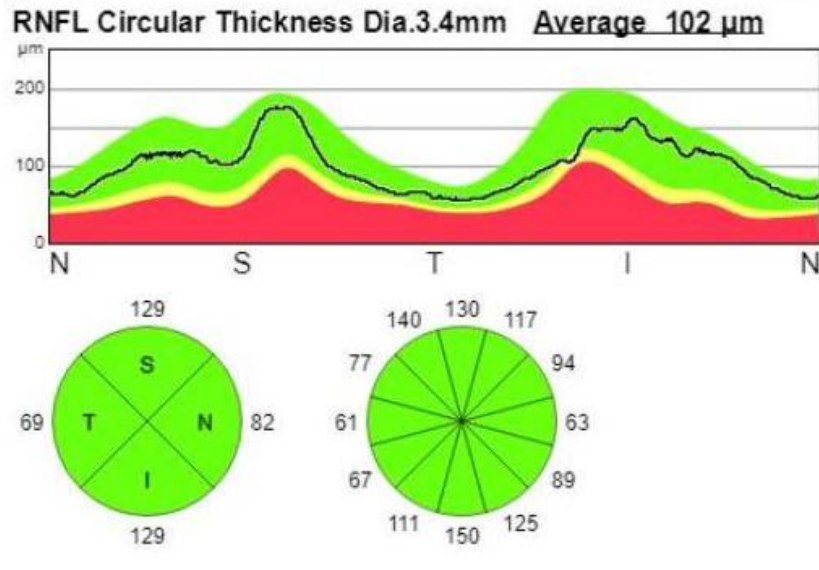


Figure 1.

Figure 1: Average, quadrant and clock-hour retinal nerve fiber layer thickness measured by swept-source optical coherence tomography

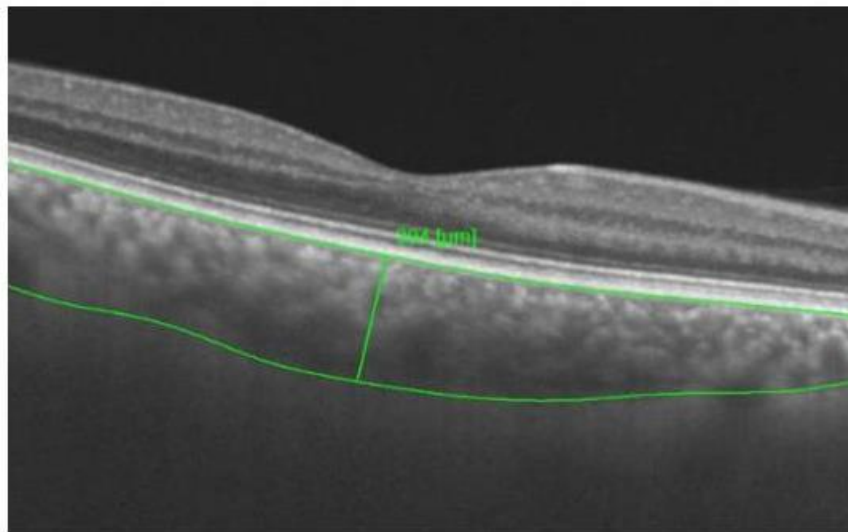


Figure 2.

Figure 2: Choroidal thickness with an automatically delineated line of choroid-sclera junction by software algorithm of device

DISCUSSION

Ophthalmic symptoms are associated with lower vitamin A, vitamin D, and calcium levels due to absorbing malnutrition, and are rarely caused by autoimmunity of the CD¹⁶. Malnutrition might cause retinopathy, cataract, dry eye and pseudotumor cerebri. Orbital myositis, uveitis, thyroiditis with orbitopathy and brain occipital calcification are the autoimmune associated manifestations¹⁷. Malnutrition retinopathy is characterized by yellowish to white punctate lesions in peripheral retina and changes in electroretinogram. Vitamin A deficiency also can lead to dry eye and faulty electroretinogram co-existing with night blindness. Malabsorption caused by chronic diarrhea interferes with the absorption of calcium and the resulting hypocalcemia causes the development of cataract. Osmotic alteration between the lens and aqueous humor due to dehydration and low level of calcium in aqueous humor change the permeability of lens epithelium leading to lens opacification.

A few case reports have determined the relation between the pseudotumor cerebri and low level of vitamin A. The clinical picture is characterized by the presence of papilledema and absence of other causes which elevates the intracranial pressure. In patients with orbital myositis, high level of anti-gliadin antibodies were found. Orbital myositis is probably related to eosinophilic granulomatous infiltration. The disease affecting only one extraocular muscle and seen more commonly in women develops diplopia, pain with eye movements and exophthalmos. In CD patients with low vision, cortical calcification in occipital region was reported¹⁸. Folic acid deficiency or immune complex associated with endothelial inflammation may be the triggering factors. However, the pathophysiology of this alteration has not yet been definitely determined.

Loss of Goblet cells and metaplasia of squamous cells in conjunctiva can lead to dry eye in patients with vitamin A deficiency. Uzel et al¹⁹ demonstrated that tear film break-up time and Schirmer test results were significantly lower and Goblet cell count remarkably diminished in CD. We did not test the tear film break-up time and Schirmer in our study but measured the corneal thickness by OCT. Primary Sjögren's syndrome is extremely rare in disease²⁰.

There are very few reports of posterior segment thickness measurements in CD-related literature. Karatepe et al²¹ defined a thinner RNFL in the eyes of children with CD. In contrast to their study, significantly thicker RNFL only in nasal quadrant was identified by SS-OCT in the present study. The

difference between RNFL thickness in two studies may result from the age and size of the sample populations. Characteristics of the OCT instruments used in the studies may be another important factor. In a study conducted by Bölükbaşı et al²², consistent with our report, CT was significantly higher in celiac group than in healthy controls. In the current study, higher thickness both in nasal quadrant of RNFL and choroid are likely associated with the granulomatous infiltration in tissues due to systemic inflammatory nature of CD.

Variations in some ocular parameters, corneal thickness and CT have previously been reported in systemic autoimmune diseases, such as rheumatoid arthritis. Corneal thickness may change in CD due to alterations in structure of the tear film layer because dry eye is one of the most common ocular symptoms. The choroidal thickness may be expected to vary depending on eosinophilic granulomatous infiltration and vascular events in choroid and deep retinal layer. The chronic process of this long-term inflammatory disease might allow the variations in anterior and posterior segments of the eye. Therefore, certain ocular parameters were measured using swept-source OCT and compared with those of normal eyes. To our knowledge, our study was the first in terms of scope. In the current study, central corneal thickness, retinal nerve fiber layer thickness, optic nerve head parameters, ganglion cell inner plexiform layer thickness, choroidal thickness, foveal avascular zone area and macular vessel density were quantified and analyzed.

This study presents certain limitations. Our study population included only 14 CD patients and 14 control subjects. Patients were entirely normal and any of the ocular manifestations, including uveitis, episcleritis, scleritis or chorioretinitis were not present in patients. Thus, the effects of these entities on ocular parameters were not researched. The small sample size in this study prevented further subgroup analysis of CD patients with different disease severities. Although they are important factors, age and sex were not analysed in the study due to small sample size. Finally, since this is a cross-sectional study, it is difficult to comment on the effect of CD in structural ophthalmic changes. Longitudinal studies will help understand the relationships between CD and ocular manifestations.

Acknowledgments: No funding support was used in the present study.

Conflict of interest: The authors inform that they have no affiliations with or involvement in any organization or entity with any financial interest or

non-financial interest in the subject matter or materials discussed in this manuscript.

REFERENCES

1. Rampertab SD, Pooran R, Brar P, Singh P, Green PH. Trends in the presentation of celiac disease. *Am J Med.* 2006;119:355.e9-355.
2. Kneepkens CM, vonBlomberg BM. Clinical practice: celiac disease. *Eur J of Pediatr.* 2012;171:1011-21.
3. Pietz G, De R, Hedberg M. Immunopathology of childhood celiac disease-key role of intestinal epithelial cells. *PLoS One.* 2017;12:e0185025.
4. Gujral N, Freeman HJ, Thomson AB. Celiac disease: prevalence, diagnosis, pathogenesis and treatment. *World J Gastroenterol.* 2012;18:6036-59.
5. Ferguson A, Arranz E, O'Mahony S. Clinical and pathological spectrum of celiac disease-active, silent, latent, potential. *Gut.* 1993;34:150-1.
6. Sollid LM. Molecular basis of celiac disease. *Ann Rev Immunol.* 2000;18:53-81.
7. Cukrowska B, Sowinska A, Bierla JB, Czarnowska E, Rybak A, Grzybowska-Chlebowczyk U. Intestinal epithelium, intraepithelial lymphocytes and the gut microbiota-key players in the pathogenesis of celiac disease. *World J Gastroenterol.* 2017;23:7505-18.
8. Sollid LM. Celiac disease: dissecting a complex inflammatory disorder. *Nat Rev Immunol.* 2002;2:647-55.
9. vanBergen J, Mulder CJ, Mearin ML, Koning F. Local communication among mucosal immune cells in patients with celiac disease. *Gastroenterology.* 2015;148:1187-94.
10. Sollid LM, Qiao SW, Anderson RP, Gianfrani C, Koning F. Nomenclature and listing of celiac disease relevant gluten T-cell epitopes restricted by HLA-DQ molecules. *Immunogenetics.* 2012;64:455-60.
11. Meresse B, Ripoche J, Heyman M, Cerf-Bensussan N. Celiac disease: from oral tolerance to intestinal inflammation, autoimmunity and lymphomagenesis. *Mucosal Immunol.* 2009;2:8-23.
12. Kupper C. Dietary guidelines and implementation for celiac disease. *Gastroenterology.* 2005;128:121-7.
13. Shan L, Molberg O, Parrot I, Hausch F, Filiz F, Gray GM, et al. Structural basis for gluten intolerance in celiac sprue. *Science.* 2002;297:2275-9.
14. Marsh MN. Gluten, major histocompatibility complex and the small intestine. A molecular and immunobiologic approach to the spectrum of gluten sensitivity (celiac sprue). *Gastroenterology.* 1992;102:330-54.
15. Oberhuber G, Granditsch G, Vogelsang H. The histopathology of celiac disease: time for a standardized report scheme for pathologists. *Eur J Gastroenterol Hepatol.* 1999;11:1185-94.
16. dosSantosMartins TG, de AzevedoCosta ALF, Oyamada MK, Schor P, Sipahi AM. Ophthalmologic manifestations of celiac disease. *Int J Ophthalmol.* 2016;9:159-62.
17. Mollazadegan K, Kugelberg M, Tallstedt L, Ludvigsson JF. Increased risk of uveitis in celiac disease: a nationwide cohort study. *Br J Ophthalmol.* 2012;96:857-61.
18. Gao Z, Varma DD, Patel S, Lee A, Chen C. Visual loss secondary to bioccipital calcifications associated with celiac disease. *Neuro-ophthalmology.* 2015;39:277-80.
19. Uzel MM, Citirik M, Kekilli M, Çiçek P. Local ocular surface parameters in patients with systemic celiac disease. *Eye (Lond).* 2017;31:1093-8.
20. Erbasan F, Çoban T, Karasu U, Çekin Y, Yeşil B, Çekin AH, et al. Primary Sjögren's syndrome in patients with celiac disease. *Turk J Med Sci.* 2017;47:430-4.
21. Karatepe Hashas AS, Altunel O, Sevinc E, Duru N, Alabay B, Torun YA. The eyes of children with celiac disease. *AAPOS.* 2017;21:48-51.
22. Bölükbaşı S, Erden B, Çakır A, Bayat AH, Elçioğlu MN, Yurттаşer Ocak S, et al. Pachychoroid pigment epitheliopathy and choroida thickness changes in celiac disease. *J Ophthalmol.* 2019;13:6924191.