

The deep femoral artery and branching variations: a case report

Arteria profunda femoris ve dallarının varyasyonu: olgu sunumu

Vedat Sabancıoğulları, Mehmet İlkey Koşar, Ekrem Ölçü, Mehmet Çimen

Department of Anatomy (Assist. Prof. V. Sabancıoğulları, MD; Assist. Prof. M. İ. Koşar, MD; Prof. M. Çimen, PhD), Cumhuriyet University School of Medicine, TR-58140, Sivas; and Department of Radiology (E. Ölçü, MD, Specialist in Radiology) Afşin State Hospital, TR-46500 Kahramanmaraş

Abstract

The deep femoral artery is the major branch of the femoral artery. Its branches and branching show various variations. For this reason, an extensive knowledge about the anatomy of the deep femoral artery is indeed important in vascular reconstructive surgery involving the groin. In this investigation, a case with variations of the deep femoral artery origin and branching has been presented. The case was a 45-year old male cadaver and the arterial variation was noted during routine dissection. The right and left origins of the deep femoral artery varied. When the midpoint of the inguinal ligament was taken as a reference, the right artery originated at 5.58 cm and the left artery at 2.22 cm. In the left, the ascending branch and transverse branch of the lateral circumflex femoral artery originated. At a joint root and the descending branch originated directly at the deep femoral artery. Also in the left, it was observed that there were eight perforating arteries.

Keywords: Deep femoral artery, anatomic variation, cadaver

Özet

Arteria profunda femoris, arteria femoralis'in uyluğu besleyen en büyük dalıdır. Bu damarın dalları ve a. femoralis'ten çıkış seviyesi çeşitli varyasyonlar gösterir. Bu nedenle damar anatomisinin ve varyasyonlarının tam olarak bilinmesi özellikle kasık bölgesini içeren vasküler rekonstruktif cerrahilerde önemlidir. Bu çalışmada a. profunda femoris'in çıkış yeri ve dallanmasına ait varyasyon gösteren bir olgu sunuldu. Olgu 45 yaşında bir erkek kadavra olup arter varyasyonu rutin disseksiyon sırasında tesbit edildi. A. profunda femoris'lerin sağ ve solda çıkış seviyeleri birbirinden farklıydı. Ligamentum inguinale'nin orta noktası referans olarak alındığında sağ arter 5,58 cm, sol arter 2,22 cm.' den ayrılıyordu. Solda a. circumflexa femoris lateralis'e ait ramus ascendens ve ramus transversus ortak bir kökle ramus descendens ise direkt olarak a. profunda femoris'ten ayrılmaktaydı. Yine solda aa. perforantes sayısının da sekiz adet olduğu görüldü.

Anahtar sözcükler: Arteria profunda femoris, anatomik varyasyon, kadavra

Geliş tarihi/Received: March 10, 2009; **Kabul tarihi/Accepted:** April 23, 2009

Corresponding author:

Dr. Vedat Sabancıoğulları, Anatomi Anabilim Dalı, Cumhuriyet Üniversitesi Tıp Fakültesi, TR-58140 Sivas. Email: sabanci@cumhuriyet.edu.tr

Introduction

The deep femoral artery originates from the femoral artery, 1-5 cm below the inguinal ligament. Soon after its origin, it presents the lateral circumflex artery. Later on, it displays 5 perforating branches and descends down the Adductor longus, terminating in the ¼ distal of the thigh after branching [1-4].

Both the deep femoral artery and its branches display many variations in origin and number [5-8]. Knowing these variations thoroughly is important in vascular reconstructive surgery, particularly those involving the groin region [9].

Furthermore, it is essential to know the origin of the deep femoral artery in surgical interventions made for the treatment of atherosclerosis seen in the lower extremity arteries in the deep femoral artery cases with deep femoral embolism [10]. For this reason, it has been attempted to present the rare variation of this artery with clinical importance.

Case

Examined case had been observed during the routine dissection of the front region of the thigh on a cadaver that found in the Department of Anatomy Laboratory. In the dissection of both femoral triangles of a 45-year old male cadaver, it was determined that the origins of deep femoral arteries were at different levels and there were variations at the left deep femoral artery. These variations showed that the descending branch of the lateral circumflex artery originated directly from the deep femoral artery and there were 8 perforating arteries including the terminal branch. While the right deep femoral artery originated at a distance of 5.6 cm to the midpoint of the inguinal ligament, the distance of the left deep femoral artery to the midpoint of the inguinal ligament was measured as 2.2 cm. The direction of the deep femoral artery in the right was posteromedial but in the left it originated from the lateral of the femoral artery. While there were 3 perforating branches in the right, 8 branches including the terminal branch of the deep femoral artery were determined in the left (Figures 1 and 2).

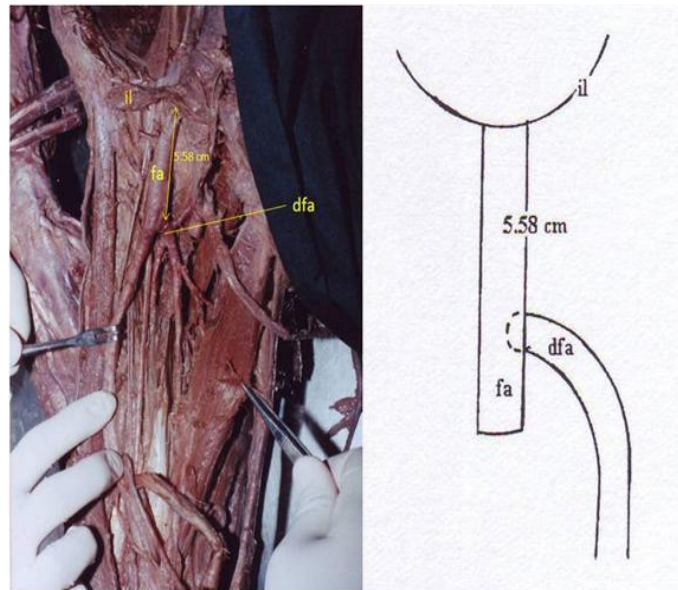


Fig. 1 A (Cadaver), B (Diagram). Posteromedial origin of the right deep femoral artery from the femoral artery. il: inguinal ligament, fa: femoral artery, dfa: deep femoral artery.

Discussion

It is of great importance to know the originating point of the deep femoral artery from the femoral artery and consider separation point as 1 cm above the arteriotomy incision in the embolectomy procedure in order to treat the deep femoral arterial embolism during the procedure of thromboendarterectomy applied in the lower extremity frequently seen in atherosclerosis [10-12].

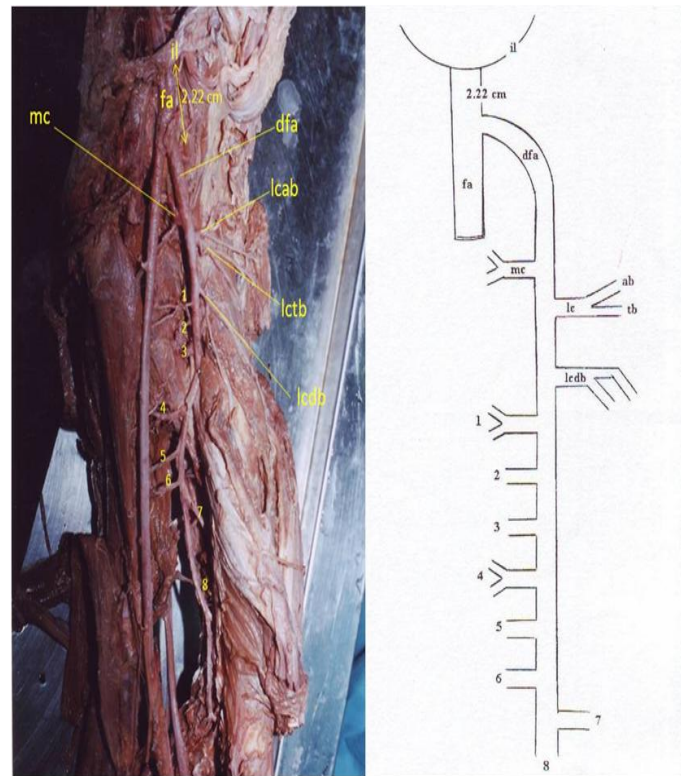


Fig. 2 A (Cadaver), B (Diagram). Lateral origin of the left deep femoral artery from the femoral artery 1-8 perforating arteries and the direct origin of the descending branch of the lateral circumflex femoral artery from the deep femoral artery. il: inguinal ligament, fa: femoral artery, dfa: deep femoral artery, mc: medial circumflex femoral artery, lcab: ascending branch of lateral circumflex femoral artery, lctb: tranverse branch of lateral circumflex femoral artery, lcdb: descending branch of the lateral circumflex femoral artery, 1-8: perforating arteries.

Various investigations have been made to determine the originating place of this point. In all of these, the distance of the originating point of the deep femoral artery from the femoral artery to the midpoint of the inguinal ligament has been taken as the main criterion [9, 13-16]. It was reported that the distance of the originating point of the deep femoral artery from the femoral artery to the inguinal ligament was measured as 4.4 cm [9], 3.5 cm [4], 4.7 cm [16], 3.7 cm [13], and 4.1 cm [15]. In our case, the distance of the originating point to the midpoint of the inguinal ligament was found to be 5.6 cm in the right and 2.2 cm in the left.

The direction of the origin of the deep femoral artery is also important in catheter application, in making flaps with pedicles in reconstructive surgery and by-pass procedures made to supply the lower extremity [11]. The direction of origin encountered in the investigation of Siddharth et al. [9] is posterolateral (40%). It is known that the most frequent direction of origin from the lateral as shown by Snell [3] and Dere [14] and from the posterior as demonstrated by De Graf and Fox [17], Prives et al. [18], and Tanyeli et al. [16]. The direction of origin of the deep femoral arteries in the right from the posteromedial and in left from the later in our case were found to be in conformity with the values of 9% and 12%, respectively, as reported by Siddharth et al. [9]. The direct origin of the descending branch of the lateral circumflex femoral artery in the left from the deep femoral artery is evaluated by some authors to be rare [4] and as a minor variation by others [7].

It is known that the number of perforating arteries reported by various authors generally vary among 3 [1, 4], 4 [3], and 4-5 [9]. Ekinçi et al. [15] determined 8 perforating

branches in one case. In our case, these were determined to be 3 in the right and 8 in the left. From this standpoint, the number of perforating branches in the right has been found to be normal but those in left considered to be rare as those reported the by Ekinçi et al. [15].

In conclusion, it is known that the deep femoral artery and its branches show many variations. It is considered that knowledge of these variations will provide facilities in vascular surgery and angiography applications and may reduce the complications.

References

1. Arıncı K, Elhan A. *Anatomi 2. Cilt*. Ankara: Güneş Kitabevi Ltd. Şti. 1997, sf 90-2.
2. Moore KL, Dalley AF. *Clinically Oriented Anatomy*. Fifth Edition. Philadelphia, PA, USA: Lippincot Williams and Wilkins. 2006; pp 603-5.
3. Snell RS. *Clinical Anatomy For Medical Students*. Fourth Edition, London, UK: Churchill Livingstone. 1992; pp 604-7.
4. Standring S, Ellis H, CJ Healy Jhonson D, Williams A. *Gray's Anatomy*. Thirty Ninth Edition. London, UK: Churchill Livingstone. 2005. pp 1450-1452, 1469.
5. Bilgiç S, Şahin B. Rare arterial variation: a common trunk from the external iliac artery for the obturator, inferior epigastric and profunda femoris arteries. *Surg Radiol Anat* 1997; 19: 45-7.
6. Şahin B, Bilgiç S. Two rare arterial variations of the deep femoral artery in the newborn. *Surg Radiol Anat* 1998; 20: 233-5.
7. Williams GD, Martin CH, McIntire LR. Origin of the deep and circumflex group of arteries. *Anat Rec* 1934; 60: 189-96.
8. Yıldırım M, Şahinoğlu K, Peştemalcı T. A. circumflexa femoris medialis ve a. circumflexa femoris lateralis'in orijin varyasyonları. *Morfoloji Dergisi* 1996; 4: 51-5.
9. Siddharth P, Smith NL, Mason RA, Giron F. Variational anatomy of the deep femoral artery. *Anat Rec* 1985; 212: 206-9.
10. Bozer YA, Güray İİ. *Damar Hastalıkları ve Cerrahisi*, Ankara: Hacettepe Üniversitesi Yayınları. 1984.
11. Değerli Ü. *Genel Cerrahi*, İstanbul: Bayda. 1983.
12. Linder HH. *Clinical Anatomy*. New York, NY, USA: Prentice Hall International Inc. 1989.
13. Başaloğlu H, Korman E, Arman C, Buldan Z. Arteria femoralis'in derin dallarının morfolojik olarak araştırılması. *Dokuz Eylül Üniversitesi Tıp Fakültesi Dergisi* 1995; 9: 39-48.
14. Dere F. *Anatomi Atlası ve Ders Kitabı*, Beşinci Baskı. Adana: Nobel Tıp Kitapevi. 1999; sf 427.
15. Ekinçi N, Unur E, Ülger H. Arteria femoralis ile arteria profunda femoris ve dallarının varyasyonları. *Erciyes Tıp Dergisi*. 1993; 15: 396-9.
16. Tanyeli E, Müftüoğlu A, Ertem AD, Özkuş K, Peştemalcı T. A. profunda femoris'in çıkış noktasının topometrik tanımı ve varyasyonları. *Cerrahpaşa Tıp Fak Der.* 1994; 25: 645-50.
17. De Graaf VMK, Fox IS. *Concepts of Human Anatomy and Physiology*, Second Edition. Iowa, USA: WCB Publishers. 1989.
18. Prives M, Lysenkow N, Bushkovich V. *Human Anatomy, Volume II*. Third Printing. Moscow, Russia: Mir Publishers. 1989.