

*Case report-Olgu sunumu*

## **Difficulties in evaluation of late presenting blunt diaphragmatic rupture: A case report**

*Geç dönemde ortaya çıkan künt diafragma rüptürünün değerlendirme zorlukları: Olgu sunumu*

**Mertay Boran, Ertay Boran, Sevim Üstek**

Department of Thoracic Surgery (M. Boran, MD), Department of General Surgery (S. Üstek, MD), Çankırı State Hospital, TR-18100 Çankırı, Department of Anesthesiology and Reanimation (E. Boran, MD), İzmir Atatürk Training and Research Hospital, TR-35100 İzmir

### **Abstract**

Blunt diaphragmatic rupture is difficult to diagnose in the absence of visceral injury or herniation. Diagnosis may be delayed as long as several days and even years. Because of late presentation, trauma can be forgotten and diaphragmatic injury can be omitted. Here, we report a case of diaphragmatic rupture diagnosed 7 months after the blunt trauma in a patient with chest pain complaint. Patient was managed with a thoracotomy and defect was closed primarily. The diagnosis of late diaphragmatic rupture should always be remembered in any patient with blunt trauma history.

**Key words:** Hernia, diaphragma, trauma, thoracic injuries

### **Özet**

Visseral hasar veya herniasyon yokluğunda künt diafragma rüptürünün tanısı zor olabilir. Tanı birkaç gün hatta yıllar boyunca gecikebilir. Burada, göğüs ağrısı şikayeti olan bir hastada, künt travmadan 7 ay sonra tanısı konulan bir diafragma rüptürü vakasını bildirmekteyiz. Hasta torakotomi ile tedavi edildi ve defektler primer kapatıldı. Geç diafragmatik rüptür tanısı künt travma hikayesi olan her hastada hatırlanmalıdır.

**Anahtar sözcükler:** Fıtık, diyafragma, travma, torasik yaralanmalar

**Geliş tarihi/Received:** April 8 2010; **Kabul tarihi/Accepted:** June 18 2010

### **Corresponding Adress:**

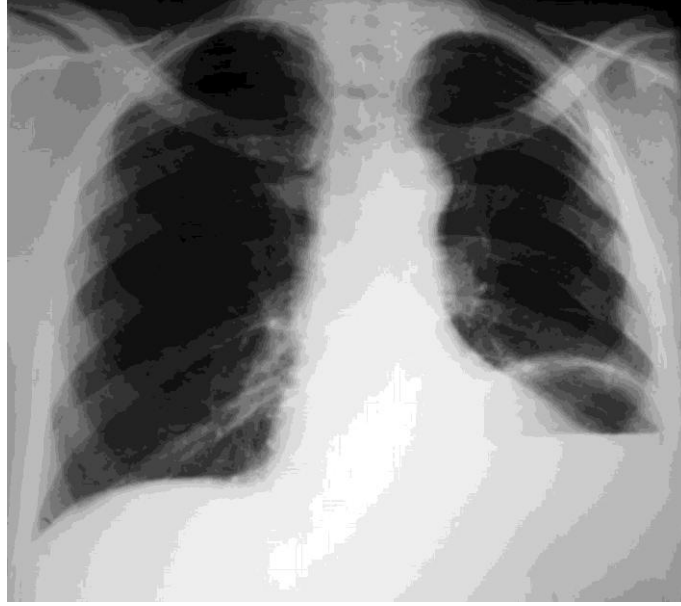
Dr. Mertay Boran, Göğüs Cerrahisi Kliniği, Çankırı Devlet Hastanesi TR-18100 Çankırı, E-mail: mertayboran@yahoo.com

### **Introduction**

Post traumatic diaphragmatic hernia is a special lesion that may be omitted. Blunt diaphragmatic rupture (BDR) is difficult to diagnose in the absence of visceral injury or herniation [1]. Diagnoses may be delayed as long as several days and even years and only be made after a complication in up to %14.6 of BDR cases [2, 3]. The reported incidence of acute diaphragmatic rupture is present in 0.8-5.8 % of blunt traumas, while the precise incidence remains unknown because of asymptomatic cases. [3-5] We report a case of late presenting diaphragmatic rupture due to blunt trauma diagnosed 7 months after the blunt trauma. Difficulties in BDR evaluation are also discussed in this report.

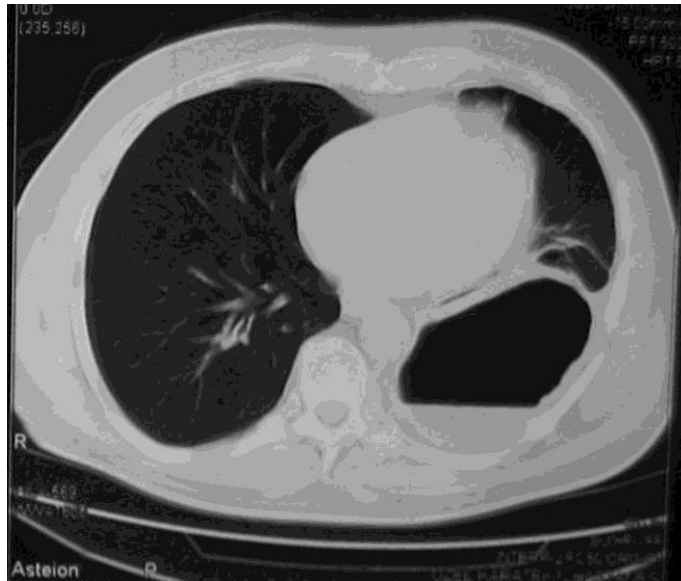
## Case

A 58 year-old male patient was referred to thoracic surgery clinic after detection of a cavitory lesion at left hemithorax during investigation for chest pain started after a coughing period 20 days ago. He had a history of free fall from a height, diagnosis of left multiple rib fractures and tube thoracostomy for pneumothorax 7 months ago. He had also a history of cranial surgery for subdural hematoma 5 months ago. His outpatient controls at 10th day; 1st, 4th and 6th months after trauma have been uneventful. Chest X-ray revealed previous multiple left rib fractures and air filled opacity at left hemithorax (Figure 1).

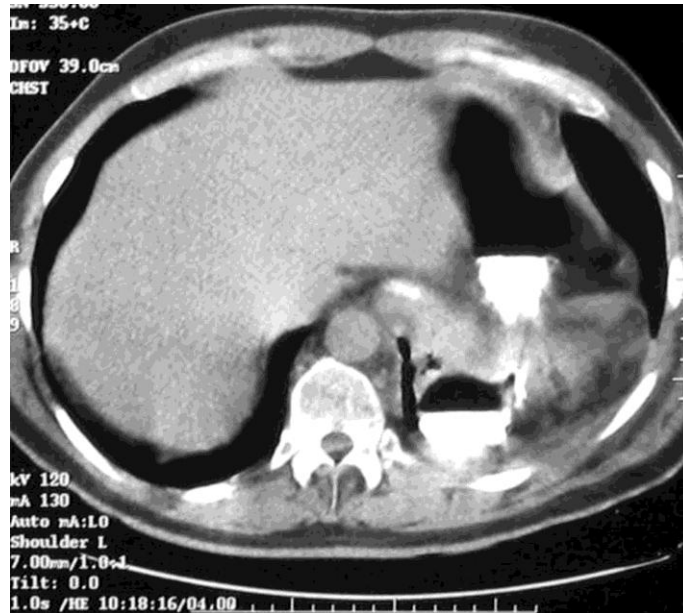

**Figure 1:** Chest X-ray reveals ruptured left hemidiaphragm and previous rib fractures.

Oral contrast-enhanced CT image revealed herniation of the fundus of the stomach (Figure 2A, and 2B).

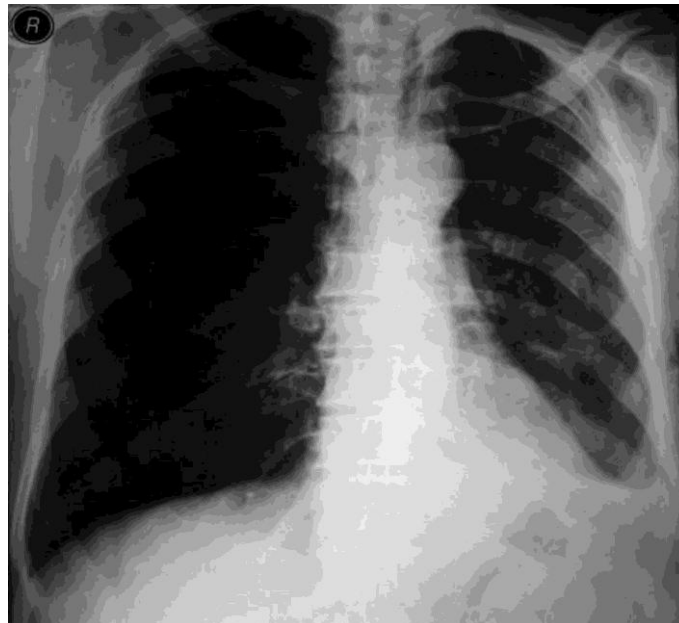


**Figure 2A:** Contrast-enhanced chest CT image shows herniation of the fundus of the stomach.



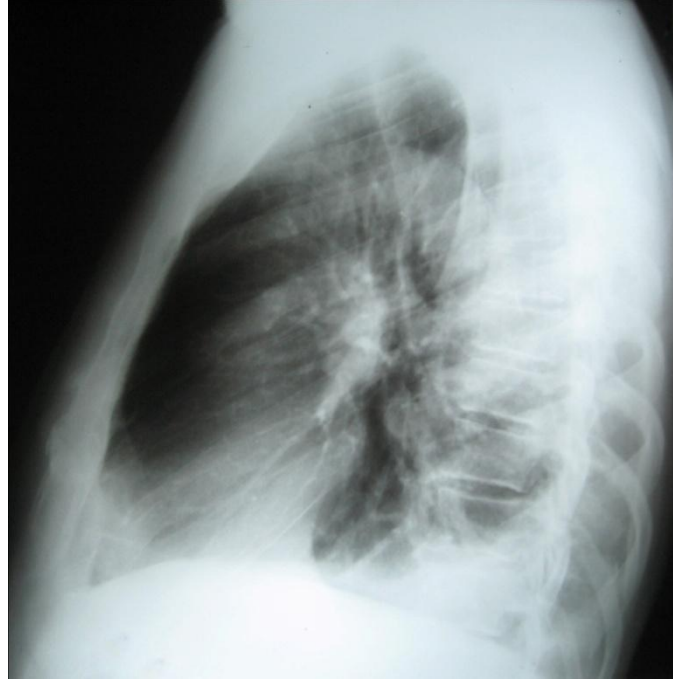
**Figure 2B** Oral contrast-enhanced Chest CT image reveals herniation of gastric fundus through the rupture.

Interestingly previous chest X-rays showed a blunting of the costophrenic angle without another sign of ruptured diaphragm (Figure 3A, 3B, and 3C).

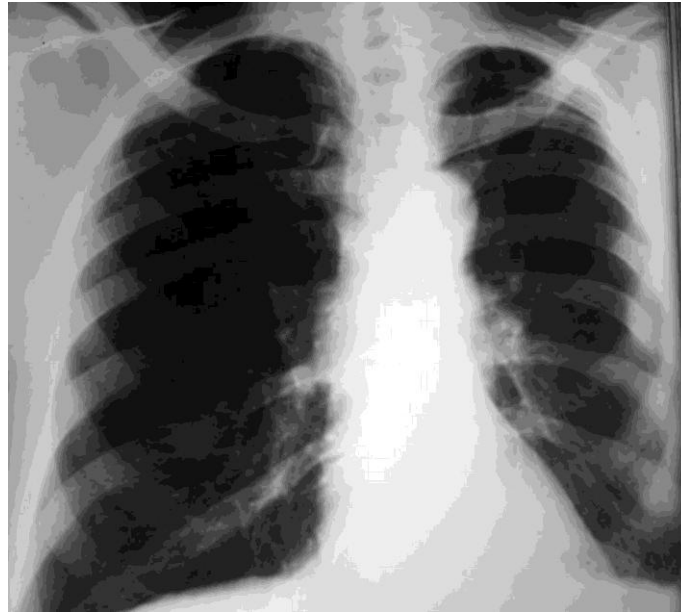


**Figure 3A:** Chest X-ray taken 10 days after trauma shows multiple rib fractures and blunting left costophrenic angle

After the diagnosis of traumatic diaphragmatic rupture with herniation of stomach into thoracic cavity, left thoracotomy was performed. The gastric fundus herniating through a 5 cm central tendon defect with thickened pleura over left lower lobe were detected during the exploration. The stomach was placed back in the abdomen, partial decortication to left lower lobe was performed, then the diaphragm was repaired with interrupted nonabsorbable sutures. Patient recovered uneventfully and was discharged home 5 days later.



**Figure 3B: Lateral Chest X-ray taken 4 months later after the trauma reveals no signs of diaphragmatic rupture**



**Figure 3C: Chest X-ray taken 6 months later the trauma.**

### **Discussion**

Missed diaphragmatic lesions result in herniation of abdominal contents into the thorax and may be revealed many years after the time of initial trauma [3-6]. Because of late presentation, trauma can be forgotten and diaphragmatic injury can be omitted. BDR most commonly occurs after blunt thoraco-abdominal trauma, such as a road traffic accident or a fall from a height. It is associated with high-energy acceleration-deceleration impact that results in a sudden increase in intra-abdominal pressure [1-5]. The raised intra-abdominal pressure during blunt injury may cause either a new defect on

the healthy diaphragm or on the weakened-impaired closed segment of the diaphragm. Repeated minor traumas, such as violent coughing, weight lifting, obesity may gradually cause enlargement of the newly formed defect on the weakened diaphragm [7]. In our case, we detected a violent coughing period which had started 20 days before chest pain. The left diaphragm is more frequently involved during blunt injuries that cause radial lacerations of the central tendinous region [1]. Because there is also a plugging effect of the viscera over the defect, migration of the abdominal organs within the chest may be delayed. The significant difference between the higher intra-abdominal and the lower intrathoracic pressures will result in herniation eventually [8]. The stomach, spleen, colon, small bowels and liver may herniate [1, 2, 6, 8].

Clinically, diaphragmatic rupture (DR) has 3 phases according to the interval between injury and diagnosis: initial or acute phase, interval phase and obstructive phase or late phase. In the acute phase which continues 2 weeks, clinical signs of DR may be obscured by the associated injuries [2, 9-11]. Classically reported symptoms, such as abdominal pain, shortness of breath, and chest pain can often be overlooked [4]. The herniated contents can result in complications, such as respiratory or cardiac insufficiency due to compression, collapse of the lung and possible shift of the mediastinum. Beside this, symptoms of intestinal obstruction are more common when hernia occurs for a considerable period of time [1, 2, 5]. The interval phase may be relatively asymptomatic and DR may be discovered only by incidental radiography. The patients may have symptoms such as indistinct chest and abdominal pain or discomfort. These symptoms may suggest angina, peptic ulcer or subacute intestinal obstruction [2, 5, 10, 11]. Our patient was also investigated by a cardiologist and gastroenterologist before his referral to thoracic surgery department. Finally, at the phase of obstruction and strangulation most patients have acute symptoms secondary to acute respiratory or bowel obstruction problems. Also patients mostly have an acute abdomen secondary to incarceration and strangulation [1-11]. Severe chest pain was leading symptom in our patient.

The patient's examination and history was also important for the diagnosis. The history of stab wound in the lower chest or abdomen may suggest missed penetrating diaphragmatic rupture (PDR). PDR may result in a small defect or a defect large enough to allow herniation of viscera to thorax. Because of normal pressure gradient between the abdomen and the thorax, the viscera migrates within thoracic cavity [2, 8, 10, 11]. Penetrating diaphragmatic defects are smaller (<2-3 cm) than BDRs which frequently consist of approximately 10 cm tear along central tendon. PDR commonly involves left hemidiaphragm, as BDR. PDR has no specific signs and it is occasionally missed when there is no surgical exploration [2, 10, 11]. In both BDR and PDR, herniation may present acutely or at the time remote from the initial injury [2, 5, 10, 11]. While late hernias secondary to blunt trauma tend to contain multiple abdominal viscera, those secondary to penetrating trauma tend to contain only colon or a portion of stomach [2-11]. In our patient, there were no history or physical findings of penetrating trauma, also the diaphragmatic defect was 5 cm. Nevertheless, previous multiple rib fractures in his history made us to consider the possibility of missed penetrating injury due to rib fracture penetration during blunt trauma, although we could not find such report in literature. Later, the violent coughing might gradually cause enlargement of this defect.

The chest radiograph is the most valuable first-line diagnostic imaging technique in identifying BDR. Unfortunately only 28-70% of chest radiographs can be diagnostic for BDR [1, 4, 9]. Persistent blunting of the costophrenic angle after chest tube placement, elevation of the hemidiaphragm, absence of the sharp hemidiaphragm, or presence of the hemopneumothorax, intrathoracic herniation of the abdominal viscera are some of the abnormal signs for BDR [1, 9]. The placement of nasogastric tube or the use of oral contrast may be helpful for the diagnosis [1]. The CT scan of the chest is the second choice imaging tool and its sensitivity ranges between 61 to 90%. Difficulties in description of hemidiaphragm from soft tissue structures such as atelectatic lung, big slice

thickness, respiratory motions are limitations of CT [4, 7, 9]. Helical CT has a much higher sensitivity and specificity than chest radiographs. Magnetic resonance imaging allows a perfect imaging of the entire diaphragm and could differentiate the diaphragm and the adjacent structures in hemodynamically-stable patients [4, 9, 12]. Chest CT was diagnostic in our case.

A surgical approach to manage diaphragmatic rupture consists of laparotomy, thoracotomy or both and it is determined by the presence of associated injuries. A transthoracic approach is recommended in late presentation of diaphragmatic rupture because of the dense adhesions between the herniated viscera and the thoracic contents. Defect can be closed primarily or with a prosthetic mesh [1-8]. Our patient was managed with a thoracotomy and defects were closed primarily.

In conclusion, the diagnosis of late diaphragmatic rupture should always be remembered in any patient with a blunt thoracoabdominal trauma history. A high index of suspicion is mandatory for early detection and prompt management.

## References

1. Meyers BF, McCabe CJ. Traumatic diaphragmatic hernia. Occult marker of serious injury. *Ann Surg* 1993; 218: 783-90.
2. Hegarty MM, Bryer JV, Angorn IB, Baker LW. Delayed presentation of traumatic diaphragmatic hernia. *Ann Surg* 1978; 188: 229-33.
3. Shah R, Sabanathan S, Mearns AJ, Choudhury AK. Traumatic rupture of diaphragm. *Ann Thorac Surg* 1995; 60: 1444-9.
4. Athanassiadi K, Kalavrouziotis G, Athanassiou M, Vernikos P, Skekas G, Poultsidi A, Bellenis I. Blunt diaphragmatic rupture. *Eur J Cardiothorac Surg* 1999; 15:469-74.
5. Mihos P, Potaris K, Gakidis J, Paraskevopoulos J, Varvatsoulis P, Gougoutas B, Papadakis G, Lapidakis E. Traumatic rupture of the diaphragm: experience with 65 patients. *Injury* 2003; 34: 169-72.
6. Özdemir A, Özenç A. Delayed traumatic diaphragmatic hernias. *TJ Research Med Sd* 1988; 6: 329-34.
7. Matsevych OY. Blunt diaphragmatic rupture: four year's experience. *Hernia* 2008; 12: 73-8.
8. Reber PU, Schmied B, Seiler CA, Baer HU, Patel AG, Büchler MW. Missed diaphragmatic injuries and their long-term sequelae. *J Trauma* 1998; 44:183-8.
9. Rodriguez-Morales G, Rodriguez A, Shatney CH. Acute rupture of the diaphragm in blunt trauma: analysis of 60 patients. *J Trauma*. 1986; 26: 438-44.
10. Guitron J, Howington J, LoCicero III J. Diaphragmatic Injuries. In Shields TW, Locicero III J, Reed CE, Feins RH ed., *General Thoracic Surgery*. 7 th ed Philadelphia: Lippincott Williams and Wilkins; 2009; 937-44
11. Clarke DL, Greatorex B, Oosthuizen GV, Muckart DJ. The spectrum of diaphragmatic injury in a busy metropolitan surgical service. *Injury, Int J. Care Injured* 2009; 40: 932-937
12. Shanmuganathan K, Killeen K, Mirvis SE, White CS. Imaging of diaphragmatic injuries. *J Thorac Imaging* 2000; 15: 104-11.