

*Case report-Olgu sunumu*

## **Acute colonic pseudo-obstruction as a rare complication in an elderly celiac patient: A case report**

*Yaşlı çöliak hastada nadir görülen bir komplikasyon olan akut kolonik psödoobstrüksiyon: Olgu sunumu*

**Fatih Albayrak, Hakan Dursun, Yavuz Albayrak, Serkan Cerrah**

Department of Internal Medicine (F. Albayrak, MD, H. Dursun, MD, S. Cerrah, MD), Ataturk University, Faculty of Medicine, 25040 Erzurum, Department of General Surgery and Burn Unit (Y. Albayrak, MD) Erzurum Training and Research Hospital, 25040 Erzurum

### **Abstract**

Celiac disease is a common disorder not only in the young but also in the elderly. Different complications may be observed in elderly patients who have had celiac disease for a long time. We report a case of Ogilvie's syndrome (acute colonic pseudo-obstruction (ACPO)) seen as a complication of celiac disease in an elderly patient. A 69-year-old woman presented with a 1-week history of gradually increasing abdominal distension and obstipation. She had been diagnosed as celiac disease approximately 35 years ago, and had been on a gluten-free diet since then. Her serum calcium was 6.7 mg/dL. She was treated with hydration and calcium repletion. We think that her long duration of celiac disease which is approximately 35 years and the intermittent diet inconsistencies due to this long duration may have contributed to the development of ACPO. Therefore, in elderly patients who have had celiac disease for a long time, ACPO may develop with an electrolyte imbalance. An early diagnosis of ACPO will minimize the rates of mortality and morbidity.

**Key words:** Celiac disease, acute colonic pseudo-obstruction, electrolyte imbalance

### **Özet**

Çölyak hastalığı, gençlerde ve yaşlılar da sık olarak izlenir. Çölyak hastalığı uzun süredir devam eden yaşlılarda farklı komplikasyonlar gözlenebilir. Bu makalede çölyak hastalığı tanısı olan yaşlı bir hastada nadir görülen bir komplikasyon olarak gelişen Ogilvie sendromu (Akut kolonik psödoobstrüksiyon (AKPO)) olgusunu sunuyoruz. Altmışdokuz yaşında bayan hasta bir haftadır ilerleyici şekilde artan karın distansiyonu ve obstipasyon şikayeti ile başvurdu. Hastaya 35 yıl önce çölyak hastalığı tanısı konmuş ve bu zaman boyunca glutensiz diyet kullanmaktaydı. Serum kalsiyumu 6,7 mg/dL bulundu. Hastaya hidrasyon ve kalsiyum replasmanı yapıldı. Hastanın 35 yıldır çöliak hastası olmasından dolayı zaman zaman glutensiz diyete uyumsuz davranmış olabileceği ve AKPO gelişmesine sebep olduğunu düşünmekteyiz. Bu nedenle uzun zamandır çöliak hastalığı bulunan yaşlı hastalarda, elektrolit imbalansı nedeniyle AKPO gelişebilir. AKPO'nun erken teşhis edilmesi de morbidite ve mortalite oranını azaltır.

**Anahtar sözcükler:** Çölyak hastalığı, Akut kolonik psödoobstrüksiyon, elektrolit dengesizliği

**Geliş tarihi/Received:** April 13 2010; **Kabul tarihi/Accepted:** April 28 2010

### **Corresponding author:**

Dr. Fatih Albayrak Ataturk University, Faculty of Medicine, Department of Internal Medicine, TR-25040 Erzurum, E-mail: fatihalbayrakerz@gmail.com

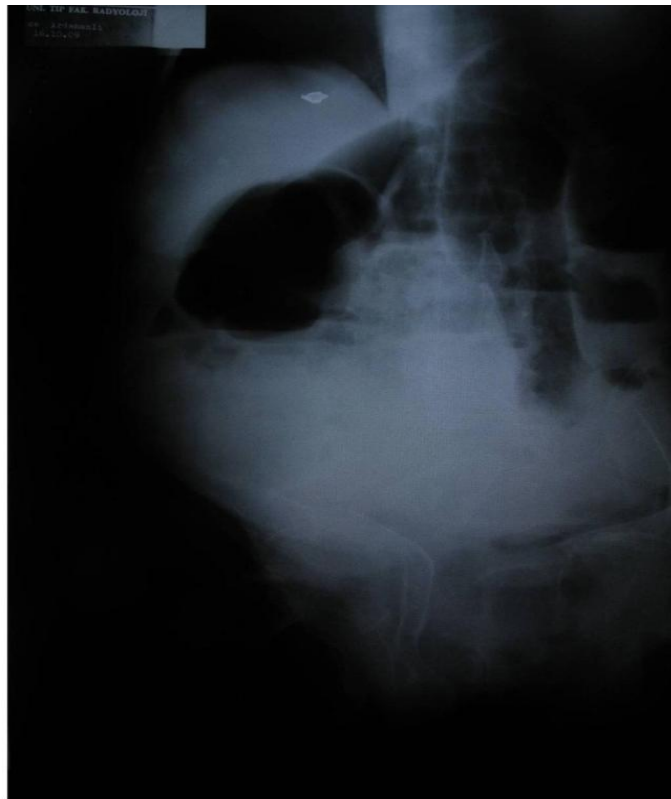
### **Introduction**

Celiac disease (CD) is a common disorder not only in the young but also in the elderly. A greater awareness of the incidence and clinical presentation of CD in the elderly is essential in order to prevent long delays in its diagnosis [1, 2]. However, even when a diagnosis is made at an early age, different complications may be observed in elderly patients who have had celiac disease for a

long time. Nevertheless, it is uncommon to see it as a cause of obstipation and colonic pseudo-obstruction. Acute colonic pseudo-obstruction (ACPO) is defined as acute colonic dilatation in the absence of obvious colonic disease or mechanical obstruction [3]. This severe form of adynamic ileus, also known as Ogilvie's syndrome, develops in hospitalized patients and is associated with a wide variety of medical and surgical conditions [4]. We report a case of Ogilvie's syndrome seen as a complication of celiac disease in an elderly patient.

### Case Report

A 69-year-old woman presented with a 1-week history of gradually increasing abdominal distension and obstipation. There was no prior history of abdominal surgery, diverticular disease, or malignancy. The patient was not taking any narcotics or opioids. She had been diagnosed with celiac disease approximately 35 years ago, and had been on a gluten-free diet since then. On physical examination, she was mildly dehydrated but lying comfortably in bed. Her temperature was 36.8 °C, pulse rate was regular at 86/min, and blood pressure was 90/60 mmHg. Examination of the chest and cardiovascular system was normal. The abdomen was markedly distended, but soft. There was mild tenderness in the lower abdomen, without rebound. Bowel sounds were reduced and tympanic. A small amount of brown stool was noted on digital rectal examination, which was negative for occult blood. On admission, her hemoglobin level was 10.8 g/dl and white blood cell count was  $5 \times 10^9$ /dl, with 70% neutrophils. Serum glucose, sodium, potassium, protein, and albumin levels were normal. Blood urea nitrogen was 50.3 mg/dl (normal range, 0-54 mg/dl) and serum creatinine was 1.4 mg/dl (normal range, 0-1.5 mg/dl). Serum calcium and phosphate were 6.7 mg/dl and 4.3 mg/dl, respectively (normal range, 8.5-10.8 mg/dl and 2.3-4.5 mg/dl). Erythrocyte sedimentation time was 33/hour, prothrombin time was 22.8 seconds, activity was 36%, activated prothrombin time was 30.9 seconds, anti-endomysium Ab was negative, anti-tissue transglutaminase was 263.5 IU/ml (0-15), anti-gliadine IgG was 65.5 U/ml (0-15), anti-gliadine IgA was over 300 U/ml (0-15), parathormon was 89 pg/ml (10-65 pg/ml) and hydroxy vitamin D was 14.7 ng/ml (11-43). Tumor markers, viral hepatitis markers, serum cortisole, vitamin B12, folic acid, ferritin and thyroid functions were normal. Plain radiographs of the abdomen revealed widespread colonic dilatation with no free air (Figure 1).



**Figure 1. Pre-treatment supine abdominal radiograph. Supine radiograph of the abdomen of the patient with intestinal pseudo-obstruction shows a dilated bowel. It resolved after medical treatment**

She was diagnosed with ACPO (Ogilvie's syndrome) based on these clinical and radiological findings. She was treated with hydration and calcium repletion; her electrolytes were closely monitored. Electrolyte controls carried out after calcium infusion showed potassium levels to be 3.3 mmol/L. Potassium and calcium replacements were monitored and continued. Approximately 12 hours later, abdominal distention was relieved, with no abdominal tenderness. For the next 2 days, the patient's condition improved significantly. Serial abdominal x-rays showed a gradual decrease in the size of the dilated colon. Her abdominal distension improved, tenderness to palpation resolved, and she was discharged on day 4.

### Discussion

Celiac disease (CD) may linger for many years before its diagnosis, causing subtle or troubling symptoms, and may present for the first time with serious fatal complications. Although the treatment of CD is straightforward, the elderly present specific challenges in the management of their CD, particularly in view of making radical changes to diet as well as coping with the complications of longstanding malabsorption. A comprehensive multidisciplinary approach to the management of CD should result in reduced morbidity in these patients. A management approach tailored to the particular challenges presented by elderly celiac patients is crucial to their success [1, 2, 5]. Although constipation is known in elderly celiac patients, as far as we know, no co morbidity of acute colonic pseudo-obstruction (ACPO) and celiac disease has yet been reported in the English literature.

ACPO is a syndrome of massive dilation of the colon without mechanical obstruction that results from an imbalance in the autonomic control of the colon. Evaluation involves exclusion of mechanical obstruction and assessment for signs of ischemia or perforation. ACPO typically develops in elderly hospitalized patients who have an associated medical or surgical condition, such as trauma, recent surgery, neurologic disorders, or a series of infections [6-8]. Left untreated, ACPO can lead to ischemia and perforation in anywhere from 3% to 15% of cases. The 36-50% mortality that accompanies perforation highlights the need for prompt diagnosis and appropriate treatment [9]. Treatment options for ACPO include appropriate supportive measures, pharmacologic therapy, colonoscopic decompression, and surgery. In most patients with ACPO, conservative management will result in the resolution of colonic distention within three days. Decisions about the need for medical therapy, colonoscopy, or surgery should be individualized and should be based on the patient's clinical status [9, 10].

In this case we are presenting, although we have determined hypocalcaemia, and after the application of hydration, mild hypopotassemia, we do not think that the sole reason for the development of ACPO was this electrolyte imbalance. We think that the patient, having suffered from celiac for approximately 35 years, and due to intermittent diet inconsistencies, had a condition whereby serum calcium level was low and this may have contributed to the development of ACPO. Therefore, in elderly patients who have had celiac disease for a long time, ACPO may develop with an electrolyte imbalance. An early diagnosis of ACPO will minimize the rates of mortality and morbidity.

### References

1. Rashtak S, Murray JA. Celiac disease in the elderly. *Gastroenterol Clin North Am* 2009; 38: 433-46.
2. Beaumont DM, Mian MS. Coeliac disease in old age: 'a catch in the rye'. *Age Ageing* 1998; 27: 535-8.
3. Fazel A, Verne GN. New solutions to an old problem: acute colonic pseudo-obstruction. *J Clin Gastroenterol* 2005; 39: 17-20.
4. Ponc RJ, Saunders MD, Kimmey MB. Neostigmine for the treatment of acute colonic pseudo-obstruction. *N Engl J Med* 1999; 341: 137-41.
5. Carnevale V, Filabozzi P, Cela P, Scillitani A. Tiredness: a feature of coeliac disease. *Age Ageing* 2000; 29: 462-3.

6. Ozkurt H, Yilmaz F, Bas N, Coskun H, Basak M. Acute colonic pseudo-obstruction (Ogilvie's syndrome): radiologic diagnosis and medical treatment with neostigmine. Report of 4 cases. *Am J Emerg Med* 2009; 27: 757.e1-4.
7. Hyatt R. Colonic pseudo-obstruction: an important complication in hospitalized elderly patients. *Age Ageing* 1987; 16: 145-52.
8. Vanek VW, Al-Salti M. Acute pseudo-obstruction of the colon (Ogilvie's syndrome): an analysis of 400 cases. *Dis Colon Rectum* 1986; 29: 203-10.
9. McNamara R, Mihalakis MJ. Acute colonic pseudo-obstruction: rapid correction with neostigmine in the emergency department. *J Emerg Med* 2008; 35: 167-70.
10. Saunders MD. Acute colonic pseudo-obstruction. *Best Pract Res Clin Gastroenterol* 2007; 21: 671-87.