

## **Papillary carcinoma in a thyroglossal duct cyst: Two case reports and review of literature**

### ***Tiroglossal kanal kistinde papiller karsinoma: İki olgu sunumu ve literatürün gözden geçirilmesi***

**Emine Elif Altuntaş\*, Şahande Elagöz, Ersin Tuncer, Ayhan Koyuncu, Suphi Müderris**

Departments of Otorhinolaryngology (Asist. Prof. E. E. Altuntaş, MD, Prof. S. Müderris, MD) and Pathology (Prof. Ş. Elagöz, MD) and General Surgery (Prof. A. Koyuncu, MD), Cumhuriyet University School of Medicine, TR-58140 Sivas

#### **Abstract**

Thyroglossal duct cysts are the most common form of congenital malformation in the neck. They develop from the epithelial remnants of the thyroglossal tract and 70% is diagnosed in childhood; 7% is diagnosed in adulthood. Carcinoma arising in these remnants constitutes a very uncommon histopathological entity. The diagnosis of malignancy is made incidentally on cytopathologic studies of the excised surgical specimen. Only 1% of thyroid carcinoma arises from the thyroglossal duct cysts and papillary carcinoma (80%) is the most common malignancy in this cyst. We describe here two cases of thyroglossal duct cysts. Surgical specimen histopathology study showed presence of papillary carcinoma in the first case. Thyroglossal duct cyst was preoperatively diagnosed via fine needle aspiration biopsy (FNAB) in the second case. We suggest that in adult cases of thyroglossal duct cysts, fine needle aspiration cytology should be used for preoperative diagnosis and frozen examination should be done intra operatively.

**Keywords:** Thyroglossal ductus cyst, papillary thyroid carcinoma, fine needle aspiration biopsy, diagnosis, treatment

#### **Özet**

Tiroglossal duktus kisti, boyun orta hattında en sık görülen konjenital boyun kitlesidir. Tiroglossal duktusun epitelyal kalıntılarından gelişir ve %70 çocuk yaş grubunda %7 ise erişkin yaşlarda tanı alır. Tiroglossal kanal kistinden karsinoma gelişimi oldukça nadirdir. Malignite eksizye edilen cerrahi spesimenin histolojik incelemesinde tesadüfen saptanır. Tiroglossal kanal kistinde karsinom gelişimi oldukça nadirdir ve olguların %1'inden azında gözlenir ve papiller karsinoma (%80) bu kistlerde en sık izlenen malignensidir. Bu çalışmada cerrahi spesimenin histopatolojik incelemesi ile postoperatif dönemde ve preoperatif dönemde ince iğne aspirasyon biopsisi ile tiroglossal kist de papiller tiroid karsinomu tanısı almış olan iki olgumuzu sunduk. Erişkin yaş grubunda tiroglossal kanal kisti tanısı almış olan olgularda preoperatif ince iğne biyopsisi ve intraoperatif frozen çalışılması gerektiği kanısındayız.

**Anahtar sözcükler:** Tiroglossal kanalkisti, papillar tiroid karsinoma, ince iğne aspirasyon biyopsisi, tanı, tedavi

**Geliş tarihi/Received:** August 08, 2011; **Kabul tarihi/Accepted:** January 19, 2012

#### **\*Corresponding author:**

Dr. Emin Elif Altuntaş, Kulak Burun Boğaz Anabilim Dalı, Cumhuriyet Üniversitesi Tıp Fakültesi, TR-58140 Sivas. E-mail: emineelifaltuntas1@gmail.com

#### **Introduction**

Thyroglossal duct cysts (TGDC) are the most common form of congenital cervical mass, which is growth from the remnant of thyroglossal duct and present characteristically as a

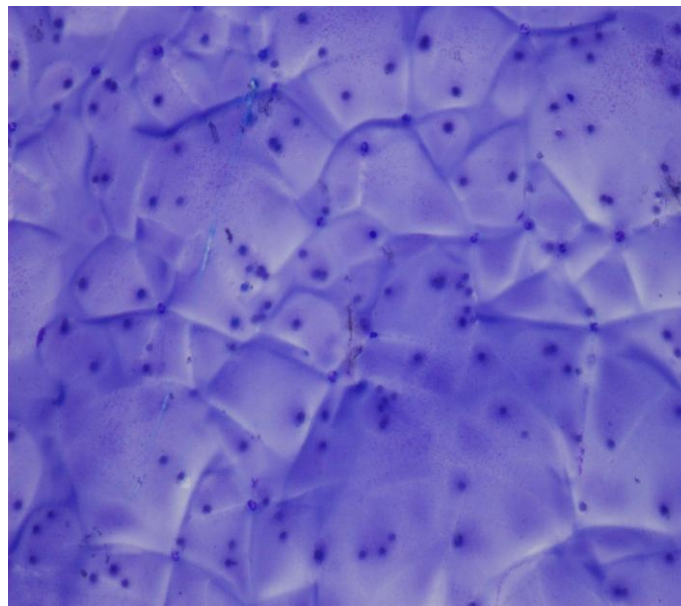
midline servical mass at the level of the thyroid membrane. A thyroglossal remnant can be a cyst, a tract or duct, a fistula, or an ectopic thyroid within a cyst or duct [1]. Carcinoma arising in the thyroglossal duct remnants constitutes a very uncommon histopathological entity [2-4]. A review of the literature showed that 250 cases of malignant thyroglossal cysts have been reported [5]. The incidence of papillary carcinoma arising in the TGDC is rare (<1%). Approximately 150 cases of papillary carcinoma arising in the thyroglossal duct cyst have previously been reported in the literature. There is very few case reports of these cases diagnosed on fine needle aspiration cytology (FNAC) [6-8]. TGDC carcinoma may be clinically indistinguishable from benign TGDC, and the diagnosis in most cases is incidental after surgical resection. The use of fine needle aspiration cytology under ultrasound guidance may enhance the preoperative diagnosis [9]. In this presentation we reported two adult cases of papillary carcinoma arising in a TGDC and discussed the diagnostic difficulties in patients with TGDC in the light of the literature.

### **Case report**

Fine needle aspiration biopsies (FNABs) were performed in two patients with TGDC in the Otorhinolaryngology department of Cumhuriyet University Teaching and Research Hospital.

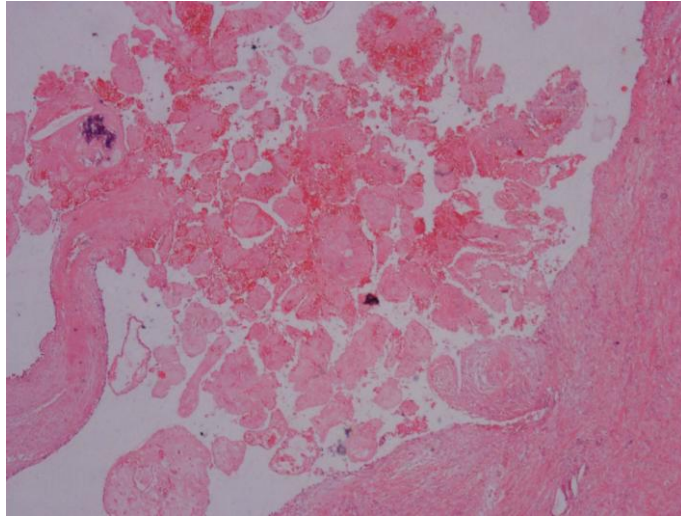
#### **Case report 1**

A 65-year-old white Asian female presented with 3-4 year history of midline progressive enlarging neck mass. She had two operations in her medical history. One of them was midline cystic neck mass excision 10 year ago and the other one was subtotal thyroidectomy 12 years ago. Thyroid hormone levels of the patient were normal. In physical examination 3x 3 cm diameter immobile necks mass was found and this moved upward with protrusion of the tongue. There was no palpable cervical lymphadenopathy. On the neck ultrasonography (USG) and scintiscan the cystic mass was 13x21x27 mm diameter and the thyroid gland was hypertrophic, irregularly margin and homogeneous echo structure. FNAB was done and showed an amorphous and hemoragic material and spares ciliated columnar cells and macrofages. Preoperatively, the lesion was histopathologically diagnosed as TGDC and the mass was resected by the Sistrunk procedure. Gross examination disclosed a 20x20x12 mm greyish-tan cyctic lesion. Microscopic examination of this spesmen showed thyroglossal duct cyst with a 1.5 cm papillary carcinoma and cyst wall invasion was absent (Figure 1a, b).



**Figure 1a. Case 1; FNAS. Mononuclear cells in the proteinase colloidal ground (MGG; x 20).**

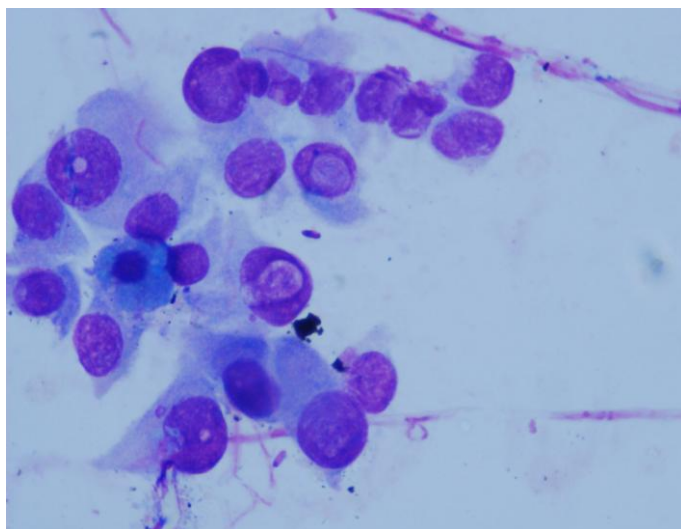
Treatment of patient was completed at a second operation with total thyroidectomy. Thyroidectomy specimen was showed had a multifocal papillary microcarcinoma. Postoperatively, the patient's thyroid sonography was completely normal and no further therapy was given. The patient has been following without any metastasis for 3 years.



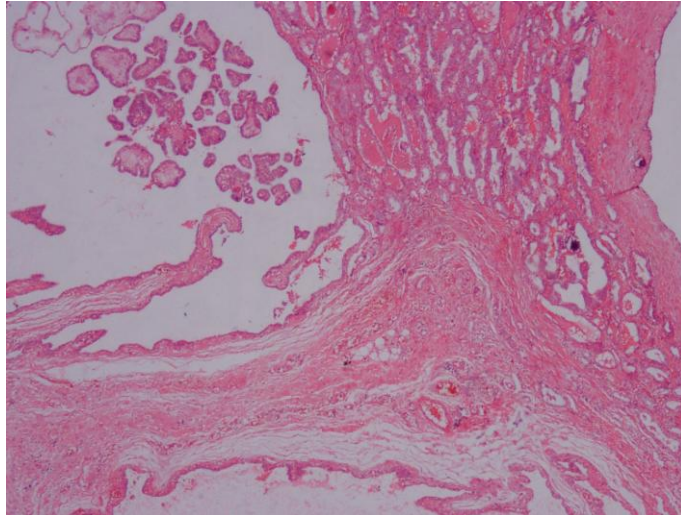
**Figure 1b. Case 1; papillary structure showed infarction and psammoma calcification (HE; x 20).**

#### **Case report 2**

A 41-year-old white Asian man presented with 2 weeks history of midline painless neck mass and this mass progressive enlarged. His past medically history has normal. Thyroid hormone levels of the patient were normal and no abnormalities were noted on palpation of the thyroid gland. Physical examination 1.5x1.5 cm diameter immobile midline neck mass was found. However, this mass moved upward with protrusion of the tongue. There was no palpable cervical lymphadenopathy. On the neck USG and scintiscan the cystic mass was 14x17 mm diameter which was located near the isthmus of thyroid gland. Location and function of the thyroid gland was found normal in the scintiscan. FNAB was done without USG guidance, aspirates showed dark fluid and was reported as malignancy. So the patient consulted with the general surgeon. Preoperatively, the lesion was diagnosed as thyroglossal carcinoma and the mass was resected by the Sistrunk procedure and total thyroidectomy. Gross examination disclosed 1.5x1x1 cm grayish-tan multi cystic lesion. Microscopic examination of this spesmen showed a thyroglossal duct cyst with a 1.5 cm papillary carcinoma with no cyst wall invasion (Figure 2 a, b).



**Figure 2a. Case 2; follicular epithelial cells include nuclear pseudoinclusion (MGG; x 40).**



**Figure 2b. Case 2; multicysts included papillary structure and thyroid follicles seen in the cyst wall are lined by atypical follicular cells (HE; x 20).**

## Discussion

TGDC during the embryogenesis, the descent the thyroid gland remains connected to the base of tongue by means of thyroglossal duct if this duct subsequently fails to atrophy it may give rise to a thyroglossal duct cyst. TGDCs are the most common non-odontogenic cyst in the neck and are presents in approximately 7% of the general population. Such cysts are the most common congenital anomalies of the neck and represent more than 75% of childhood midline neck masses. Thyroglossal duct cyst is diagnosed mostly in childhood but it may also be found in adults and in the elderly [10]. Thyroglossal cysts are commonly complicated by infection and sinus formation, the development of malignancy is rare (0.7-1%) and is encountered mostly in adults and which only few cases have been reported. Carcinomas arising in the thyroglossal duct cyst are generally of two types: thyrogenic carcinoma and squamous carcinoma. The thyrogenic carcinoma most often arises from thyroembryonic rests in the duct or cyst and the squamous carcinoma arises from the metaplastic columnar epithelium [11]. Papillary carcinoma (80%) is the most common malignancy seen in TGDC, accounting for approximately mixed papillary-follicular carcinoma 8% and; squamous cell carcinoma 6% of cases [12]. Incidence of papillary carcinoma arising in the thyroglossal duct cyst is <1% and it is usually seen in younger women, with a sex ratio of 1.5:1 [8, 11]. Malignant TGDC present in the same manner, in most cases a diagnosis of malignancy is frequently made postoperatively by histopathological examination of the resected tissue [13]. The carcinoma should be suspected in any remnant that is hard, fixed or irregular wall of the cyst or is associated lymphadenopathy. These TGDC carcinomas are generally not suspected preoperatively and are clinically indistinguishable from benign TGDC. A preoperative diagnosis of malignancy is rare and aspiration cytology proved unhelpful in this case but some authors recommend the USG guided FNAB in all TGDC before operations. Routine FNAB of all TGDC may not be cost-effective because of the rare instances of cancer in these patients and its relatively low accuracy, but it can be undergone routinely by adults 4. FNAC yielded correct results in only 50-66% of cases [6, 8, 14]. The false-negative result on FNAC was due to cystic fluid that was aspirated, leading to hypocellularity from dilution due to cystic contents 6. Location of the target lesion, careful searching for malignant cells and repeat FNAC of any residual mass after aspiration of the fluid in the cyst would yield better results, especially if done under USG guidance [6, 15]. When FNAB suggests throglossal duct carcinoma and magnetic resonance imaging is performed to evaluate the neck for local invasions, cervical metastasis and the presence of lesions with in the thyroid gland itself. In a review of Yang

et al.[6] found just 17 cases of preoperative FNAB of TGDC with papillary carcinoma. The true-positive rate was 53% and the false-negative rate was 47%. Miccoli et al. [16] have reported a 100% sensitivity and specificity in their series of nine patients undergoing FNAB. Agarwal et al [8] have reported a case in view of the rarity of pre-operative FNAC diagnosis of this entity and to highlight the diagnostic pitfalls and importance of FNAC to plan a proper surgical management. In our cases the success rate was one of two cases, however, we consider that FNAB is simply, cheap and reliable procedure if it is performed under USG guidance by a clinician or a cytopathologist. Origin of the TGDC papillary carcinoma doesn't know nowadays. They may be metastases of a thyroid tumor, or they may be the primer tumor of the TGDC. This distinction may have implications treatment of the disease. In managing patients with carcinomas of TGDC before a surgical procedure, it is important to identify whether the normally functioning thyroid tissue is in its usual location or not [17]. Some authors believe the papillary carcinoma of TGDC is the metastasis from the thyroid gland carcinoma who recommends total thyroidectomy as treatment. Others believe that papillary carcinoma is the primer tumors of the TGDC so that total thyroidectomy might not be necessary as a routine procedure only the Sistrunk procedure enough for the treatment [10]. Patel et al. [12] showed that the addition of total thyroidectomy to the Sistrunk procedure had no significant impact on outcome. Sistrunk operations cure rate of TGDC cases is 95% in the literature if there is no clinical or sonographic suspicion of thyroid lesion or cervical adenopathy. Total thyroidectomy of TGDC carcinomas enables a good flow-up. It increases the sensitivity of radioiodine scans, makes it possible to use radioactive iodine treatment and postoperative hormone suppression. In addition thyroglobuline levels may then be used as a sensitive marker of tumor status [10, 18, 19]. Malignancy within a thyroglossal duct cyst is very rare but should be included in the differential diagnosis of a neck mass. TGDC papillary carcinoma is rarely diagnosed preoperatively with the FNAB because of its relatively low accuracy. In our opinion diagnosis of papillary carcinoma arising in a TGDC is frequently made postoperatively by histopathological examination of the resected tissue, routine FNAB of all TGDC may not be cost-effective. For this reason only the adult TGDC cases FNAC must be done preoperative diagnosis and if surgeon suspected malignancy frozen examination should be done intra operatively.

## References

1. Peretz A, Leiberman E, Kapelushnik J, Hershkovitz E: Thyroglossal duct carcinoma in children: Case presentation and review of the literature. *Thyroid* 2004; 14: 777-85.
2. Vincent S, Synhorst II J: Adenocarcinoma arising in a thyroglossal duct cyst. *J. Oral Maxillofac Surg* 1989; 47: 633-5.
3. Aydin O: Boyun kitleleri. *Kulak Burun Bogaz Hastalıkları ve Baş-Boyun cerrahisi*. 1 baskı. Editör: Koc C, Ankara: Güneş Kitabevi; 2004: 887-99.
4. Plaza CP, Lopez ME, Carrasco CE, Meseguer LM, Perucho Ade L: Management of well differentiated thyroglossal remnant thyroid carcinoma: time to close the debate? Report of five new cases and proposal of a definitive algorithm for treatment. *Ann Surg Oncol* 2006; 13: 745-52.
5. . Geok Chin T, Mohd Sidik Sh, Manickam S, Seng Phang K, Clarence-Ko CH, Jeevanan J: Papillary carcinoma of the thyroglossal duct cyst in a 15-year-old girl. *Int J Otorhinolaryngology* 2007; 2: 732-5.
6. Yang YJ, Hagher S, Wanamaker JR, Powers CN. Diagnosis of papillary carcinoma in a thyroglossal duct cyst by fine-needle aspiration biopsy. *Arch Pathol Lab Med* 2000; 124: 139-42.
7. Tehrani AN, Karimi YAR, Kazemi M. Primary papillary carcinoma in thyroglossal duct cyst. *Acta Medica Iranica* 2007; 45: 236-8.
8. Agarwal K, Puri V, Singh S. Critical appraisal of FNAC in the diagnosis of primary papillary carcinoma arising in thyroglossal cyst: A case report with review of the literature on FNAC and its diagnostic pitfalls. *J Cytol* 2010; 27: 22-

- 5.
9. Park MH, Yoon JH, Jegal YJ, Lee JS. Papillary thyroglossal duct cyst carcinoma with synchronous occult papillary thyroid microcarcinoma. *Yonsei Med J* 2010; 51: 609-11.
10. Ishay A, ElmalahI, Luboshitzky R: Papillary carcinoma in a thyroglossal duct cyst. *IMAJ* 2008; 10: 312-3.
11. Srinivasan R, Ranjini K, Vadhiraja BM. Primary papillary carcinoma of the thyroglossal duct cyst - a case report. *Indian J Pathol Microbiol* 2005; 48: 228-30.
12. Patel SG, Escrig M, Shaha AR, Singh B, Shah JP: Management of well-differentiated thyroid carcinoma presenting within a thyroglossal duct cyst. *J Surg Oncol* 2002; 79: 134-9.
13. Vijay R, Rajan KK, Feroze M: Inapparent twin malignancy in thyroglossal cyst: Case Report. *World J Surg Oncol* 2003; 1: 15.
14. Bardales RH, Suhrland MJ, Korourian S, Schaefer RF, Hanna EY, Stanley MW. Cytologic findings in thyroglossal duct carcinoma. *Am J Clin Pathol* 1996; 106: 615-9.
15. Cherian MP, Nair B, Thomas S, Somanathan T, Sebastian P. Synchronous papillary carcinoma in thyroglossal duct cyst and thyroid gland: case report and review of literature. *Head Neck* 2009; 31: 1387-91.
16. Miccoli P, Pacini F, Basolo S, Iaconi P, Puccini M, Pinchera A. Thyroid carcinoma in a thyroglossal duct cyst: tumor resection alone or a total thyroidectomy? *Ann Chir* 1998; 52: 452-4.
17. Kazemi M, Assadi m, Kazemi AA, Ghazvini LA: Primary papillary carcinoma of thyroglossal duct cyst. *Hell J Nucl Med* 2006; 9: 39-40.
18. Basu S, Shet T, Borges A M: Letter to Editor: Outcome of primary papillary carcinoma of thyroglossal duct cyst with local infiltration to soft tissues and uninvolved thyroid. *Indian Journal of Cancer* 2009; 46: 169-70.
19. Motamed, Mehdi; McGlashan, Julian A: Thyroglossal duct carcinoma. *Current Opinion in Otolaryngology & Head and Neck Surgery* 2004; 2: 106-9.